



# Case of the Day

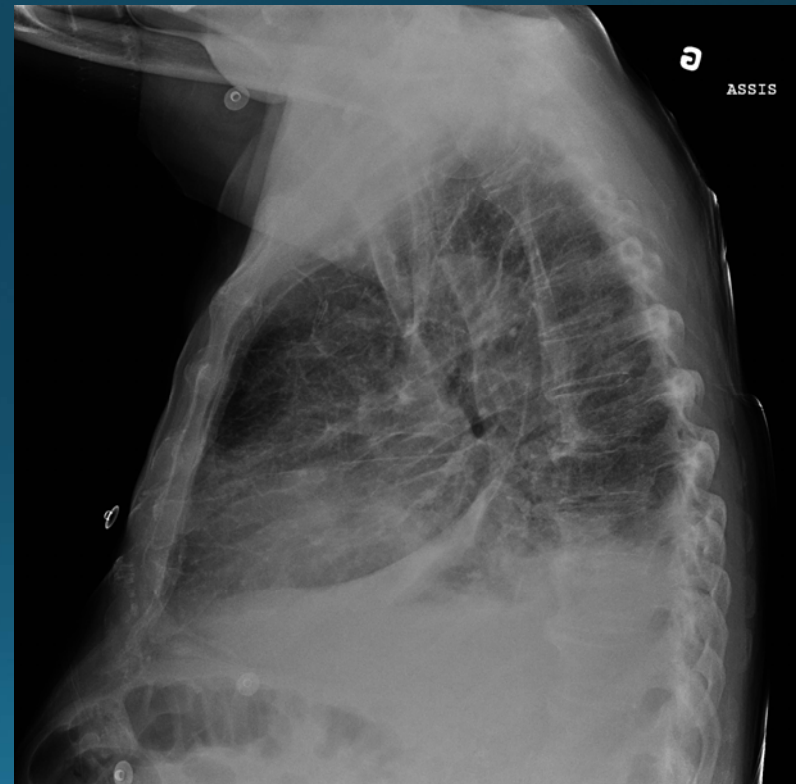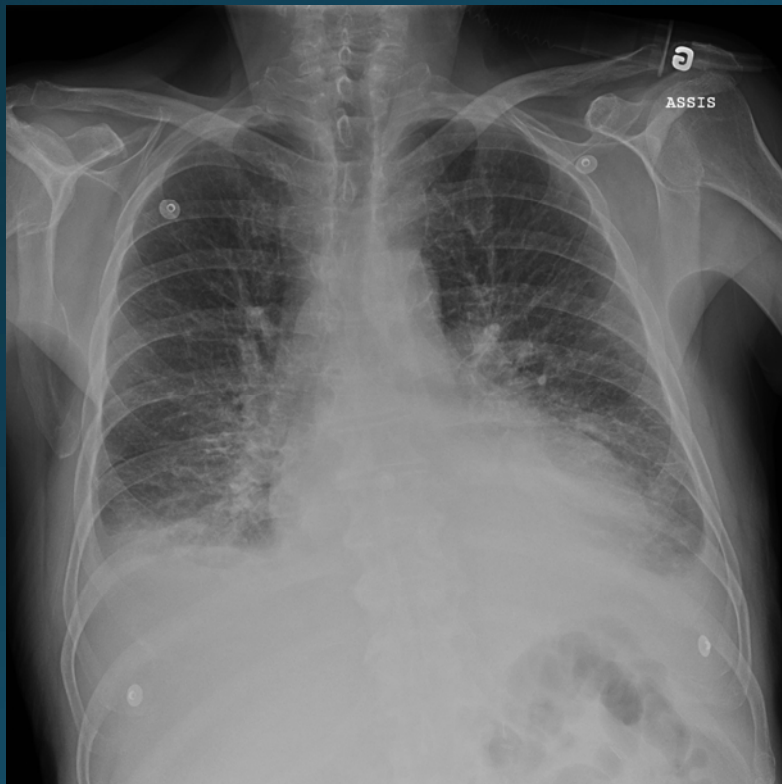
## November 2014

Case courtesy of Drs. Y. Kaitoukov, A. Husain and V. Oliva  
Université de Montréal

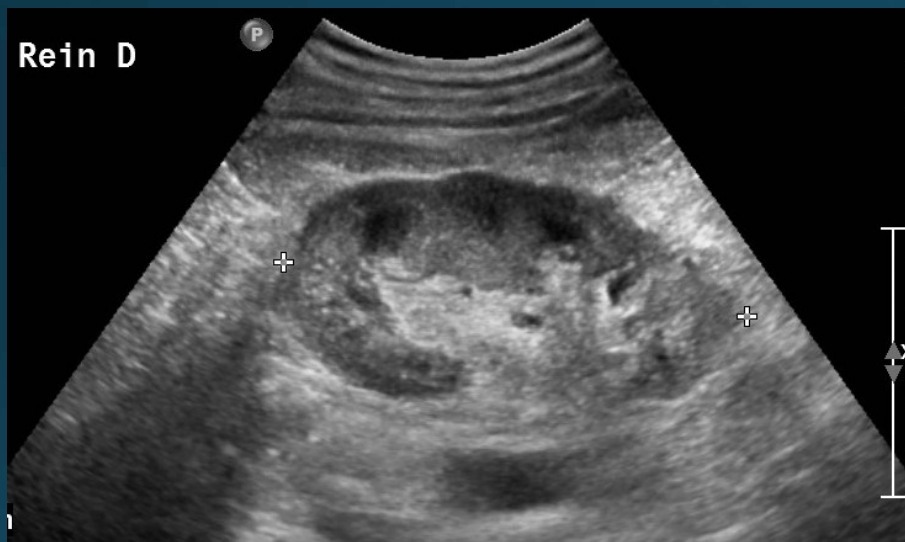# Clinical History

- 74 year old male
- Left nephrectomy for RCC
- History of right renal artery angioplasty +/- stenting
- Referred from a secondary center for recurring episodes of flush pulmonary edema and therapy-resistant hypertension.

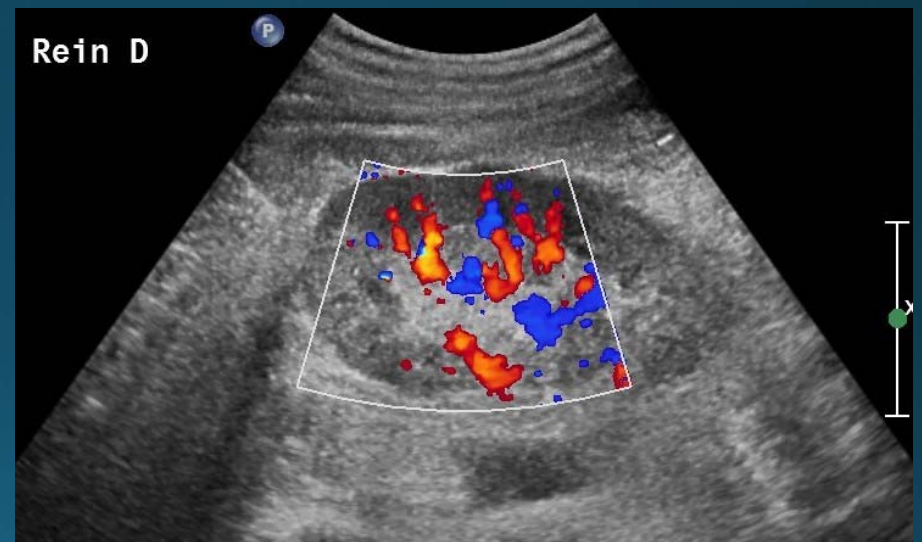
# Admission: pulmonary edema



# Diagnostic work-up: ultrasound

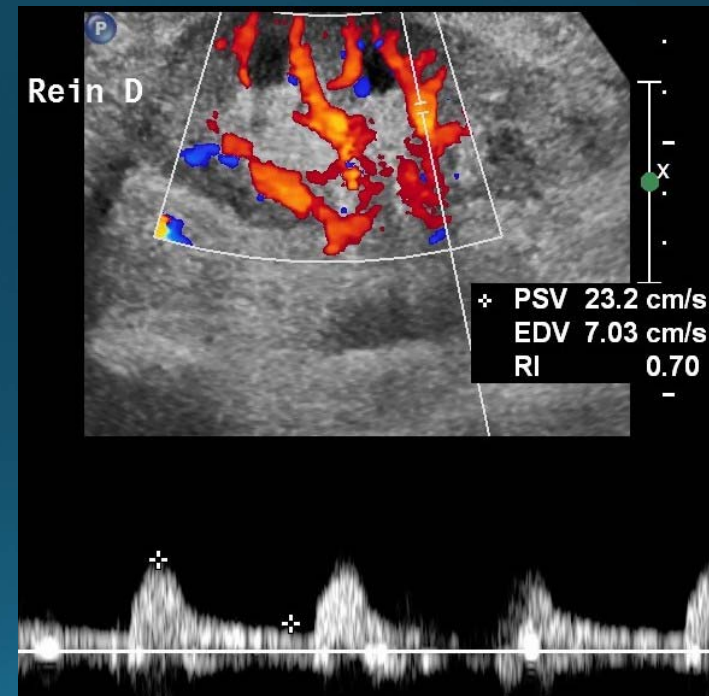
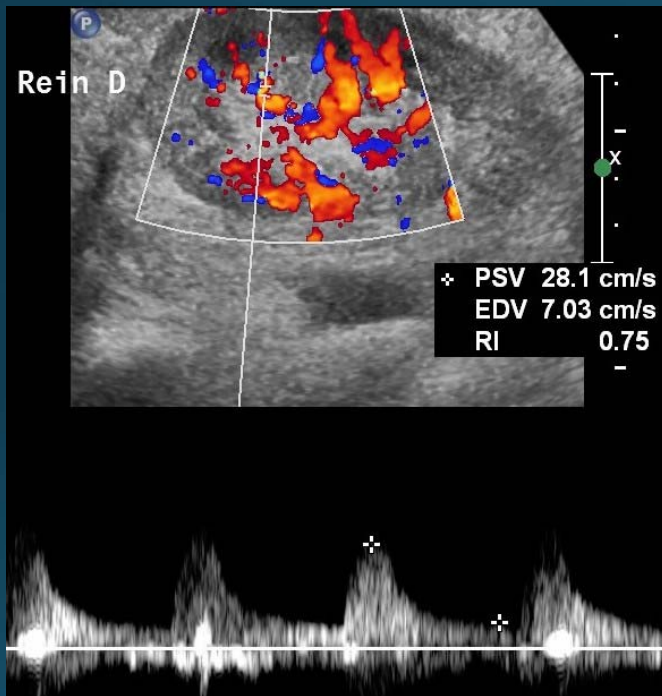


+ Dist 9.51 cm



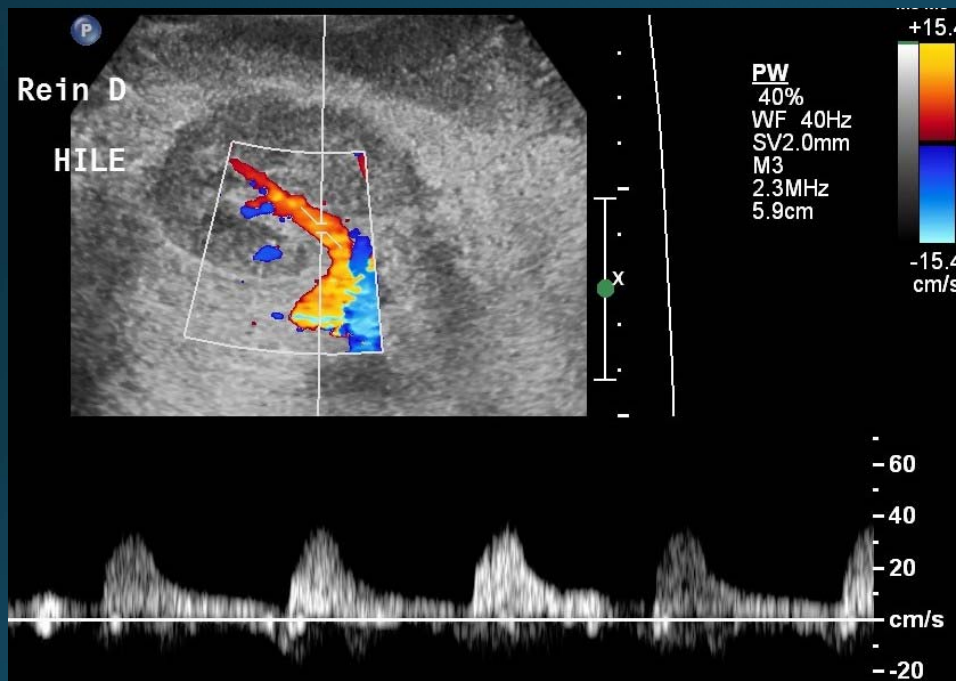
Normal right kidney on ultrasound

# Renal Doppler Ultrasound

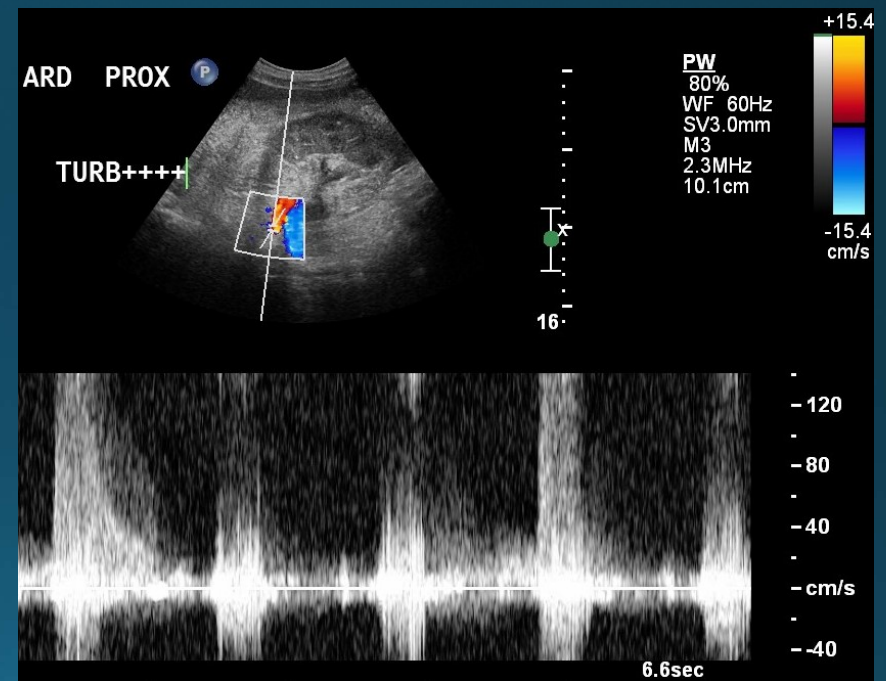


Resistive indices in the upper-normal range

# Right renal artery Doppler Ultrasound

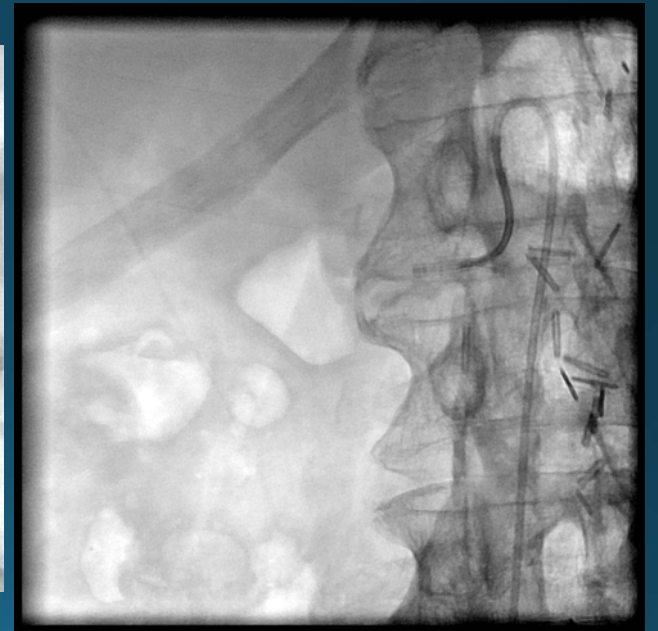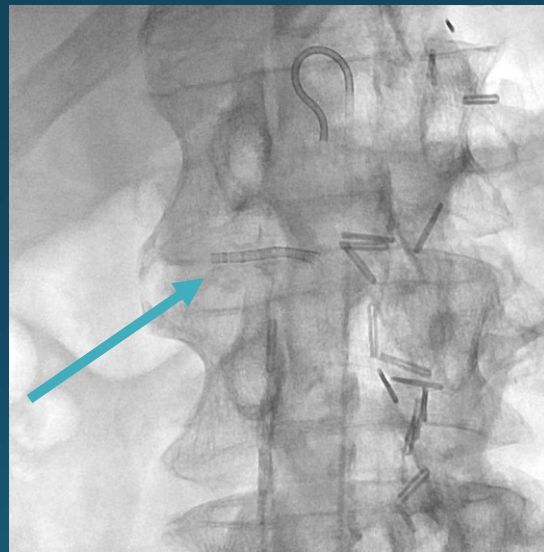
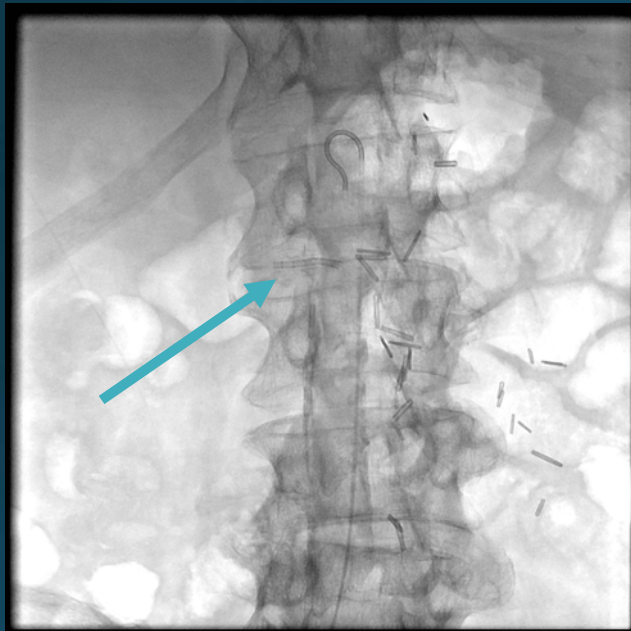


Diminished systolic rise at the renal hilum



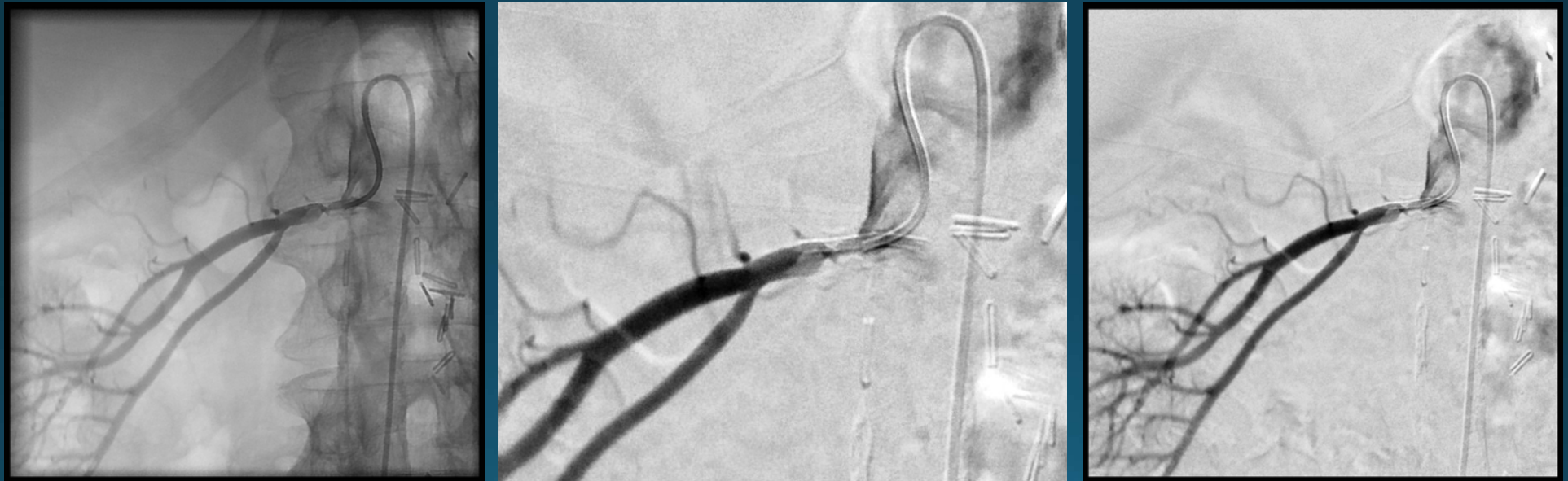Accelerated and turbulent flow in the middle of renal artery

# Fluoroscopy



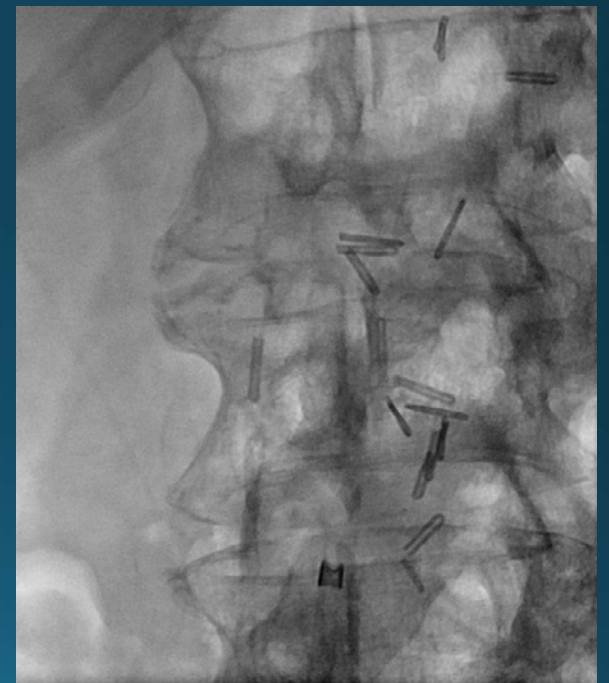
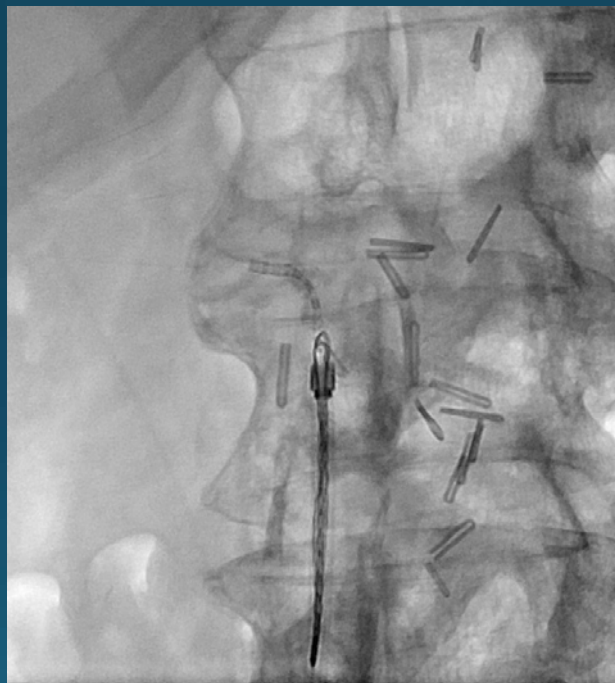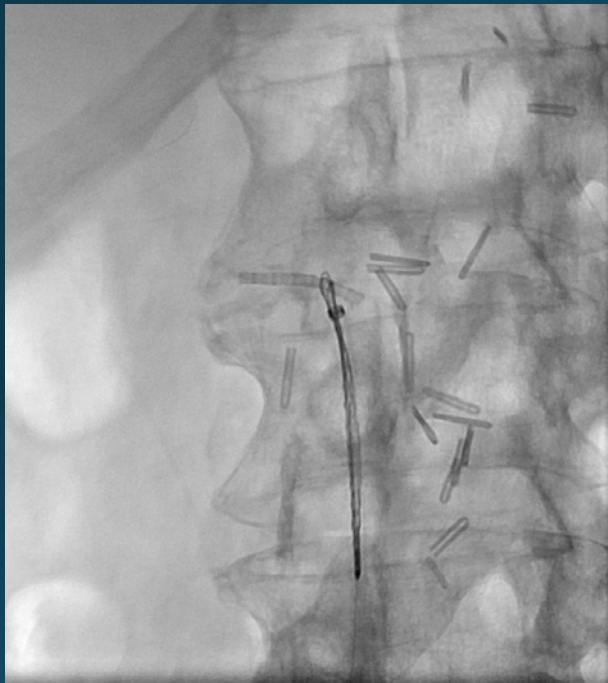
Collapsed stent in the right renal artery (arrow)

# Digital Subtraction Angiography



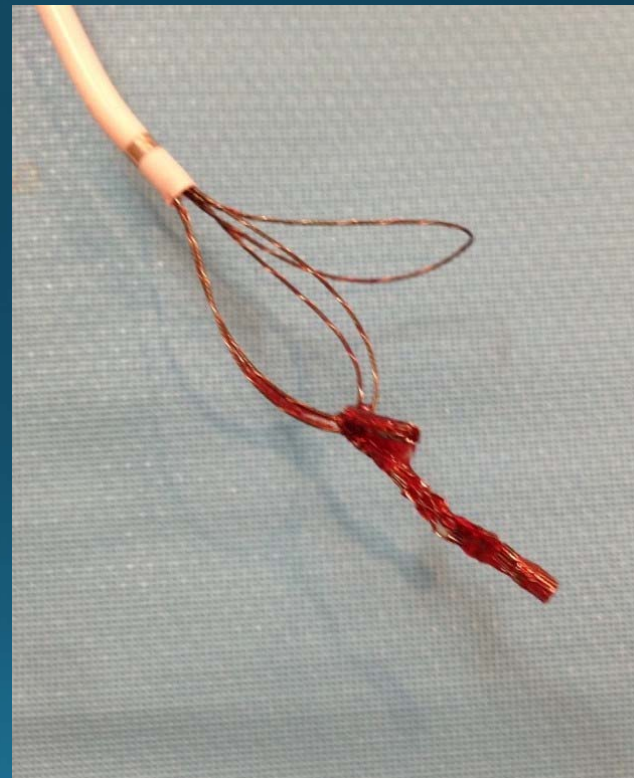
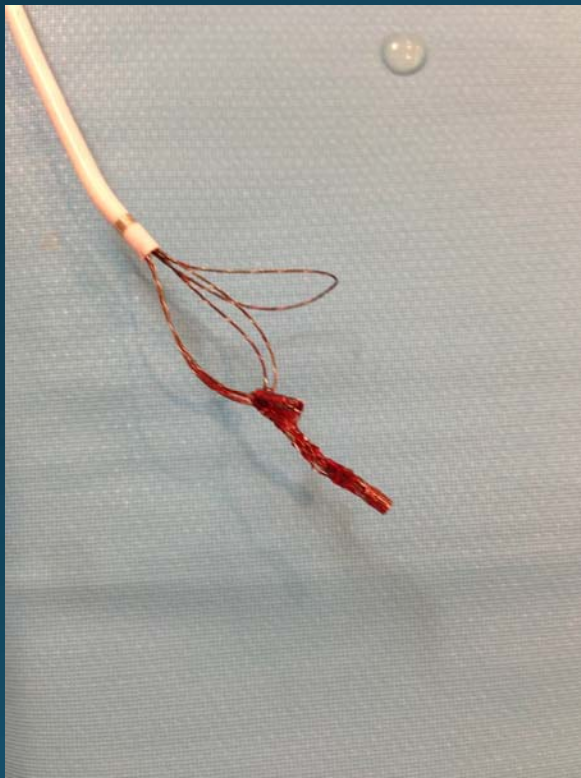Stenosis in the proximal portion of the right renal artery, partly occluded by a collapsed stent.  
Stent protrusion into the aortic lumen.

# Snaring: NSnare

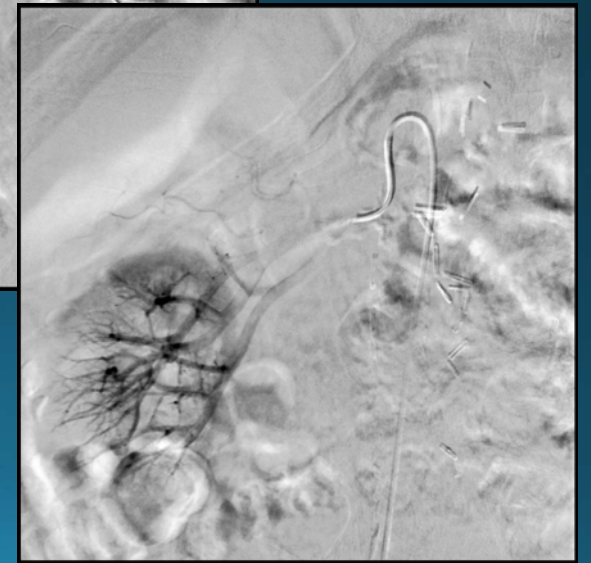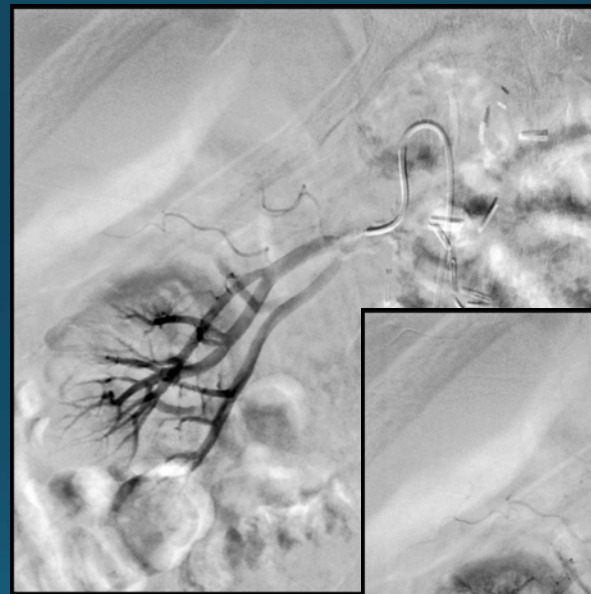
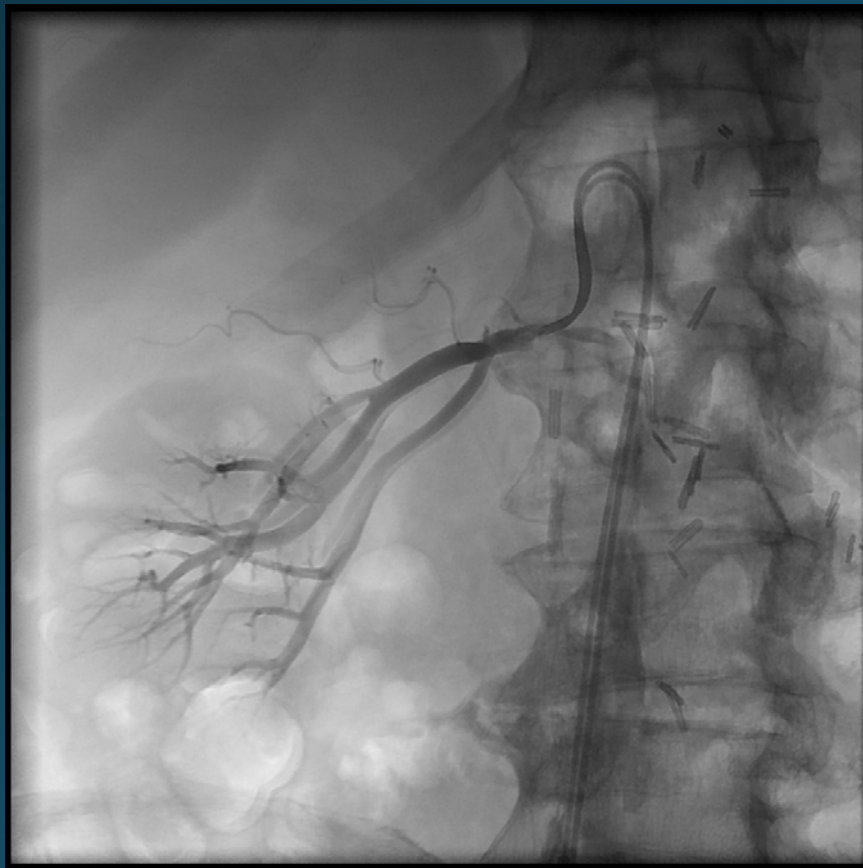


Snaring the proximal free edge of the stent protruding into the aorta. Removing the stent by gentle traction.

# Extracted bare metal stent

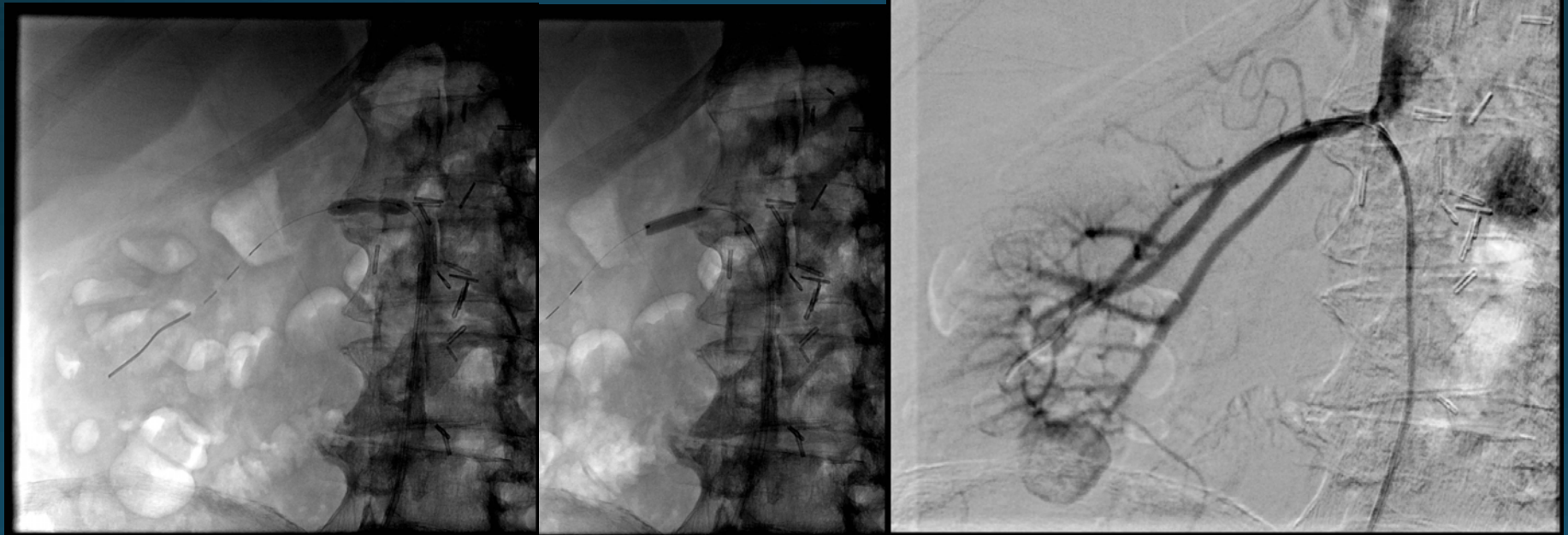


# Residual renal artery stenosis

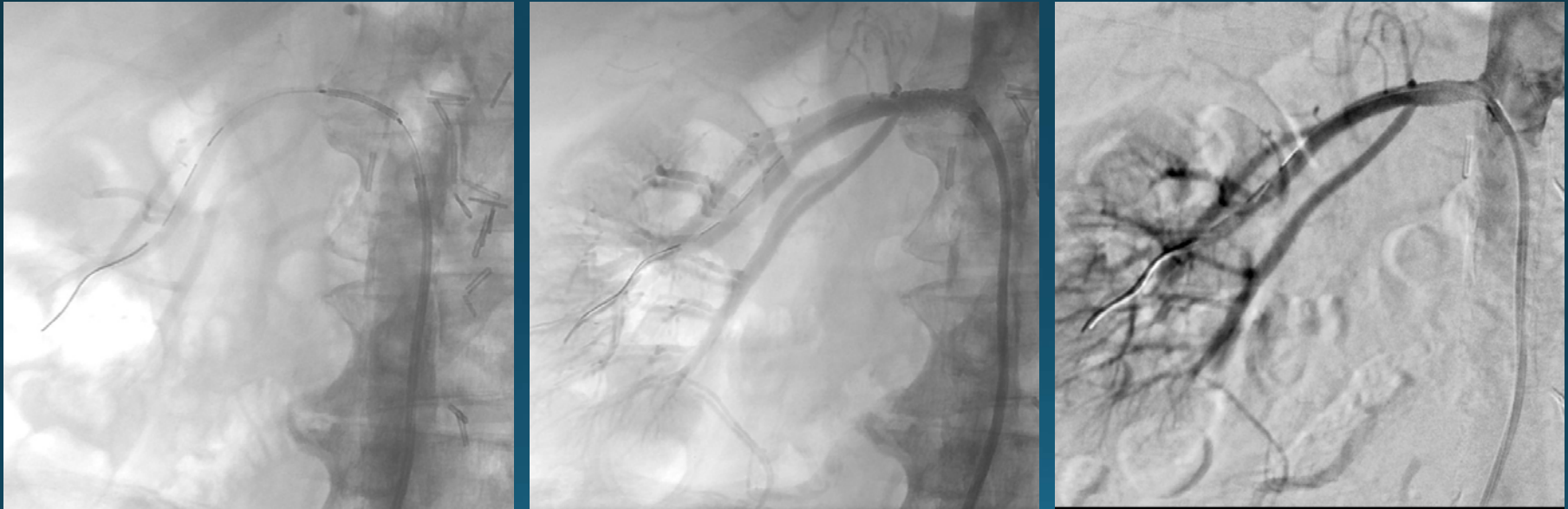

# Renal artery angioplasty

Thruway 0.014 inch microcatheter  
Balloon 5mm diameter

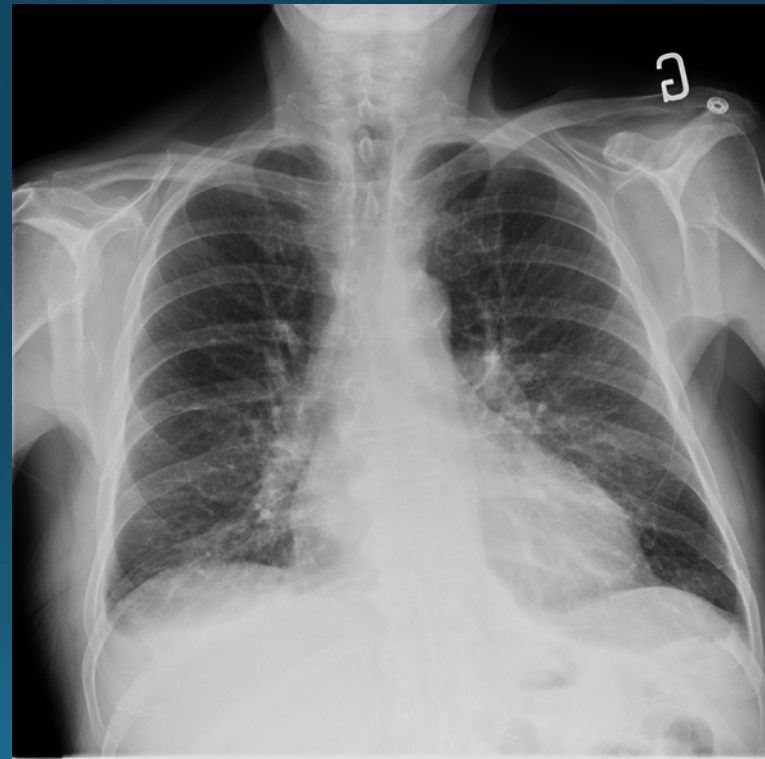
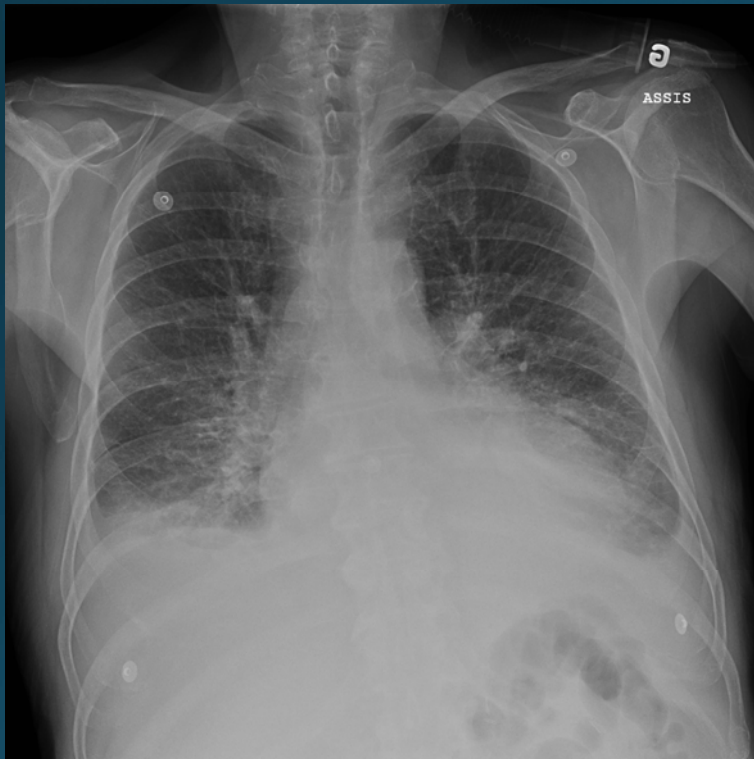


# Renal artery stenting

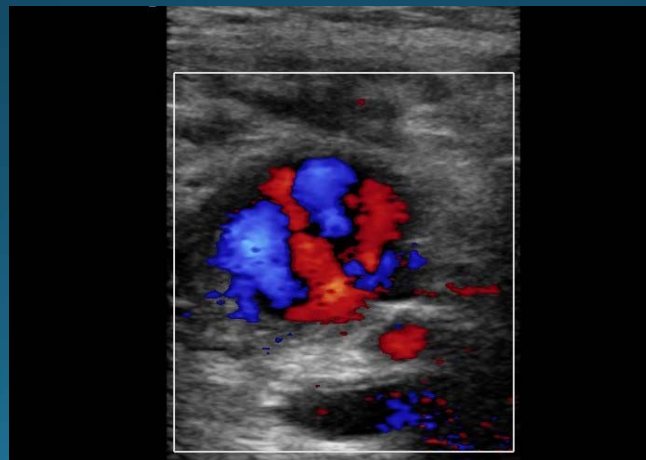
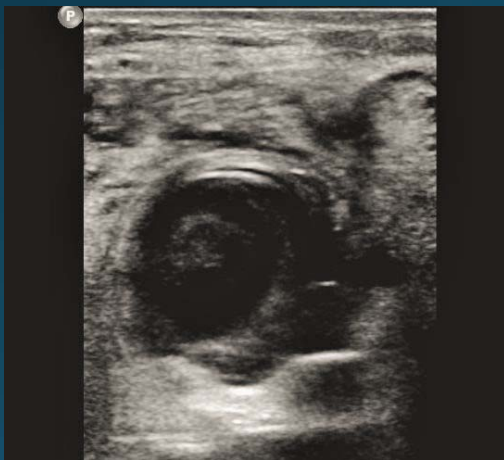
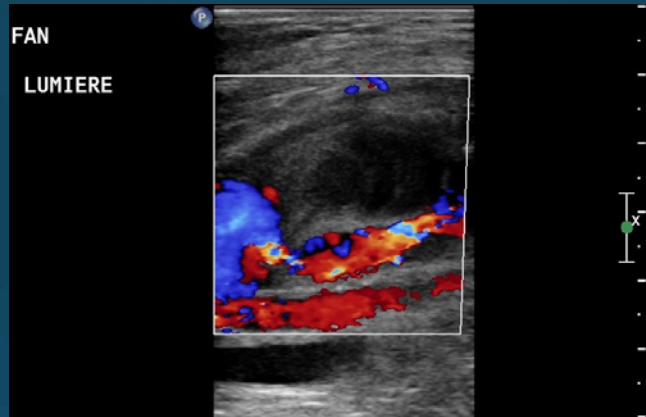
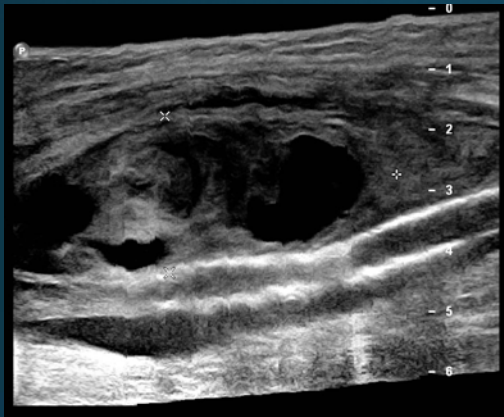

Express SD 6mm x 18mm Monorail Premounted Stent System (Boston Scientific).

# Regression of pulmonary edema



# Follow-up : CFA pseudoaneurysm



6.6cm x 2.6 cm

# Direct thrombin injection

3000 U Recothromb

