

CIRA Case of the Day

September 2015

Case Courtesy of Dr. Muhammad Bayat
University of Ottawa

Clinical History

Patient MG is a 76 year old male patient

Presented in August of 2014 with

- Progressive tiredness and lethargy
- New onset of abdominal pain (particularly worse after eating)
- Recent history of acute weight loss of 10 kg

Past Medical History

- Long standing hypertension, Cardiomyopathy and CCF
- Stage 3 CKD that acutely worsened in November 2010 but is now stable

Medications

- Ramipril, Metoprolol, ASA, Tylenol

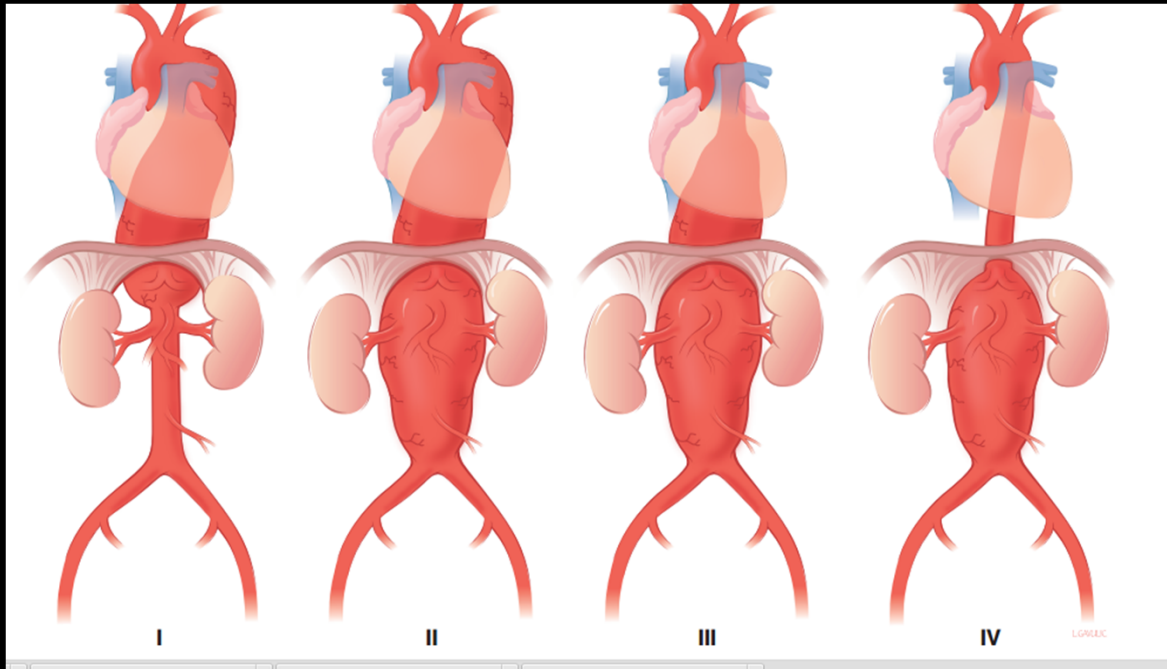
Allergies

- Nil

Clinical History

Past Surgical/Endovascular History

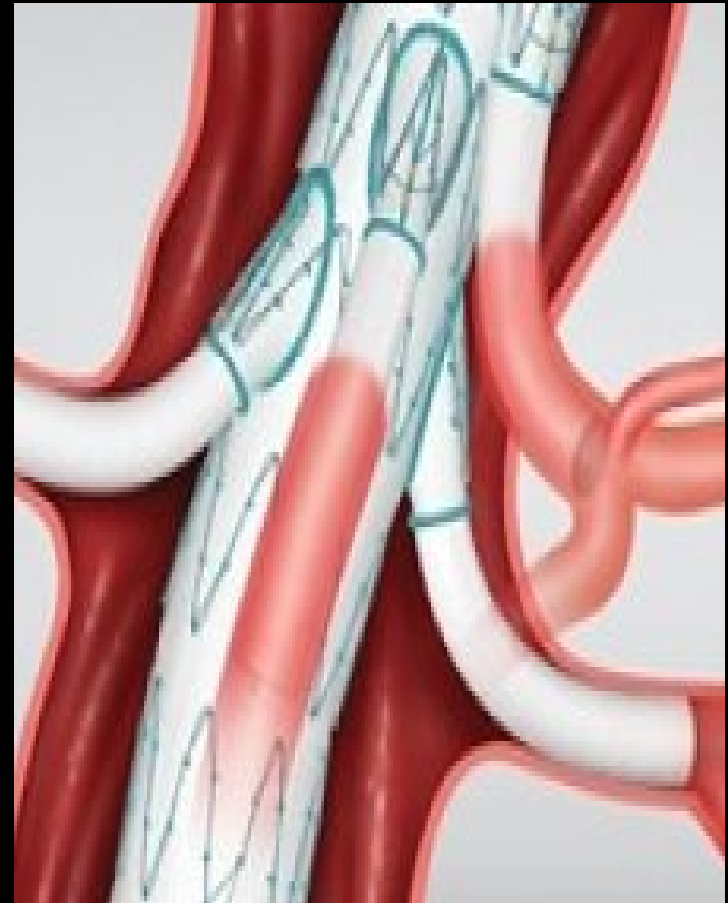- 2005 - Open AAA repair for infrarenal aneurysm
- 2009 - Developed thoracoabdominal aortic aneurysm (TAAA) – Crawford type IV



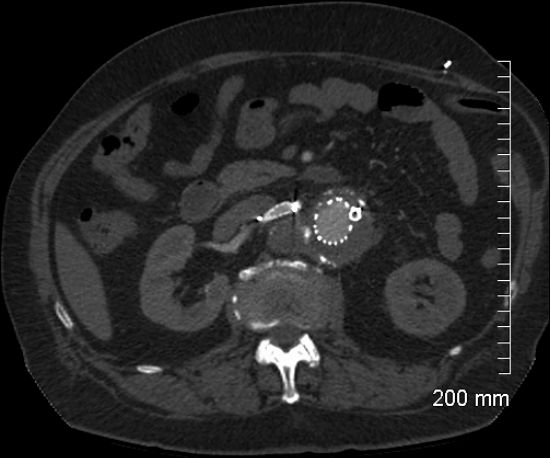
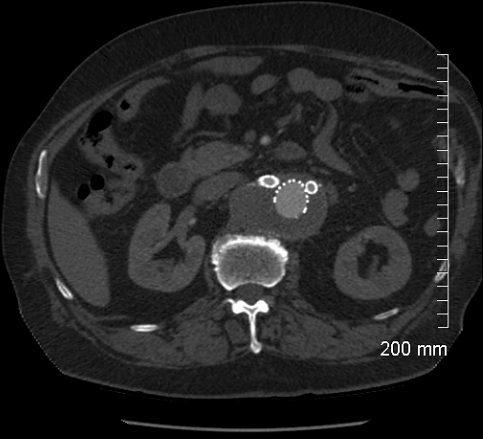
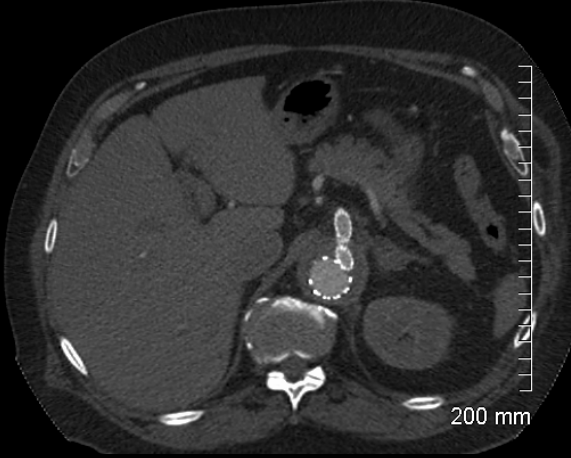
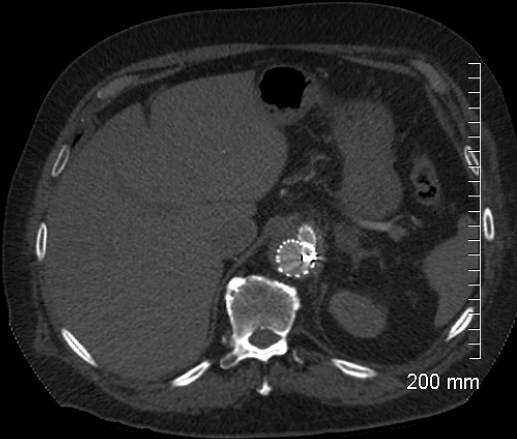
Clinical History

Past Surgical History Continued :

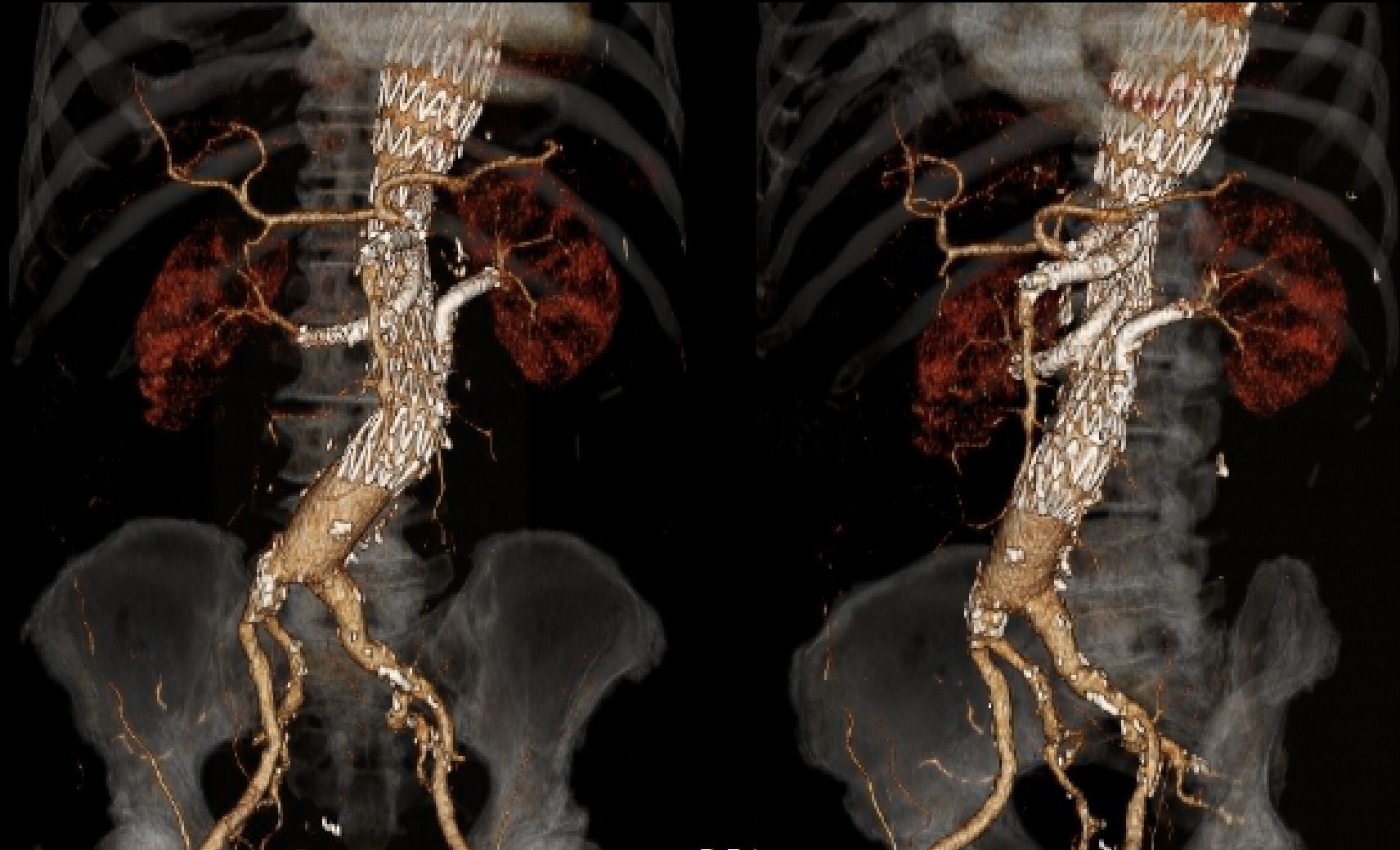
- Endovascular treatment of TAAA
 - Cuffed branched endograft with side cuffs
 - Self-expandable covered stents placed into the proximal visceral vessels
- Surveillance CT scans (6 month intervals) between 2009 – 2012 showed no change
- Patient lost to follow-up between 2012 and 2014



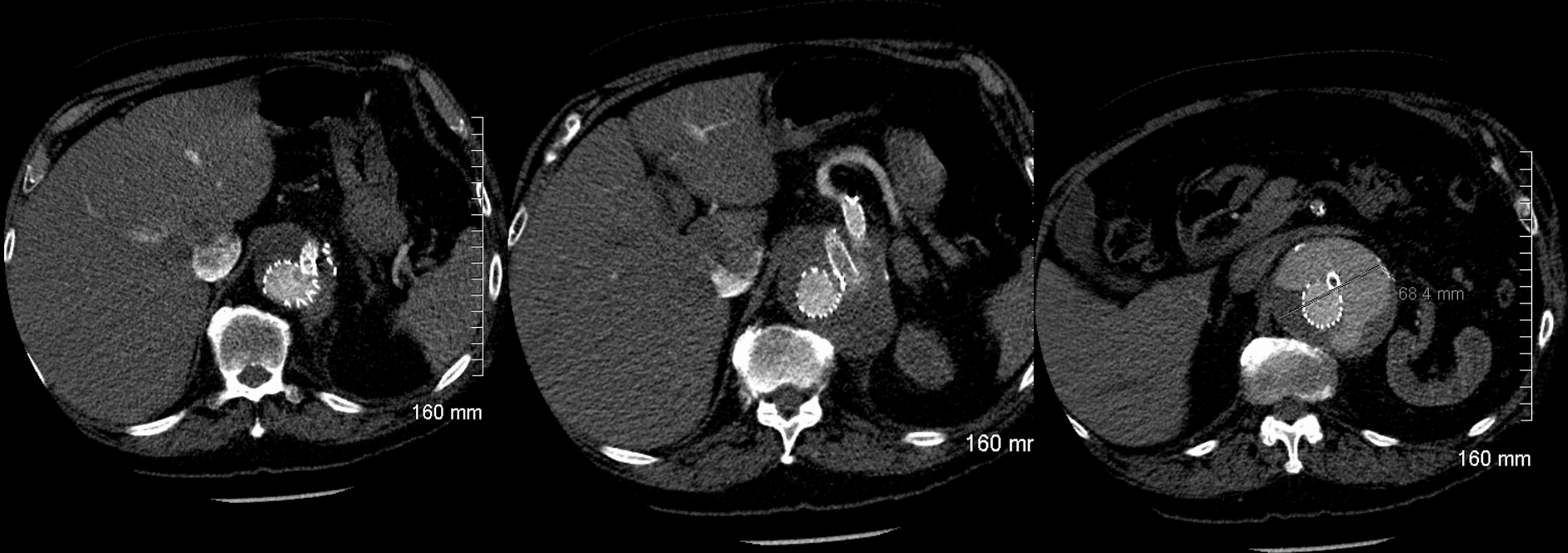
CT scan post-repair (2009)



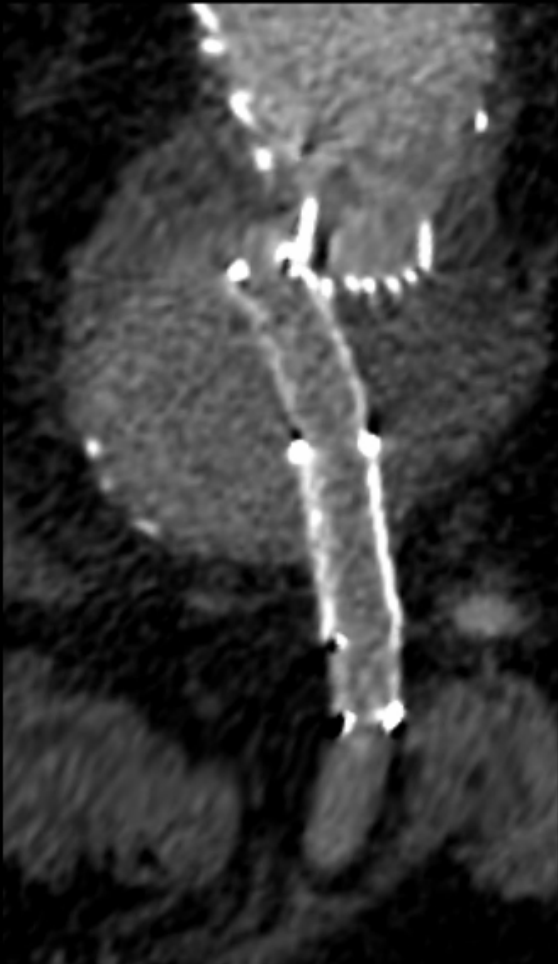
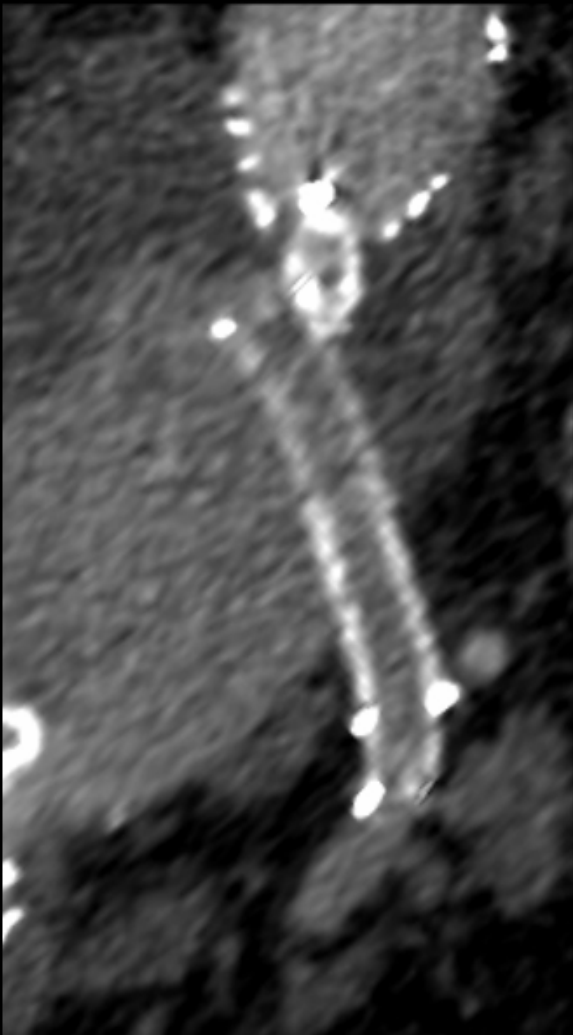
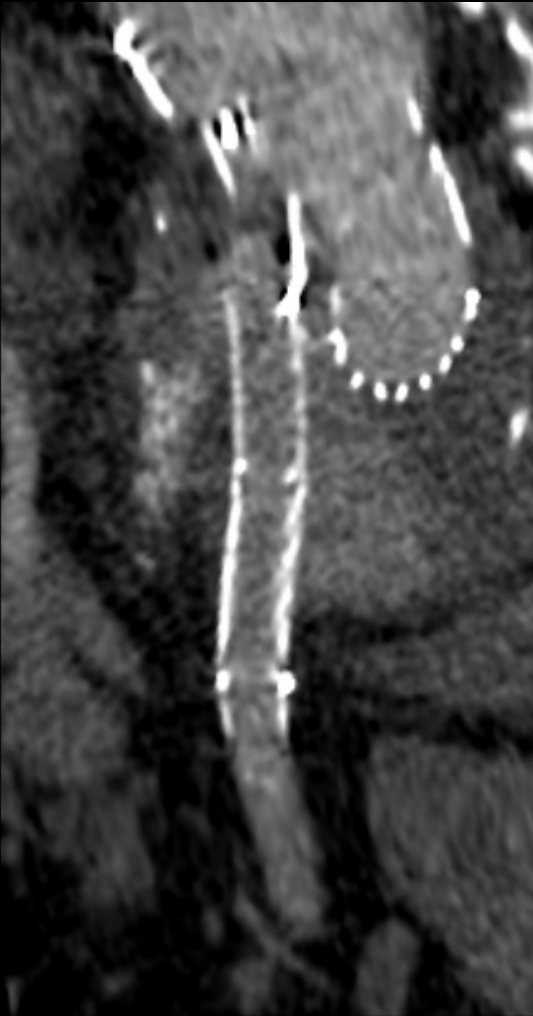
CT scan post-repair (2009)



CT scan – current presentation



CT scan – current presentation



Options for Treatment

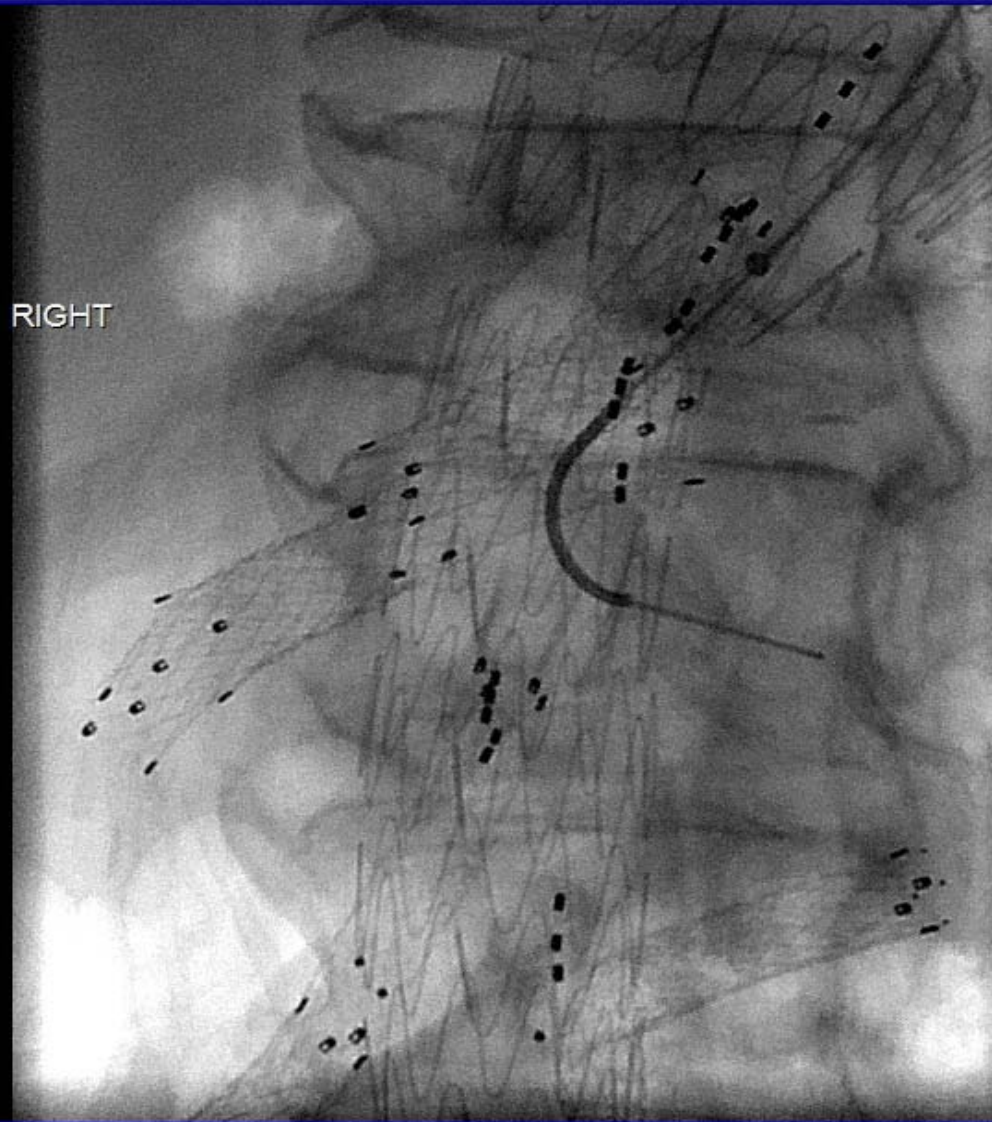
1. Trial of endovascular repair
2. Hybrid endovascular/surgical approach (retrograde access into the SMA)
3. Full surgical SMA bypass with occlusion of the aortic graft branch.

Outline of Plan

Endovascular approach selected

1. Plan to catheterize the endoleak sac via the pre-existing SMA branch cuff
2. Realign the old stent with the SMA origin
3. Bridge any residual gap between the main body of the aortic stent graft and the originally placed SMA covered stent

Procedure – Challenge 1 – Catheterize the Endoleak Sac

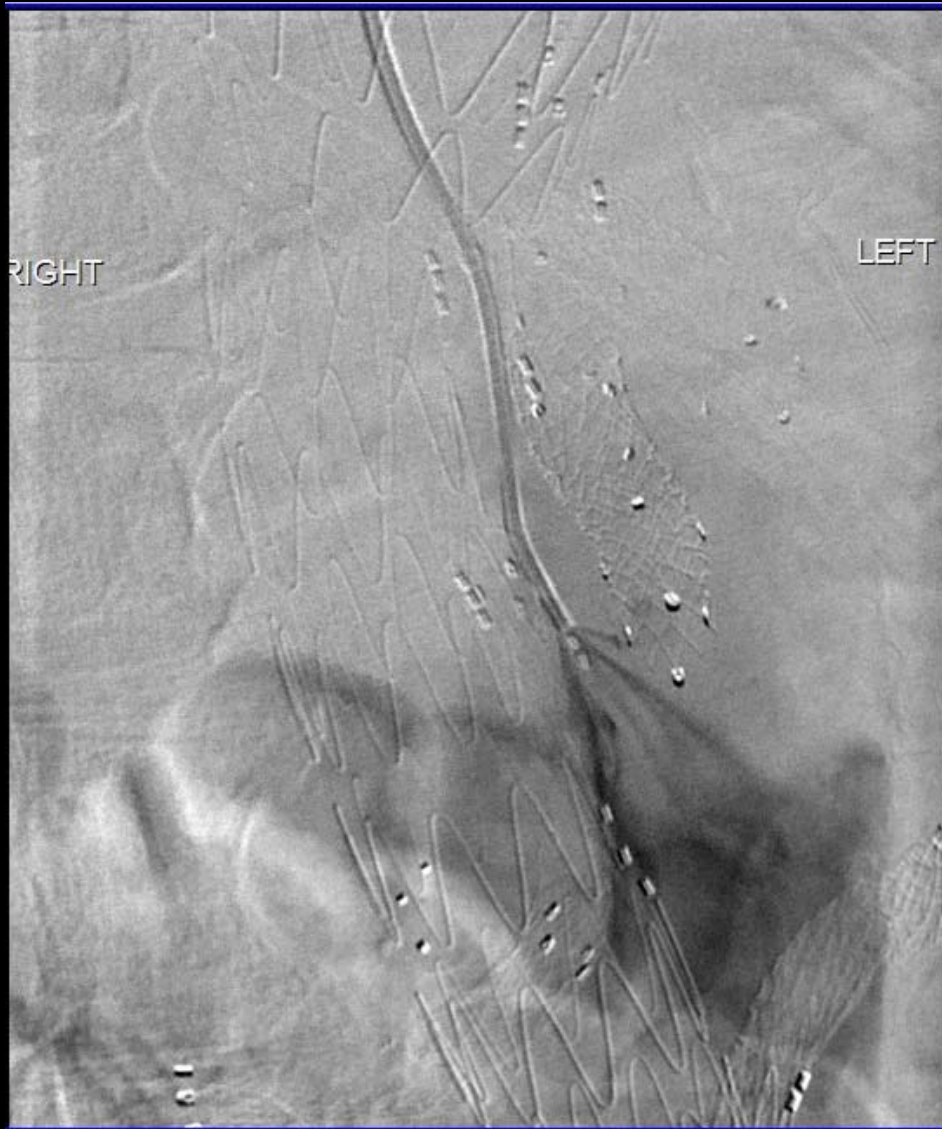

Left transbrachial approach under
US guidance

7 French sheath inserted over
guidewire into the aorta

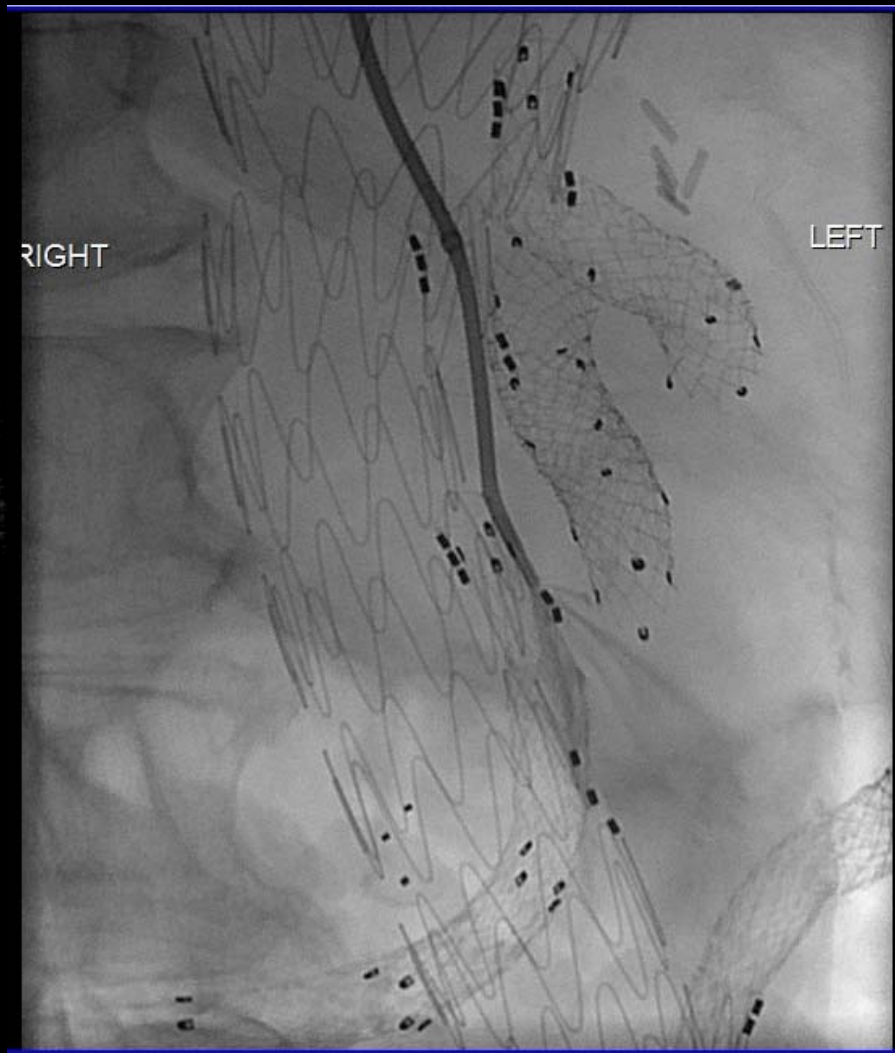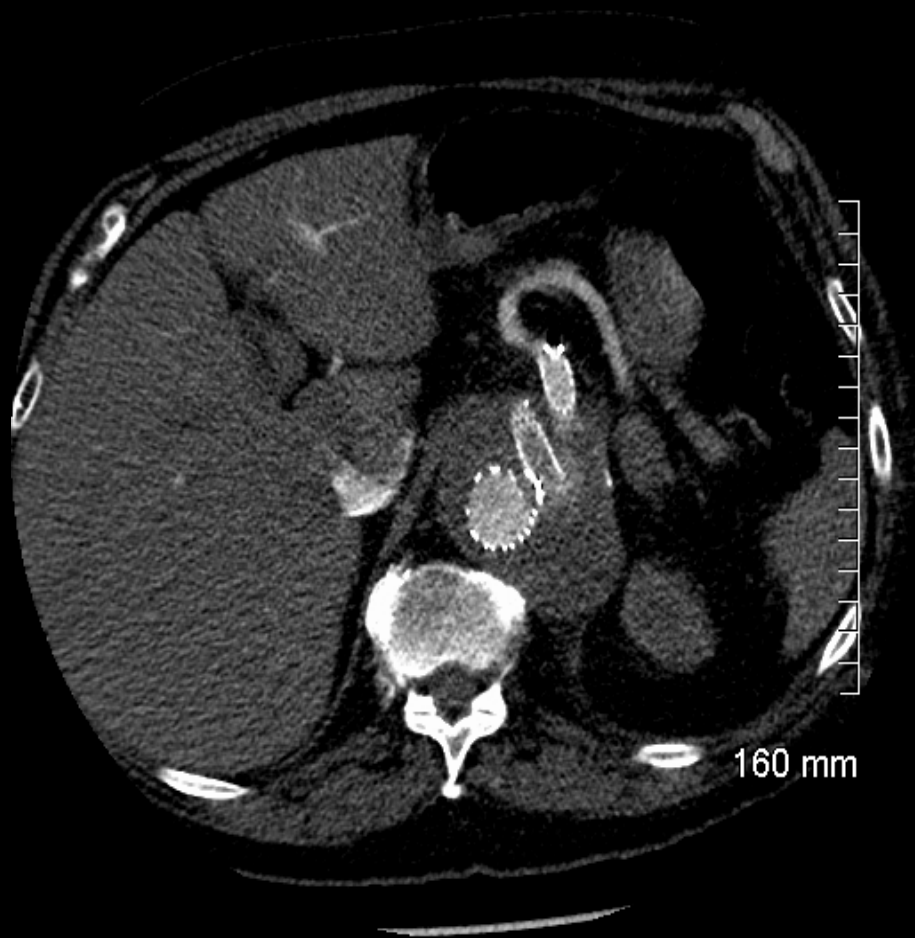
Catheterized SMA origin

Solution 1 – Position confirmed

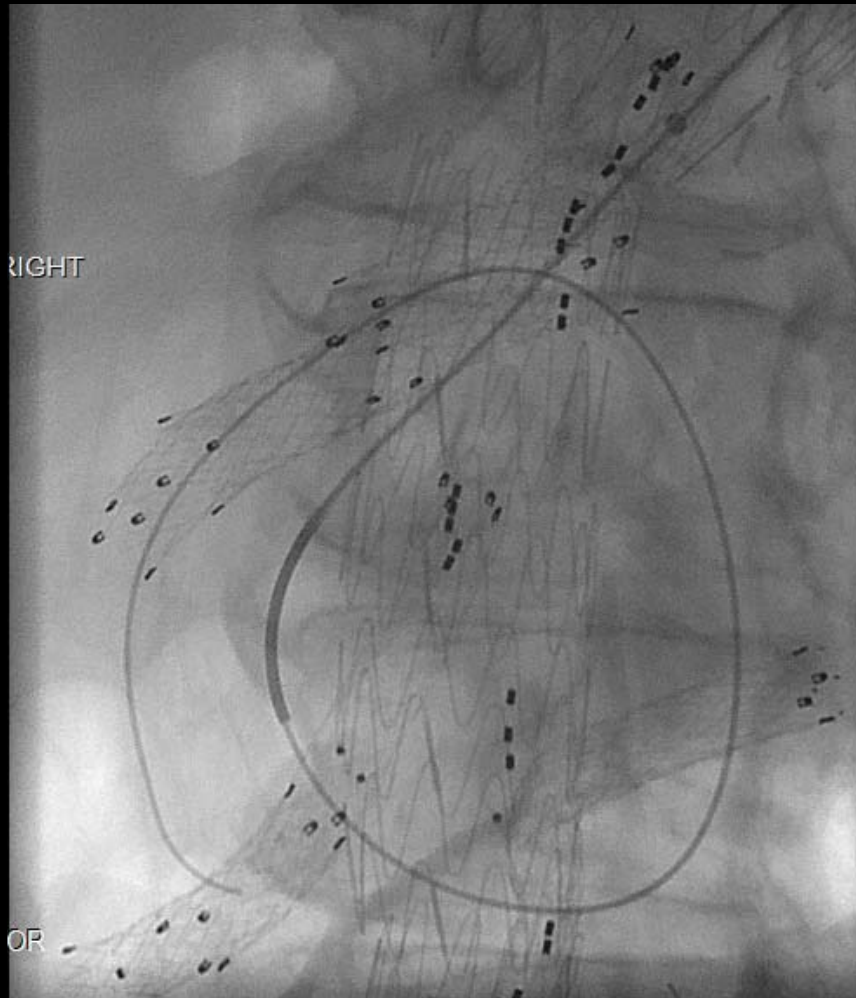


Contrast injected confirmed the catheter positioned in the endoleak sac

Procedure – Challenge 2 – Catheterize the SMA Stent



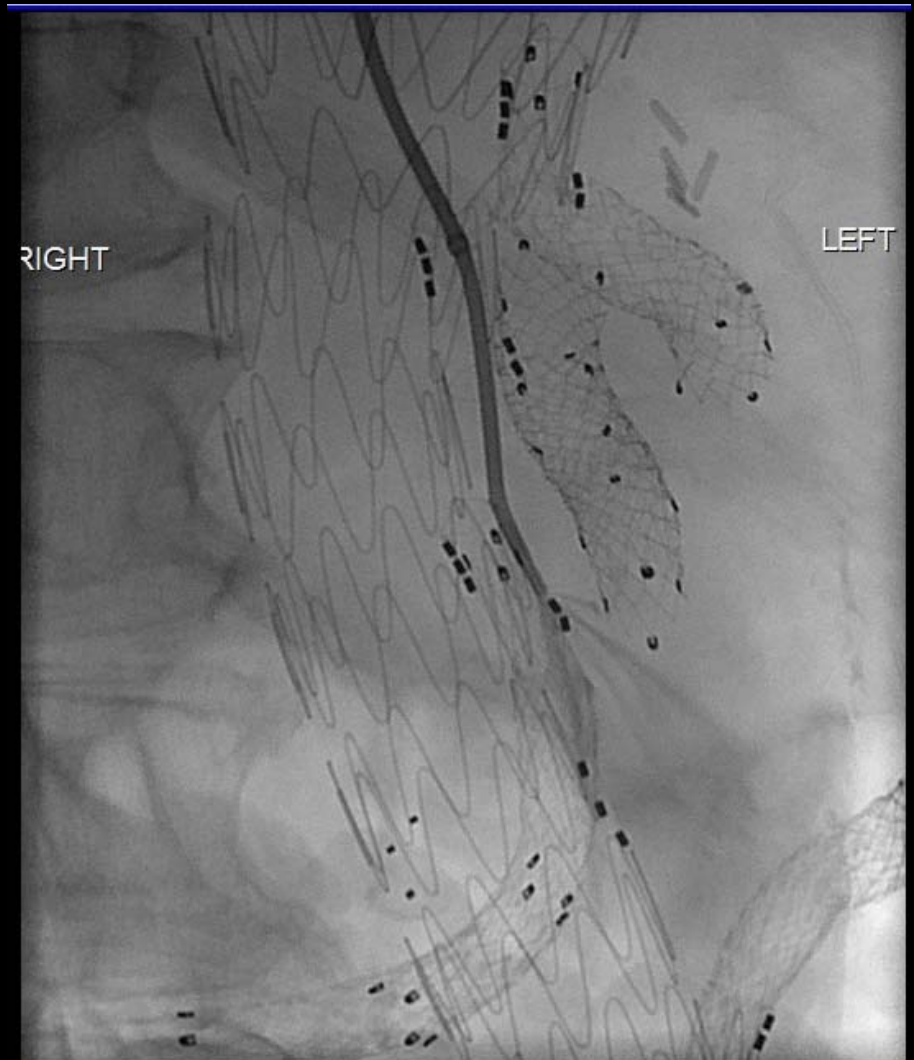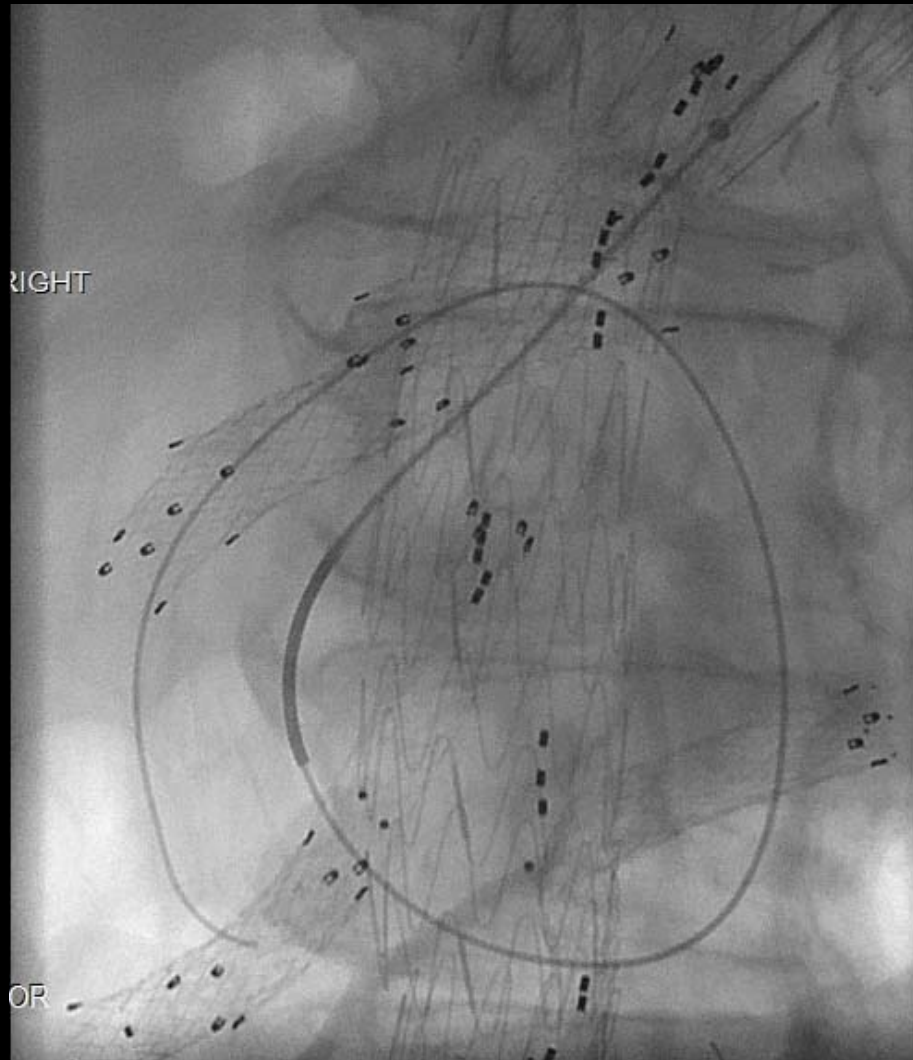
Solution 2 – SMA Stent Catheterized



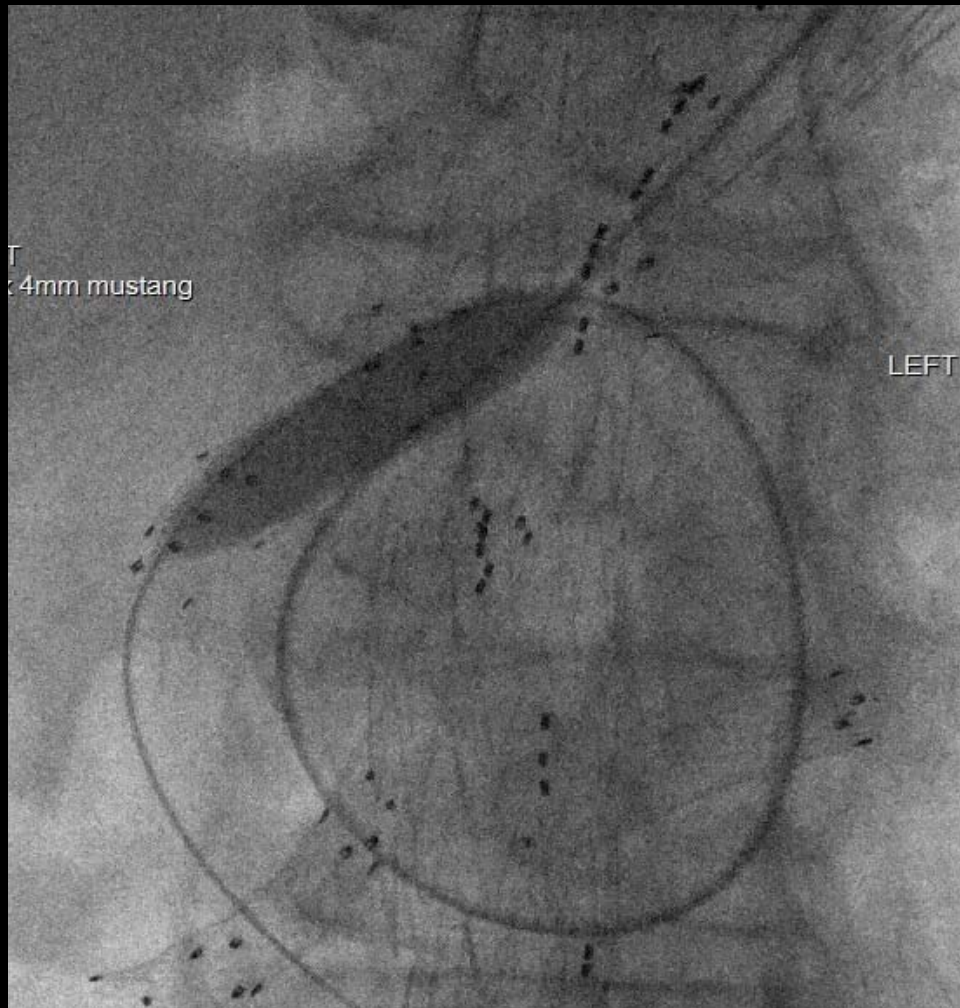
Original SMA covered stent was catheterized by creating a loop with the wire and catheter in the sac

Wire advanced distally into the SMA

Procedure – Challenge 3 – Realign the SMA stent

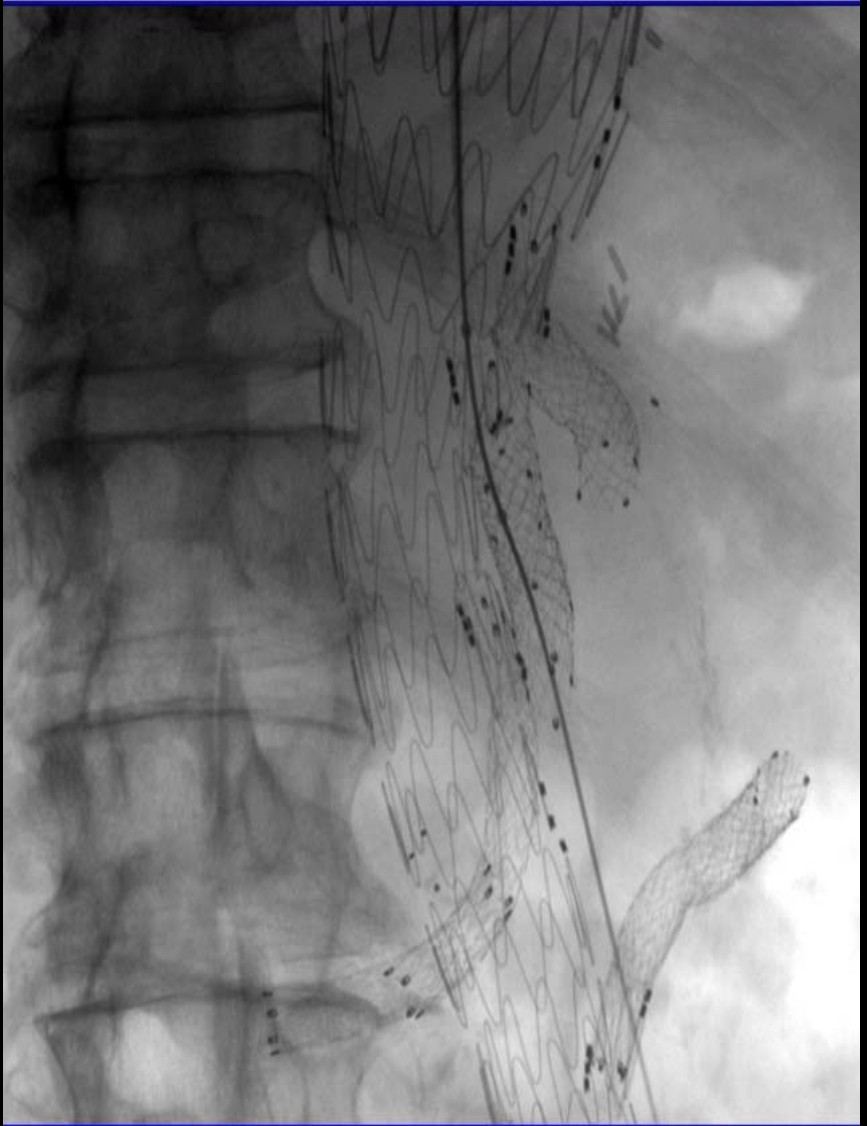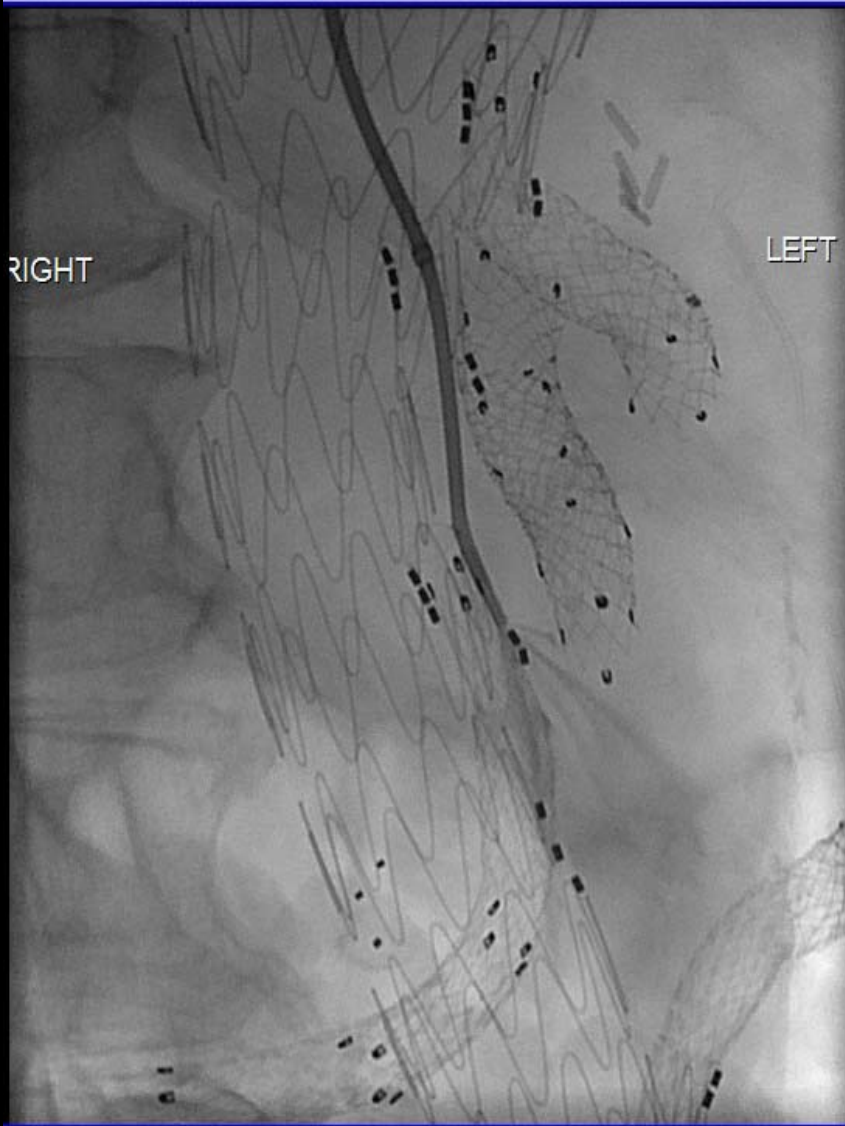


Solution 3 - Aligning the Stent

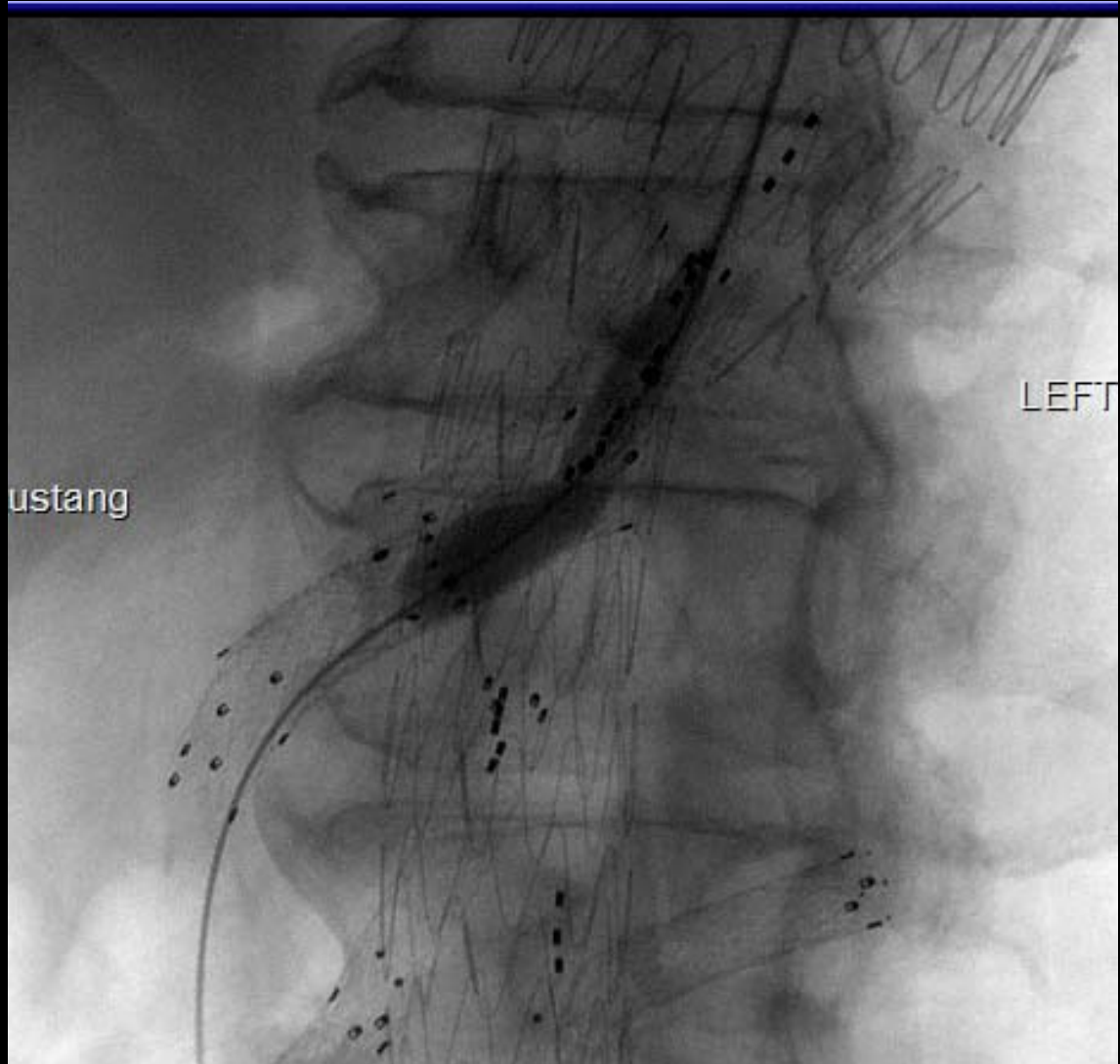


The loop configuration of the wire was straightened using an 12x40mm angioplasty balloon (acting as an anchor) in the distal SMA, and by applying traction to the wire/catheter at the skin exit site

Procedure – Challenge 4 – Bridge the Gap

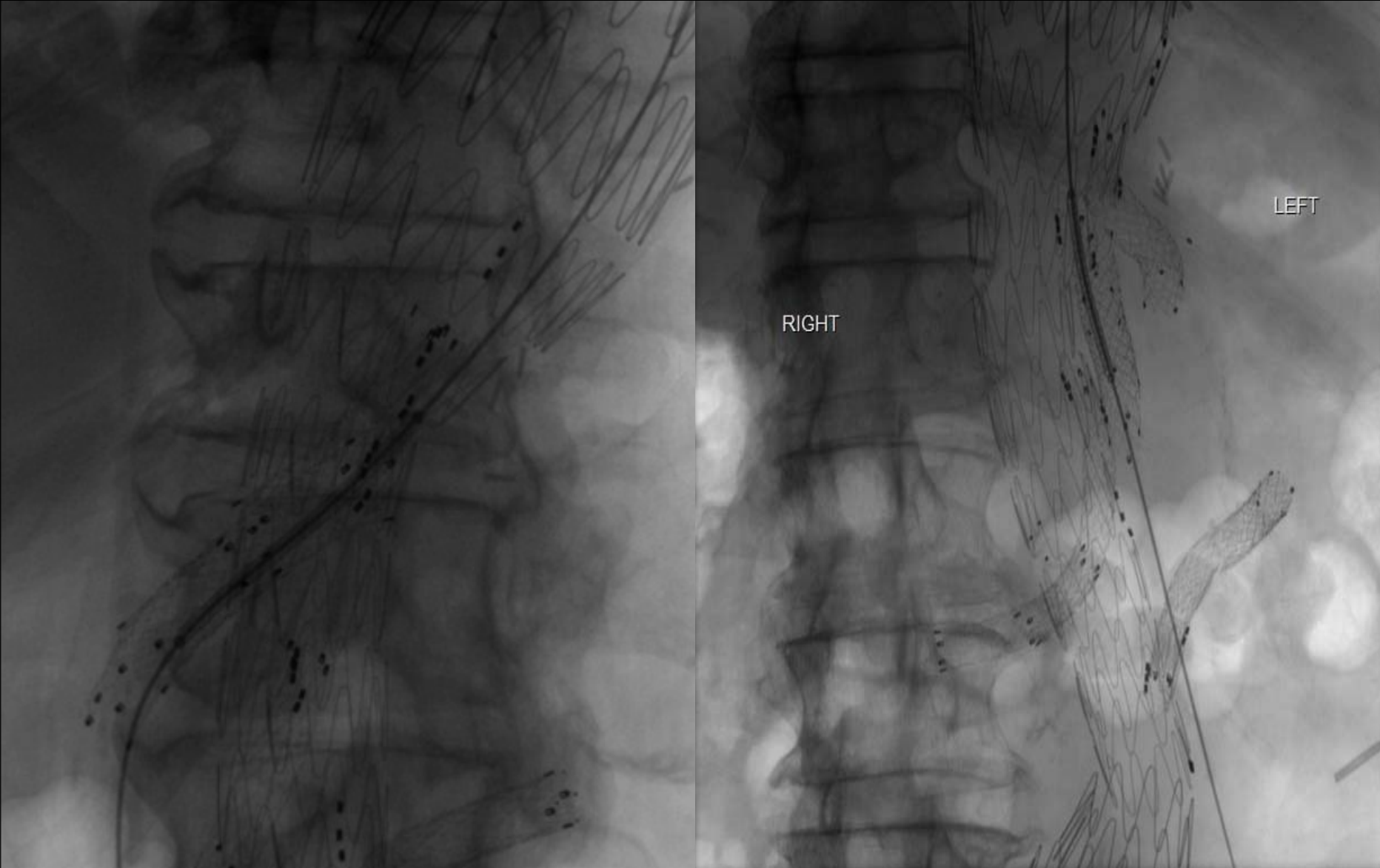

Solution 4 – Bridging the Gap

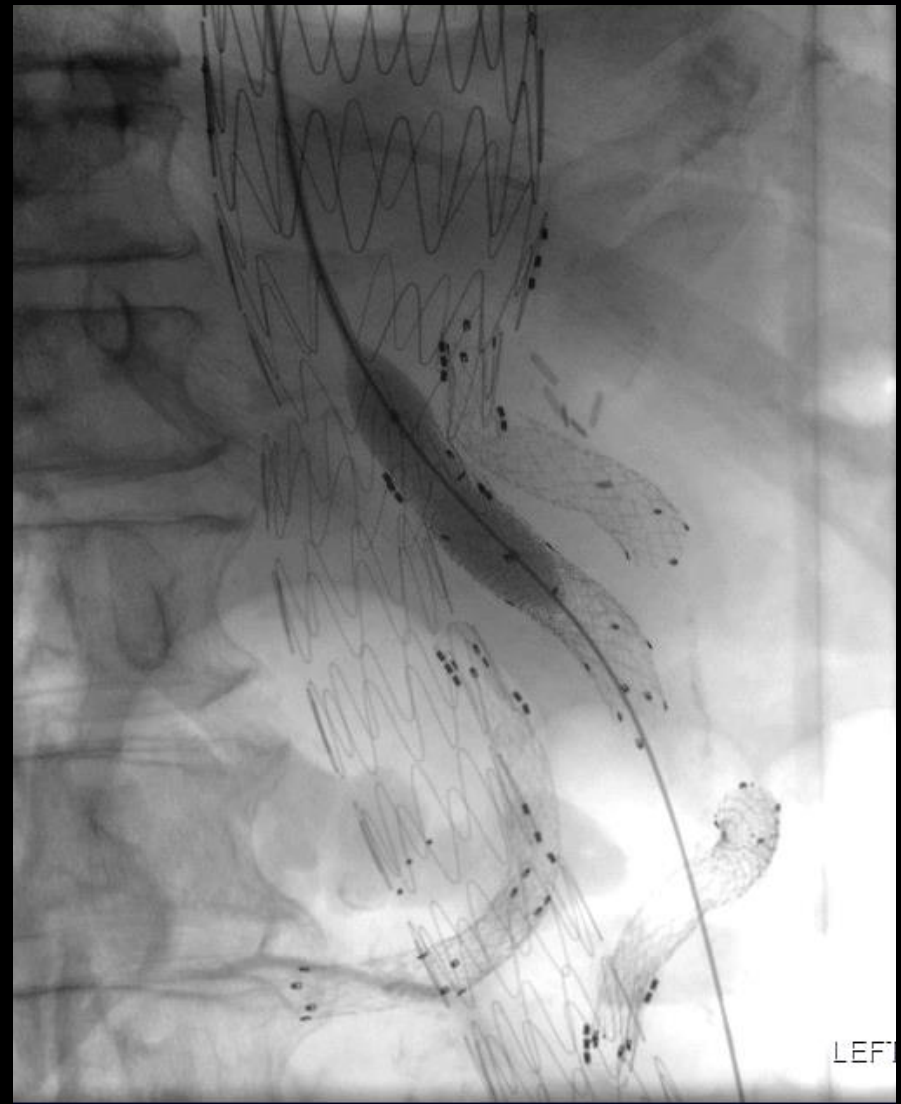
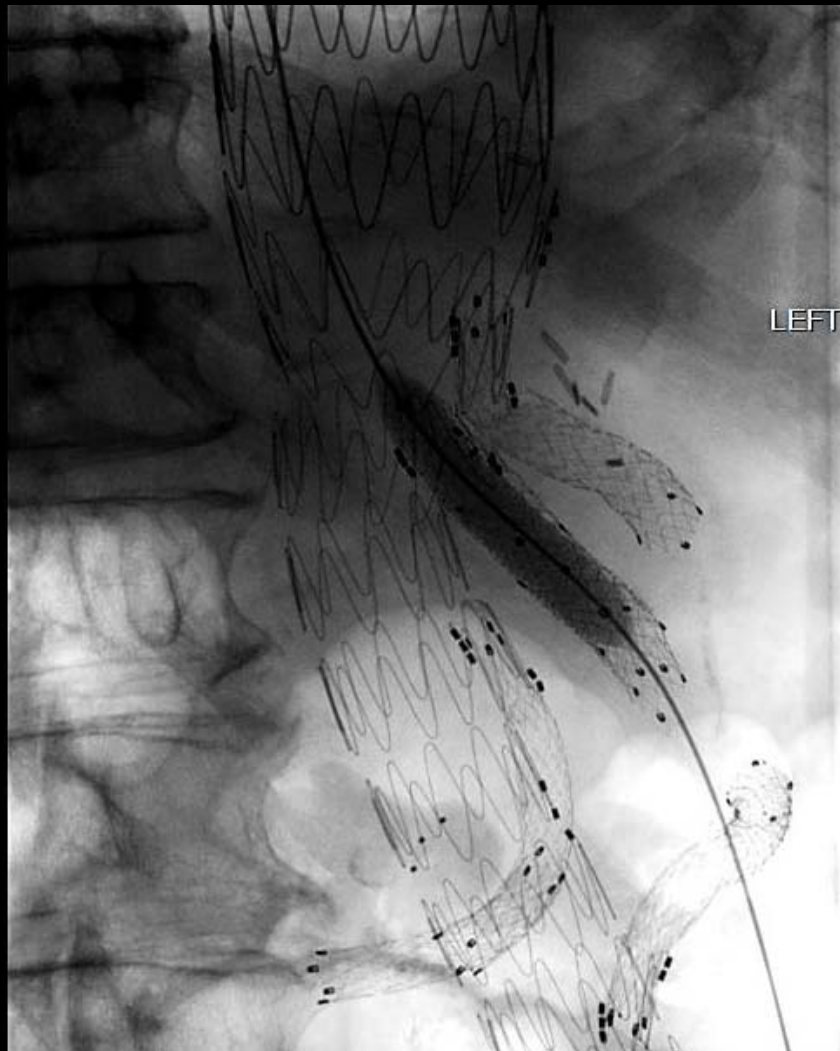
Partially inflated
balloon aided
advancement of the
vascular sheath
across the disconnect

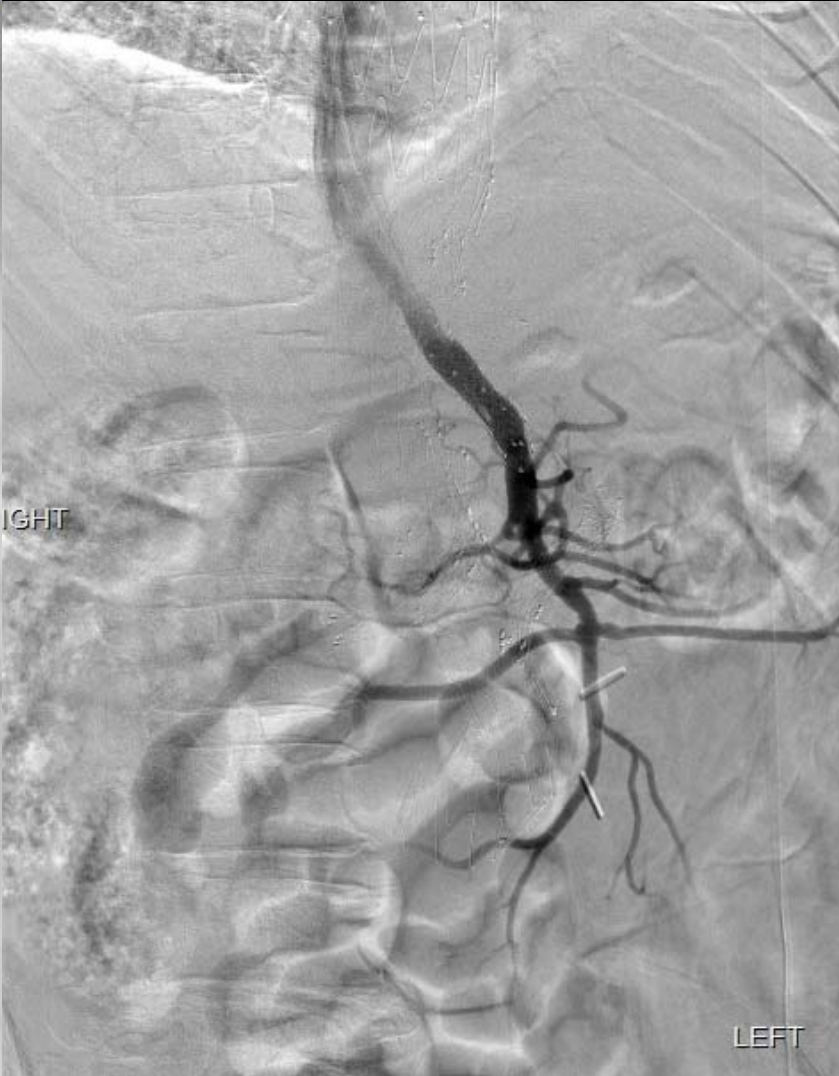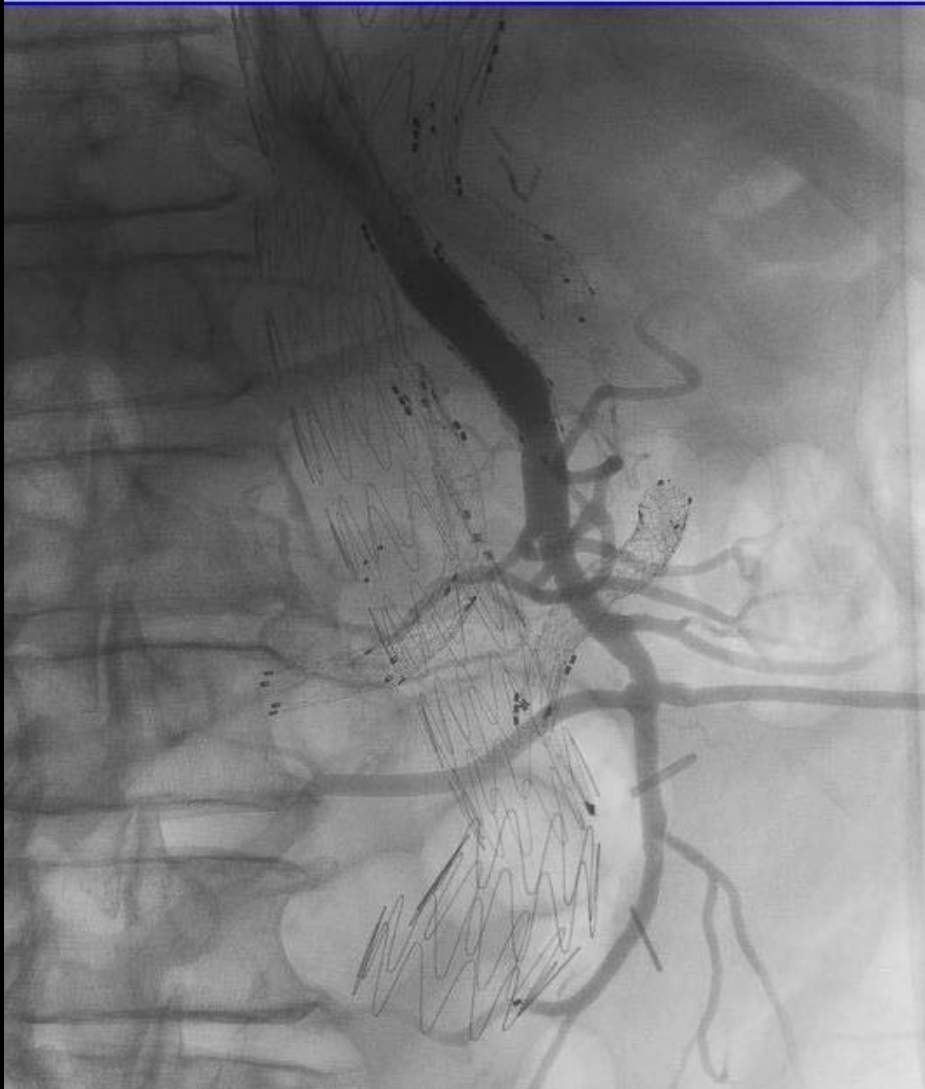Solution 4 – Bridging the Gap



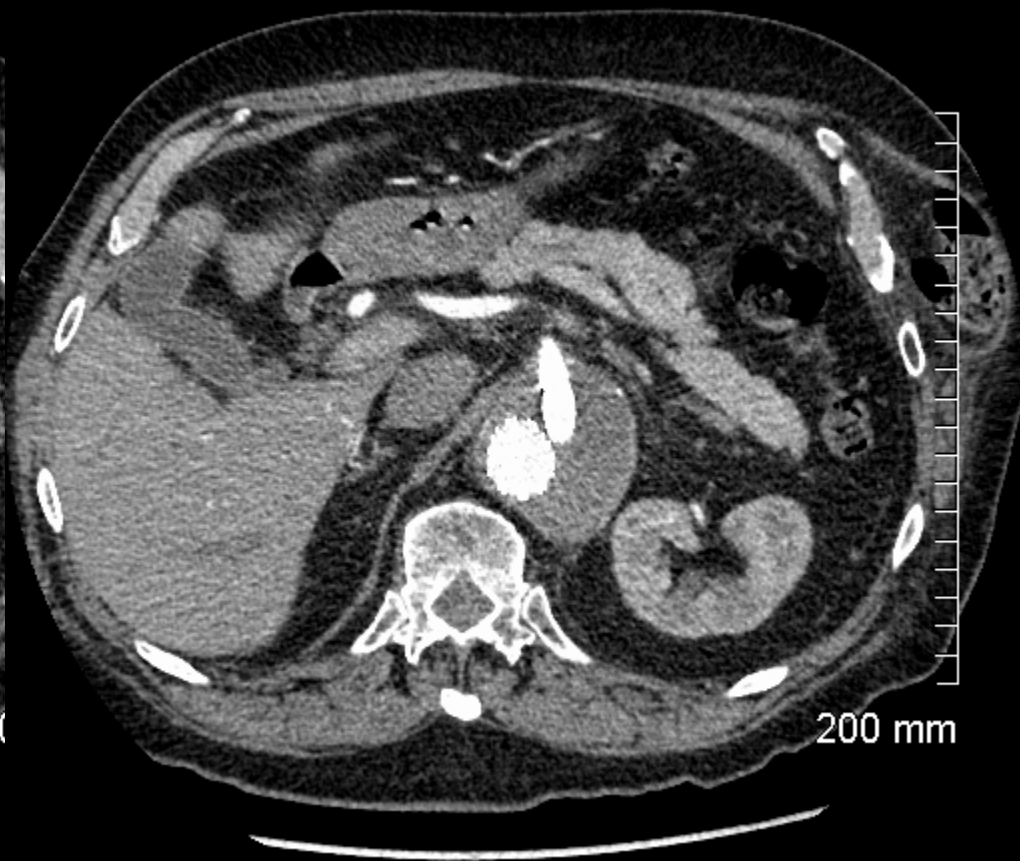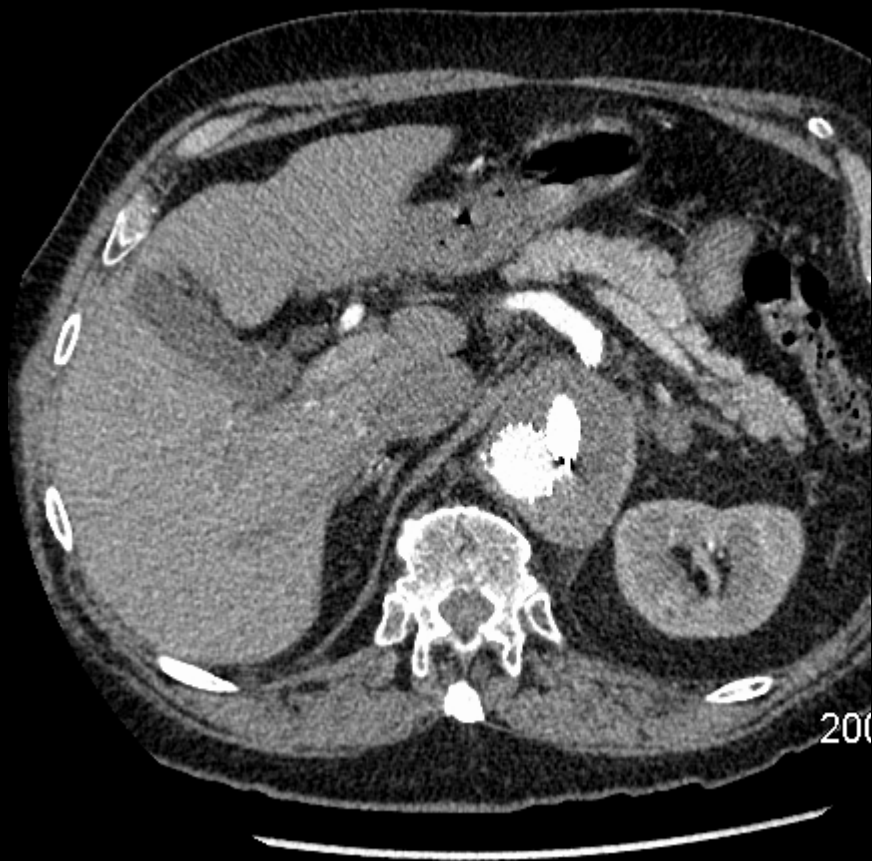Solution 4 – Bridge the Gap – V12 covered stent



Final Run



Follow-up CT May 2015



Summary

- Endovascular repair for TAAA is a relatively recent development with 30 mortality quoted at 1-7.1%** vs 3-19%* for open TAA repair
- Complications of branched endograft repair (that radiologists should be familiar with) include
 - Branch vessel compromise
 - Component migration, separation and endoleaks (in our case)
 - Adverse renal outcomes (catheter manipulation, contrast and atheroembolism)
- Type 3 endoleaks arising from side branch component separation has been reported in up to 6.8%** of cases

*Ricotta, J. Etal . J Endovasc Ther. 2010;17:212-215

**Austermann M, Et al. J Endovasc Ther, 2011;18:157-160

References

1. Troisi, N, Donas, K.P., Austermann M et al. Secondary procedures after Aortic Aneurysm repair with fenestrated and branched endografts, J Endovasc Ther; 2011;18: 146-153.
2. Ricotta, J. Commentary : Fenestrated and Branched Stent Grafts for the Treatment of Thoracoabdominal Aortic Aneurysms. J Endovasc Ther. 2010;17:212-215
3. Austermann M, Et al. Pararenal and Thoracoabdominal Aortic Aneurysm Repair With Fenestrated and Branched Endografts: Lessons Learned and Future Directions, J Endovasc Ther, 2011;18:157-160