

Uterine Arteriovenous Malformation & Uterine Artery Embolization

CAIR CASE OF THE MONTH

Navraj Dhaliwal



Acknowledgements

Lotus Yang PGY5, Saskatoon

Dr. Robert Otani IR RUH, Saskatoon

Dr. Joshua Gitlin Body RUH, Saskatoon

Dr. Nicolette Sinclair IR SPH, Saskatoon

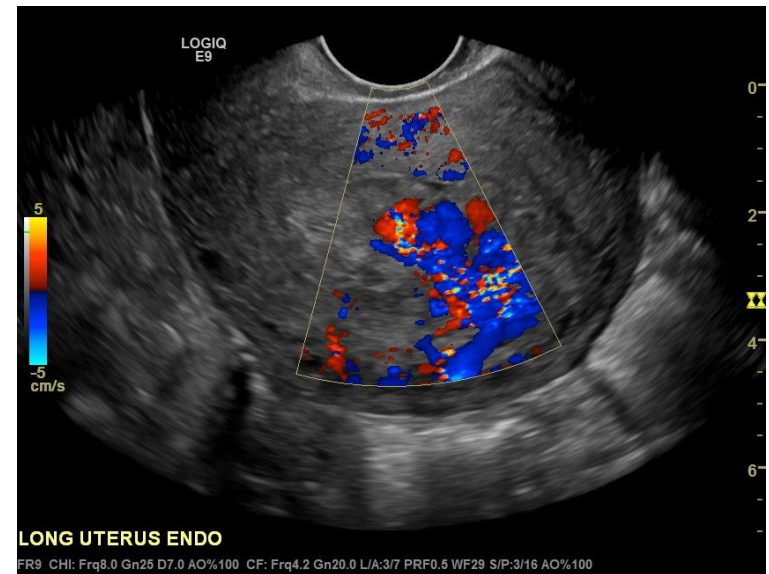
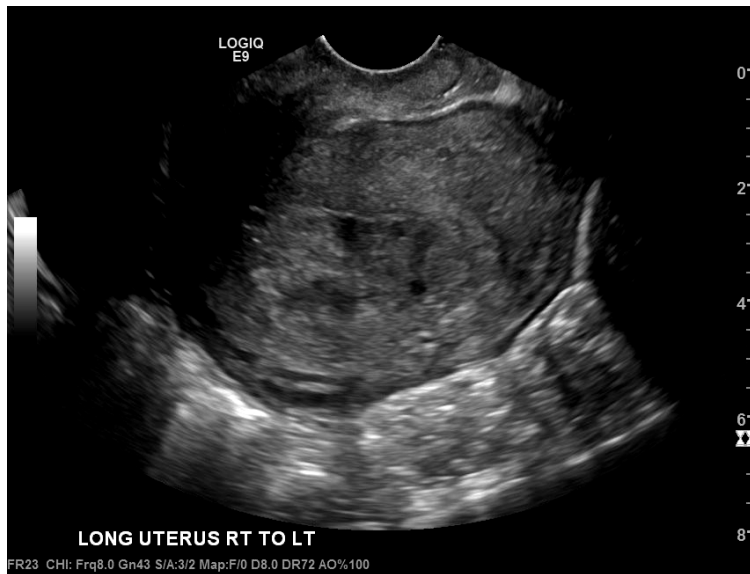
Clinical History

30-year-old female, G1P0

- Twin pregnancy miscarriage at 20 weeks due to rupture of membranes.
- Manual removal and D&C performed for retained placenta, complicated by ongoing hemorrhage and transfusion of 3 PRBC units.
- Presented with ongoing vaginal bleeding PPD 11 in a peripheral center.
- Ultrasound requested, R/O RPOC.

Ultrasound post 1st D & C and ongoing bleeding – ?RPOC

- Thickened and heterogenous endometrium, measuring 2.8 cm in the fundal region.
- Demonstrates markedly increased vascularity, particularly in the fundal region.



Clinical History

- PPD 11 US consistent with RPOC.
- 2nd D&C performed.
- Again, complicated by ongoing hemorrhage and 2 units of PRBC were transfused.
- Discharged home shortly afterwards.

Clinical History

- PPD 16, repeat presentation with vaginal bleeding.
- Repeat US consistent with RPOC.
- 3rd D&C performed and discharged home shortly afterwards.
- OBGYN suggests transfer to tertiary center if there is a repeat presentation.



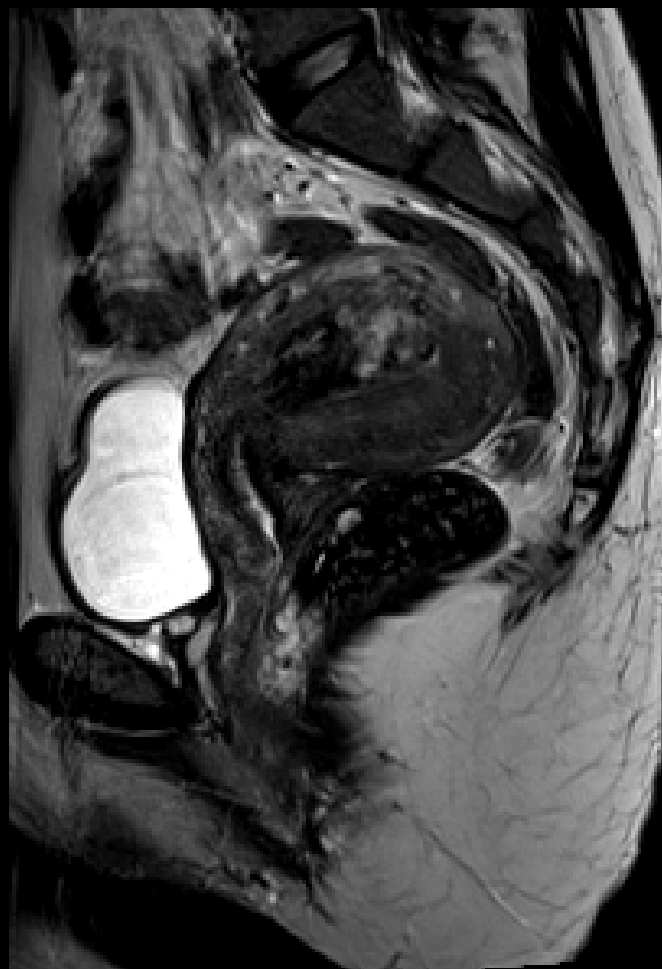
Clinical History

- PPD 20, repeat presentation with bleeding.
- Transferred to our tertiary care center.
- MR requested for ?AVM.

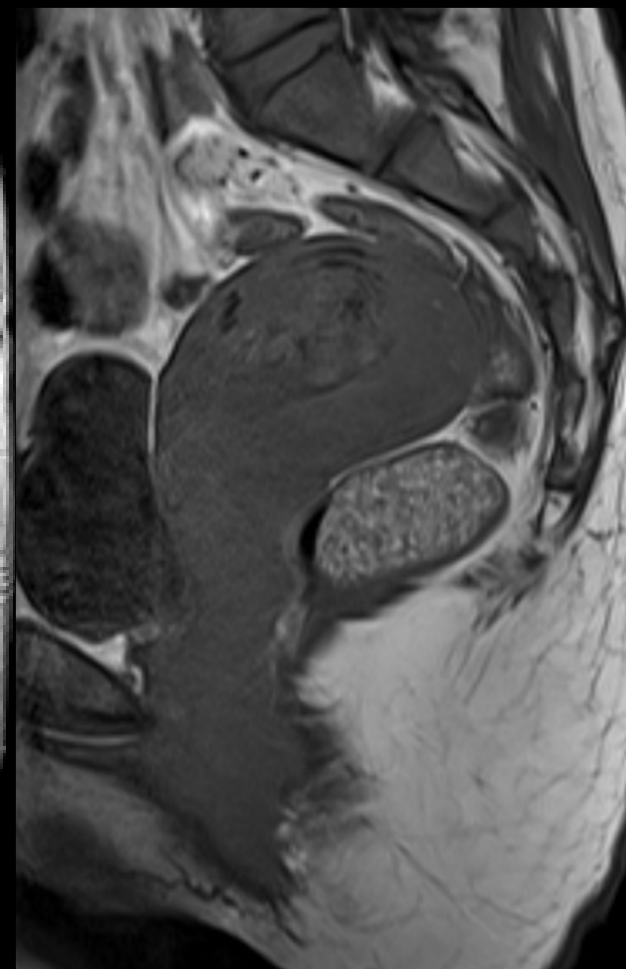


MRI post 3rd D & C and persistent bleeding – ?AVM

- The endometrium demonstrates marked T2 heterogeneity with tubular flow voids extending from the endometrium into the myometrium in the fundus.
- Heterogeneous T1 and T2 mass-like region centered in the fundal endometrium and extending into the anterior myometrium.

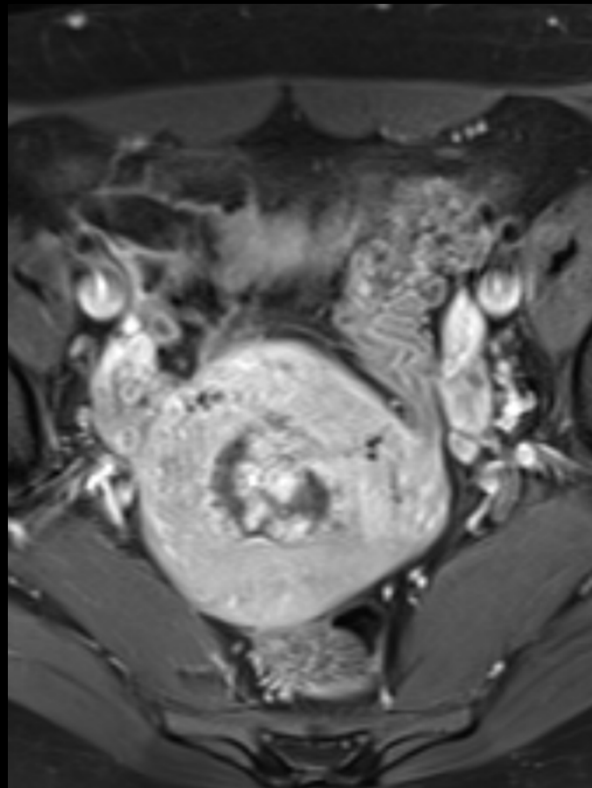
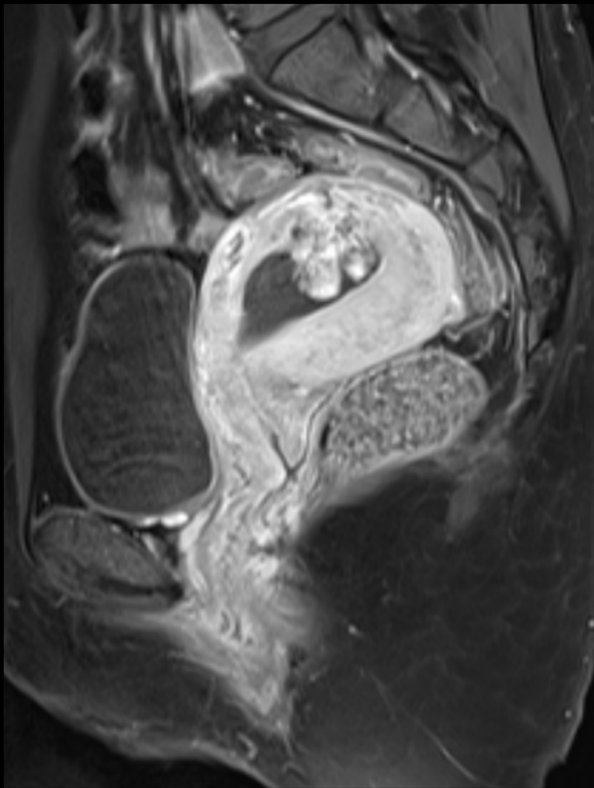


T2



T1

MRI post 3rd D & C and persistent bleeding – ?AVM

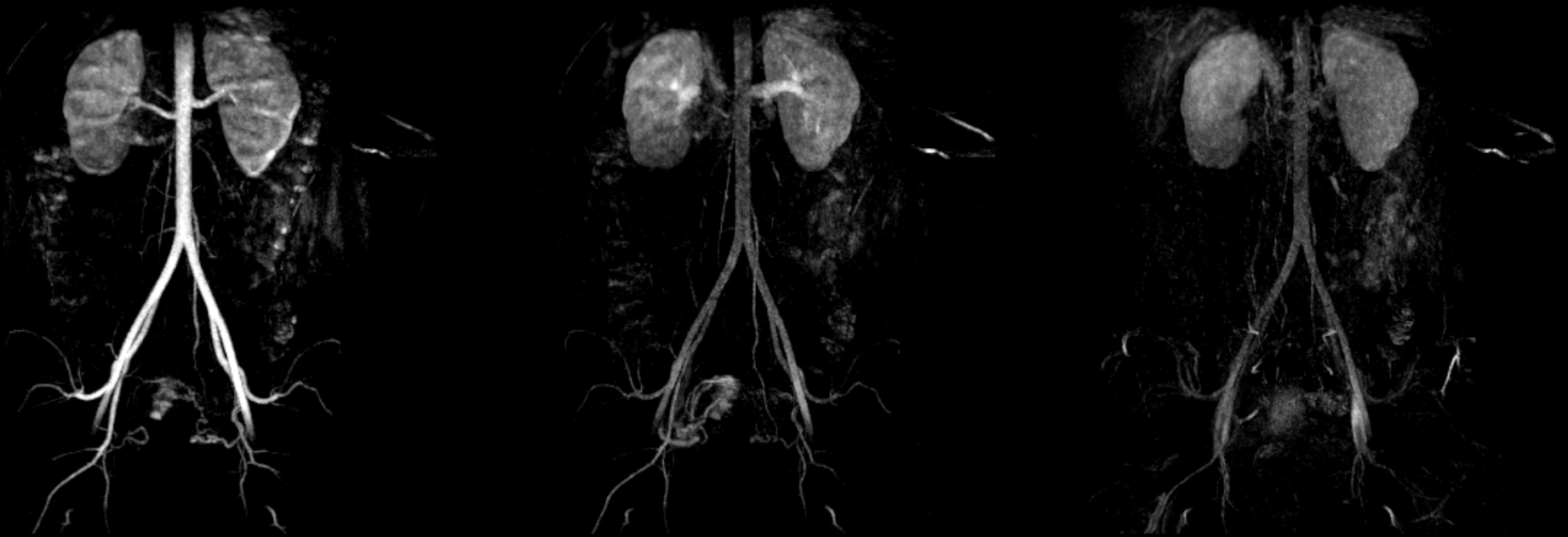

T1 FS post-Gad

- The lesion demonstrates avid arterial phase hyperenhancement.

MRI – ?AVM

- On time-resolved MR angiography, the lesion is supplied by the bilateral uterine arteries, apparently more pronounced on the right. There is early venous drainage on the right.
- Findings are most in keeping with an AVM. RPOC is considered less likely, given involvement of the myometrium.



Time-resolved MRA (TWIST)

Uterine AVM

- Abnormal arteriovenous connections contained within the uterus.
- Congenital or acquired.
- Can be clinically occult or manifest as life threatening hemorrhage.
- Less than 150 cases reported in the literature as of 2018.
- Prospective study of 959 women using US identified 1 (0.1%) – they presented with massive periodic hemorrhage post D&C with a history prior myomectomy and multiple gestations.
- Repeat instrumentation can worsen hemorrhage.

Uterine AVM Treatment

- Expectant management (with possible spontaneous resolution)
- Limited reports on conservative management with gonadotropin releasing hormone agonists
 - Selection criteria include small size, lack of hemorrhage and elevated levels of estrogen
- Uterine artery embolization
- Technical success rate of 61% with primary embolization and 91-96% secondary embolization
- Hysterectomy

Uterine Artery Embolization (UAE)

- UAE has been performed for uterine AVM since the late 1980's
- Indications include primary treatment for AVM and reduction in size prior to definitive hysterectomy
- Various embolic agents have been employed with selection depending on operator experience and preference
 - Including: glue, Gelfoam, coils, PVA and microspheres and combinations of them
 - No significant difference between agents has been reported
- A review including 54 cases identified no major complications; previously described complications of uni- or bilateral UAE include uterine necrosis, sepsis and pulmonary embolism
- The most common minor complication encountered was pelvic pain

Conception and UAE

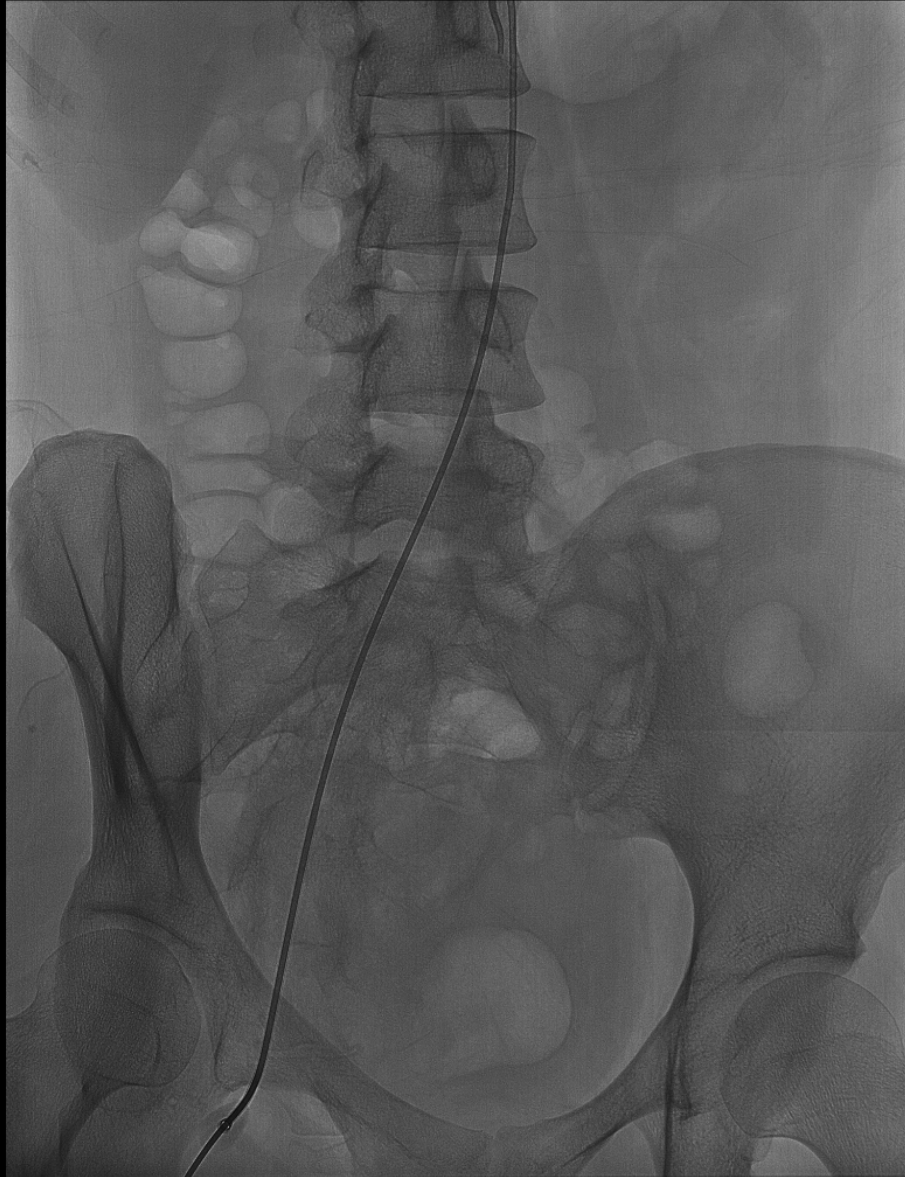- UAE is thought to decrease fertility by inducing ovarian insufficiency
- Data concerning preserved pregnancy outcomes is limited by small sample sizes, unknown fertility status prior to embolization and publication selection bias favoring cases of preserved fertility
- Multiple small studies have demonstrated varying degrees of preserved fertility post UAE
- 22 patients with uterine arteriovenous malformation treated with expectant management (9/22) and uterine artery embolization (13/22) were followed for a median range of 38 months (about 3 years); all patients treated with UAE or expectant management who wanted to conceive became pregnant (EM 2 and UAE 8). (Delplanque et al. 2019)
- 33 patients underwent uterine artery embolization for symptomatic uterine AVM. Technical success in 100%. Bleeding control was achieved in 96%. 6 pregnancies occurred post embolization, out of which 4 women had full term pregnancies without complication and 2 were in the 2nd trimester of uncomplicated pregnancies. No post-embolization related miscarriage. (Ghanaati et al. 2022)

Pregnancy and UAE

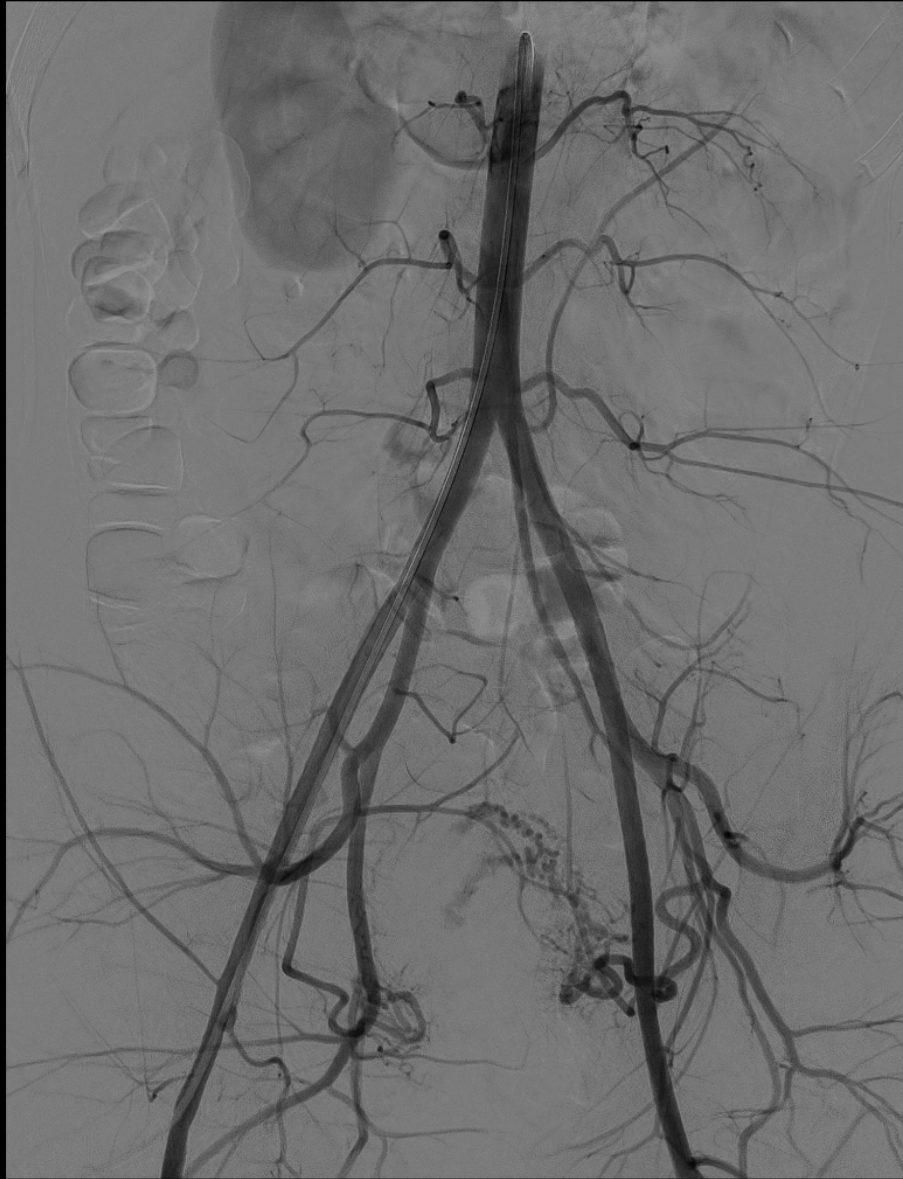- Data concerning pregnancy outcomes and UAE is limited
- UAE may be associated with an increased risk of placental abnormality, specifically placenta accreta
- Delplanque et al. 2019 report no difference in gestation or delivery between the expectant management group and the UAE group

Clinical Course

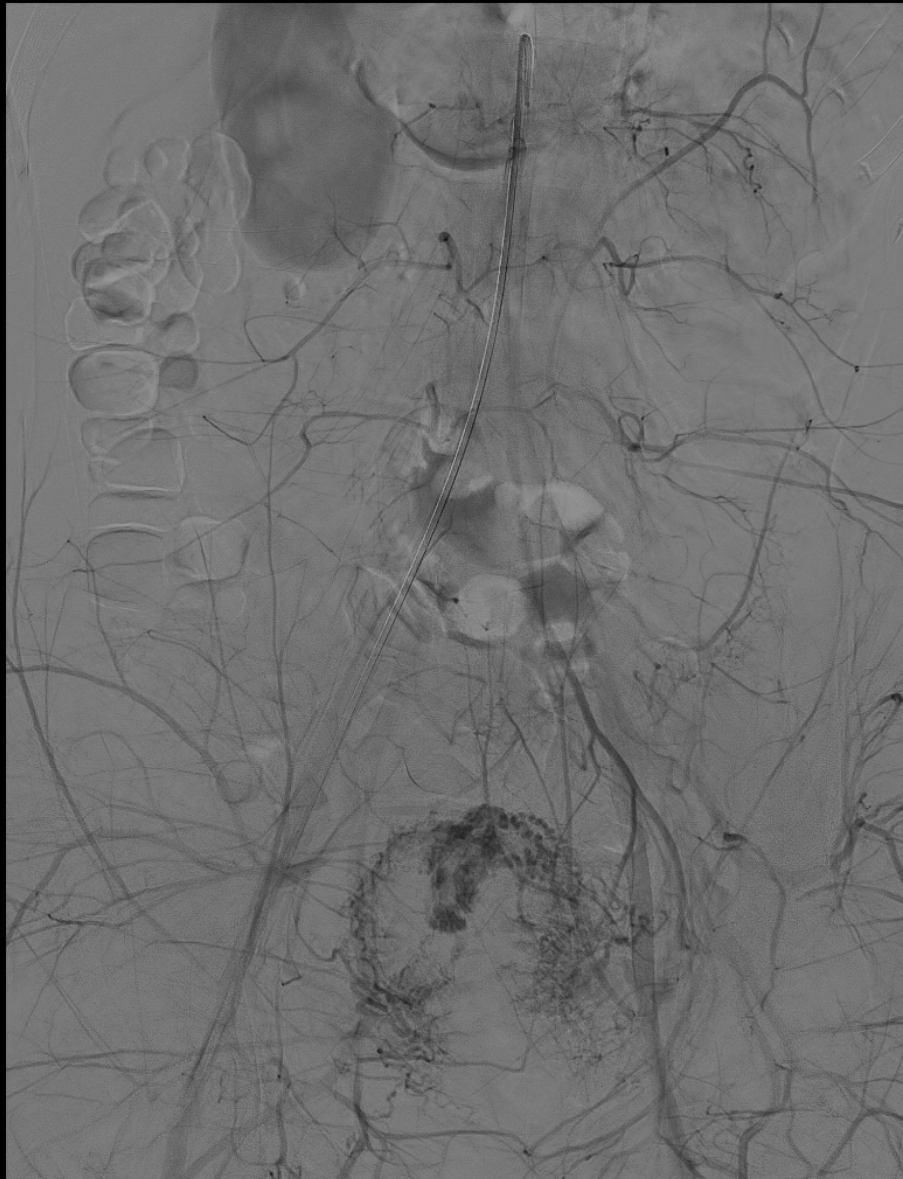
- PPD 21 MR consistent with AVM.
- IR consultation is suggested.
- IR reviewed the risks and benefits of the procedure with the patient.
- The patient wanted to preserve fertility and the evidence regarding maintained fertility post UAE was reviewed with the patient however no guarantee was made.
- IR proceeded with angio and UAE on PPD 22.



- Right common femoral artery was accessed.
- 5 Fr pigtail catheter was advanced into the lower abdominal aorta above the common iliac artery bifurcation.
- Infra-renal aortic angiogram performed to evaluate pelvic arterial anatomy.

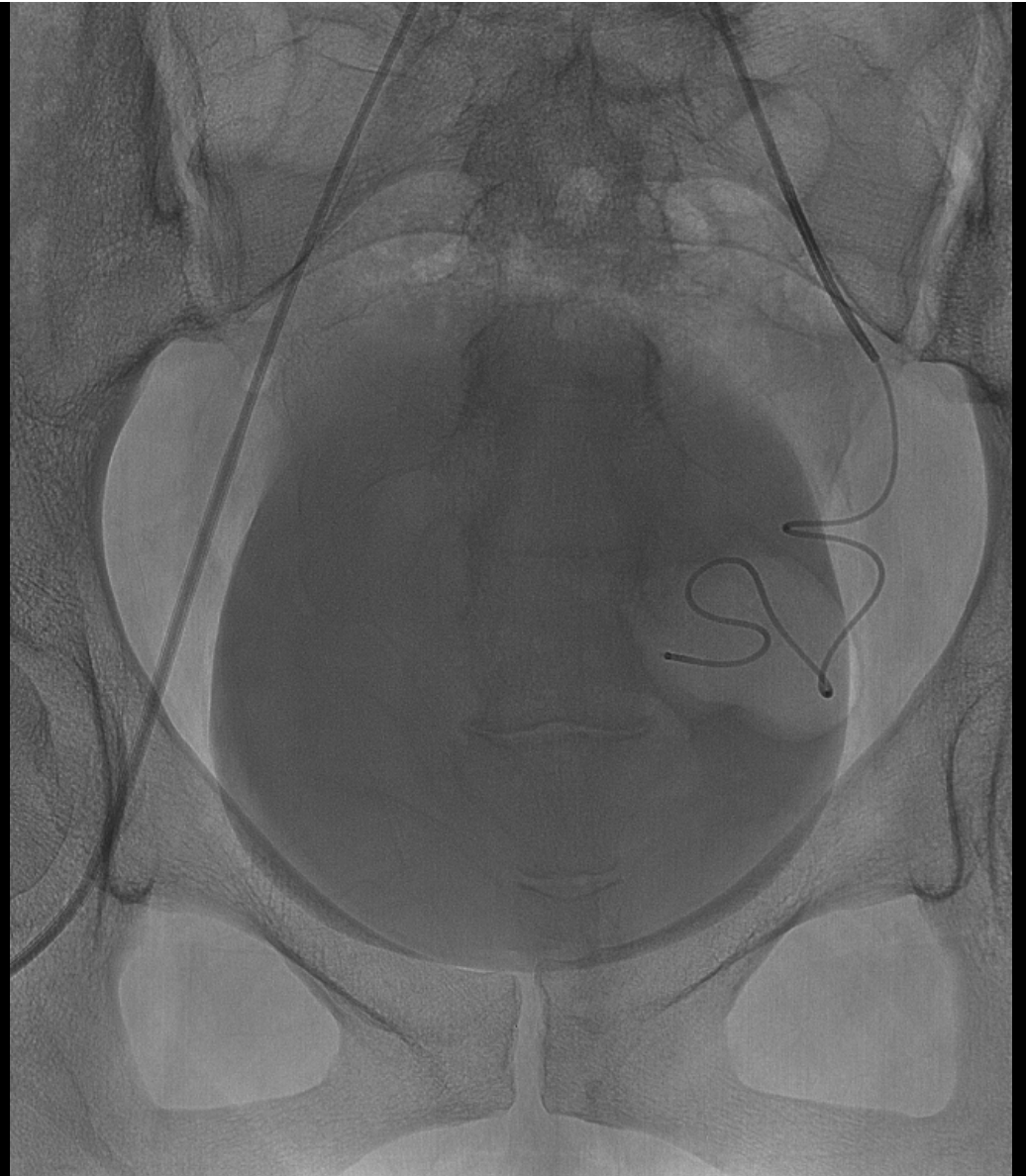

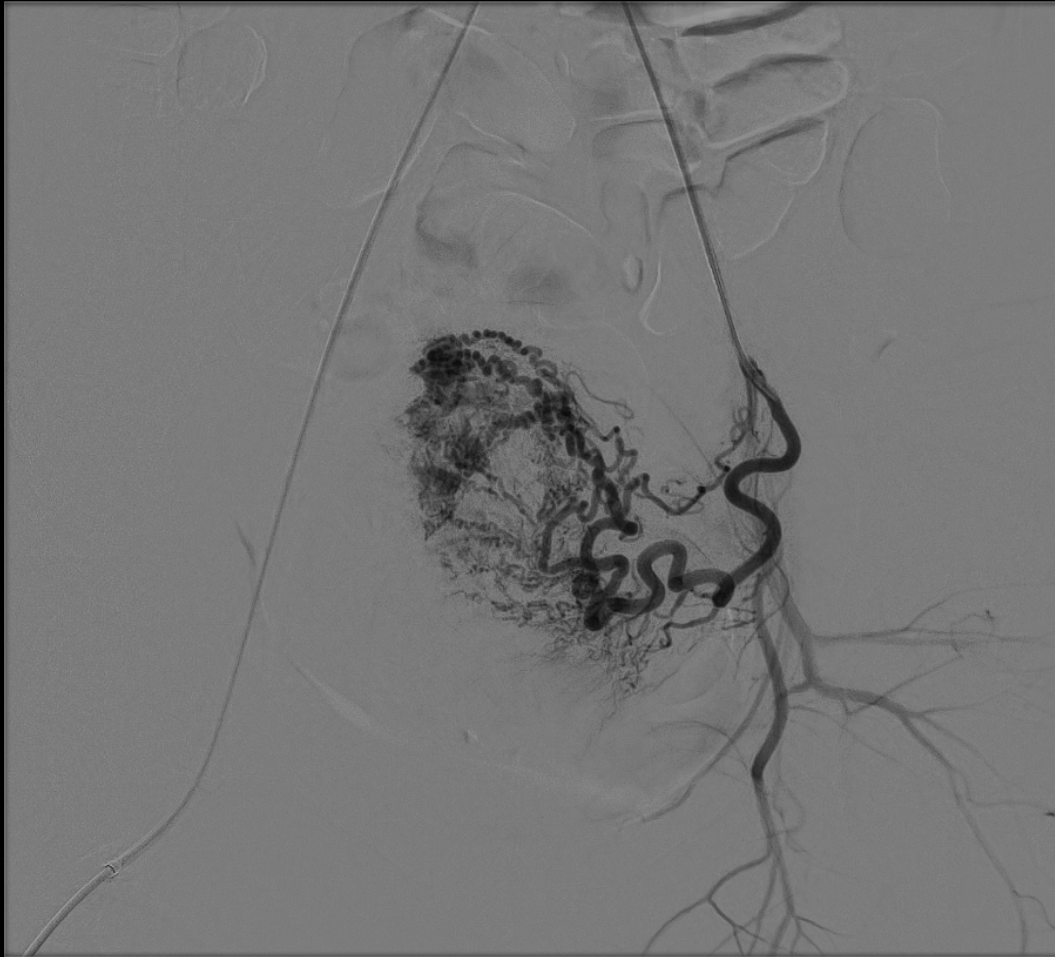
- Abnormal early blush of contrast opacification in the superior aspect of the uterus, verifying the suspicion for uterine arterial venous malformation.
- Preferential flow via the left uterine artery. Therefore, a left uterine artery approach was planned.



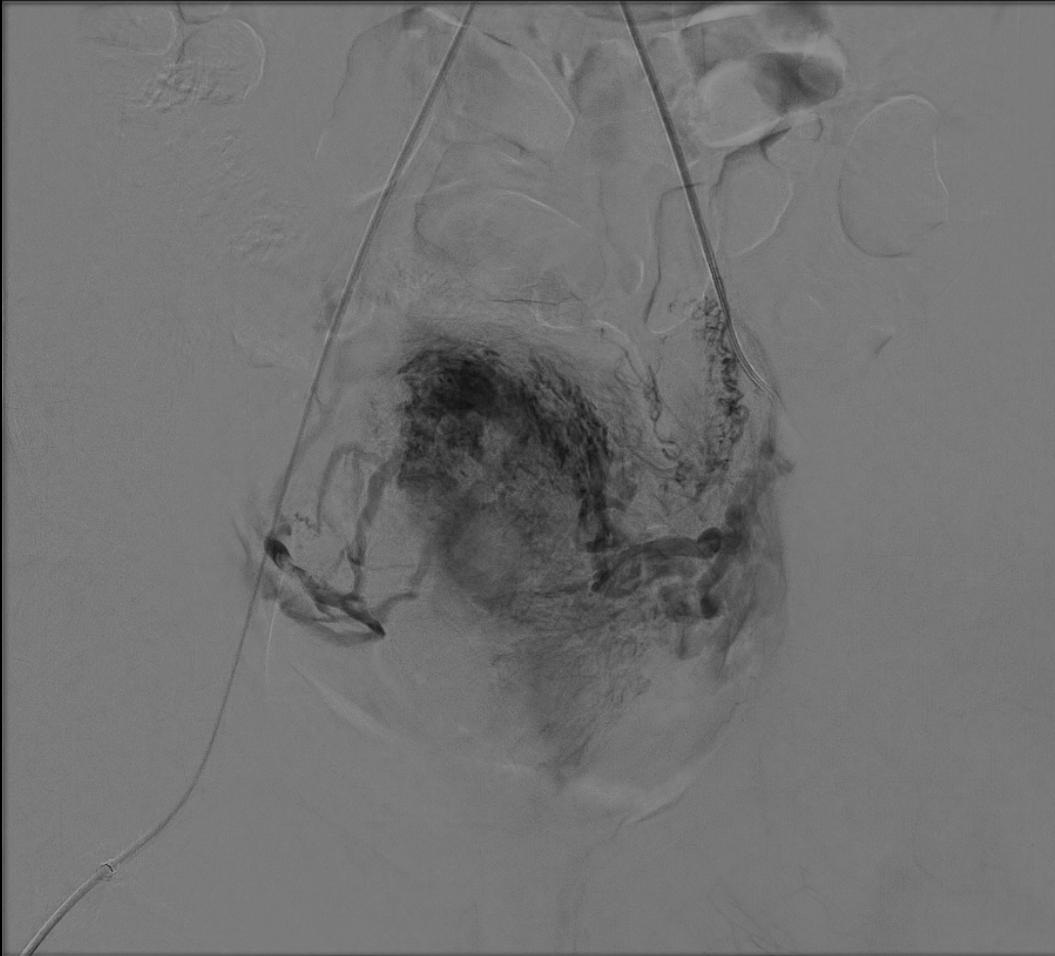
- Abnormal early filling was accompanied by abnormal early venous drainage into the adnexal regions bilaterally.

- The pigtail catheter was exchanged for a C2 catheter and manipulated into the left common iliac artery.
- A 5 Fr uterine artery catheter was then used to enter the left uterine artery.
- Finally, a 2.8 Fr Progreat microcatheter and GT wire was navigated into the distal left uterine artery.

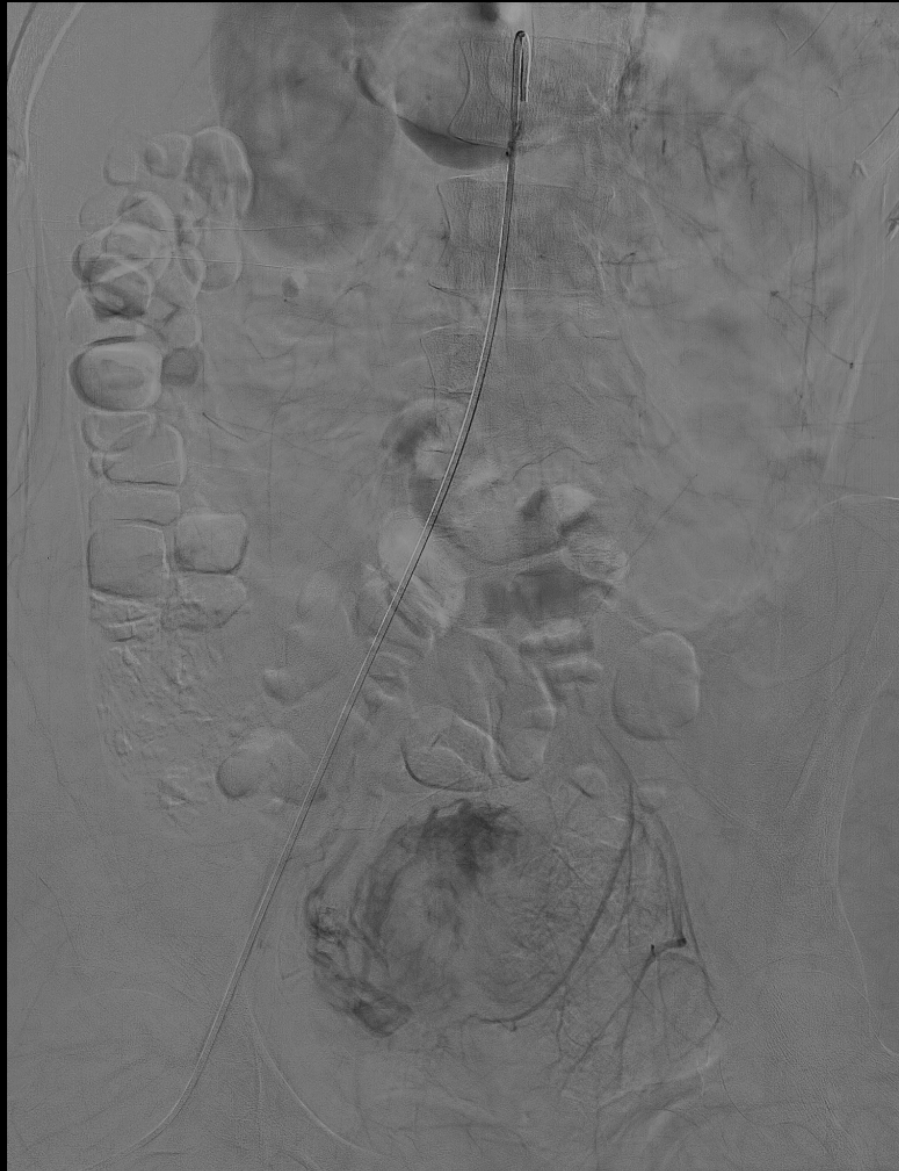



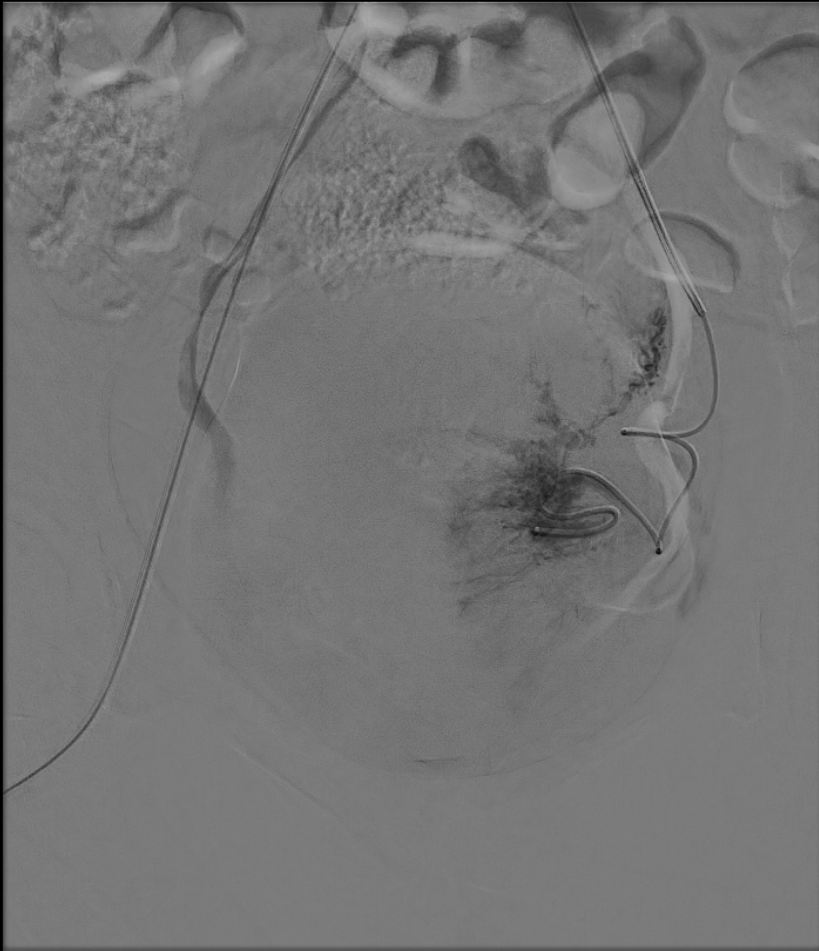
- Distal left uterine artery angiogram.
- Redemonstration of significant abnormal early arterial vascularity in the uterine fundus, on a background of normal uterine spiral arteries.
- Note is made of the tubo-ovarian branch.



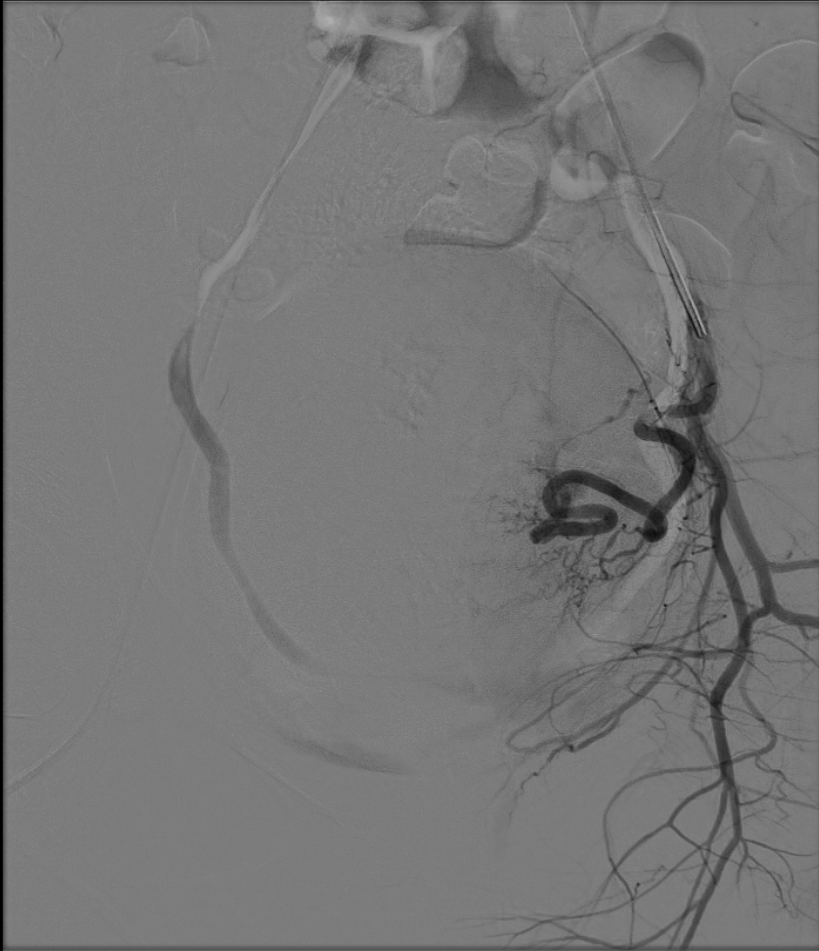- Abnormal early venous drainage is seen bilaterally.



- Abnormal early venous drainage is seen bilaterally.

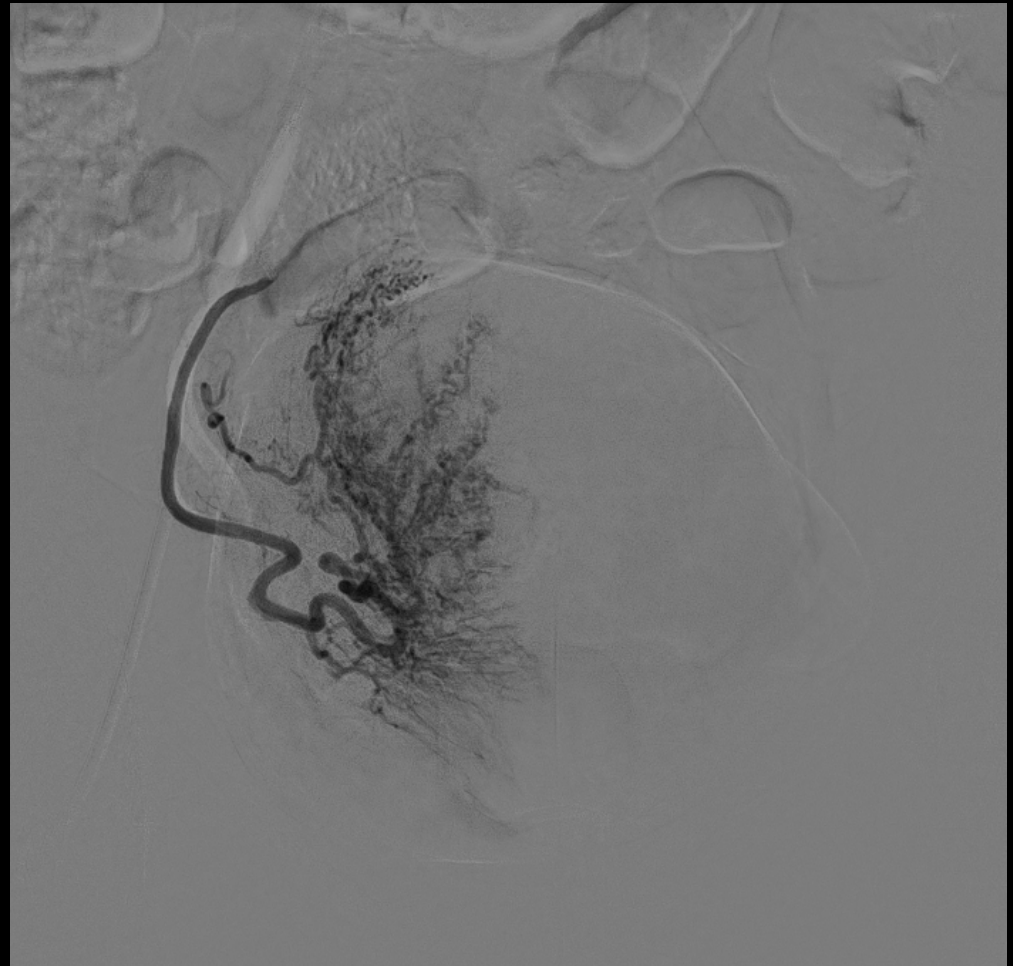


- Embolization to near stasis using 0.6 vial of 500 to 700 um Embospheres.

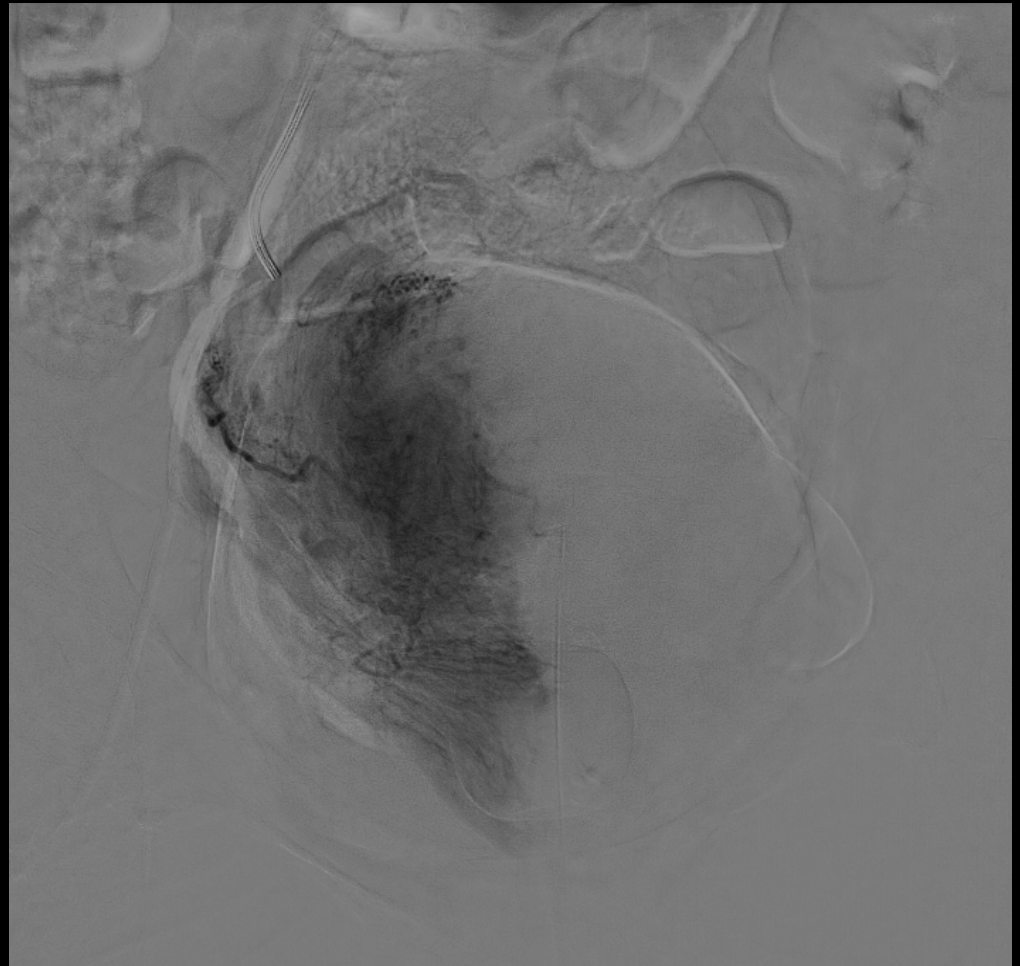


- After embolization, completion angiogram demonstrated absence of abnormal contrast opacification and early venous drainage.
- Preservation of flow via the tubo-ovarian branch was noted.

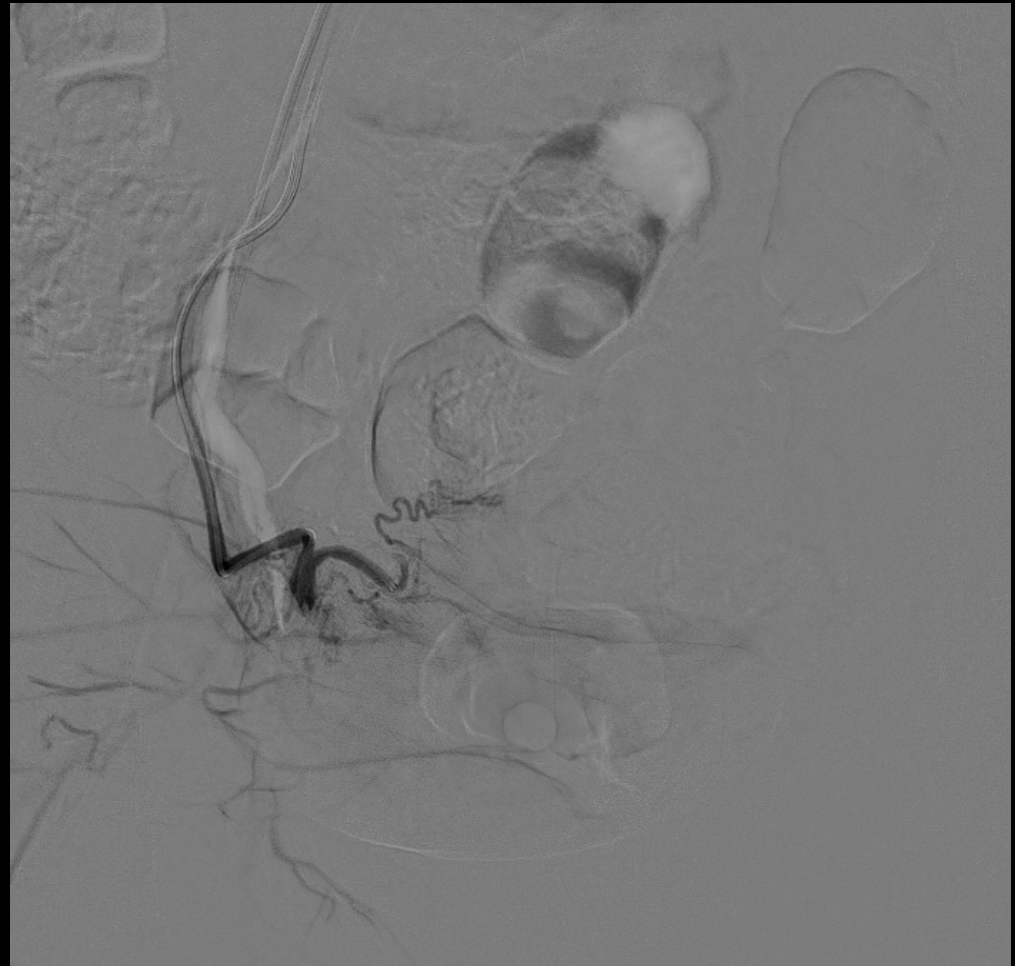
- The distal right uterine artery was accessed with the microcatheter in the same manner.
- Angiogram demonstrated multiple spiral arteries and normal arterial vasculature.



- Normal venous drainage without abnormal contralateral drainage as seen prior to embolization.



- Proceeded with contralateral embolization to diminish the risk of subsequent collateral/contralateral supply formation to the known AVM.
- Embolization to near stasis using 0.3 vial of 500 to 700 um Embospheres.

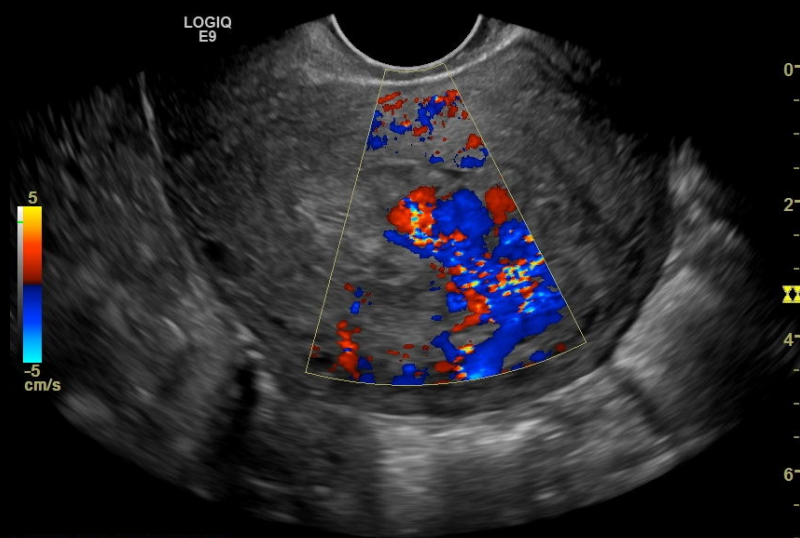


Clinical Course

- No repeat vaginal bleeding presentations since UAE.
- 6 weeks post-embolization follow up US to assess for maintenance of occlusion of the uterine AVM.

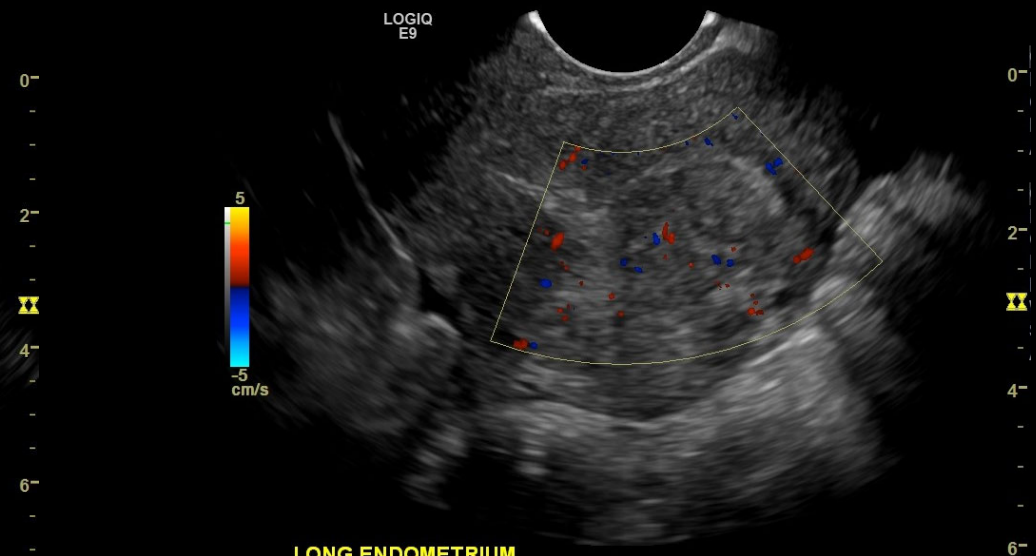
Ultrasound – Reassess AVM 6 weeks post-UAE

- Minimal residual flow is noted post embolization.



LONG UTERUS ENDO

FR9 CHI: Frq8.0 Gn25 D7.0 AO%100 CF: Frq4.2 Gn20.0 L/A:3/7 PRF0.5 WF29 S/P:3/16 AO%100



LONG ENDOMETRIUM

PD 0

- Miscarriage at 20 weeks
- D&C for retained placenta
- Transfused 3 units

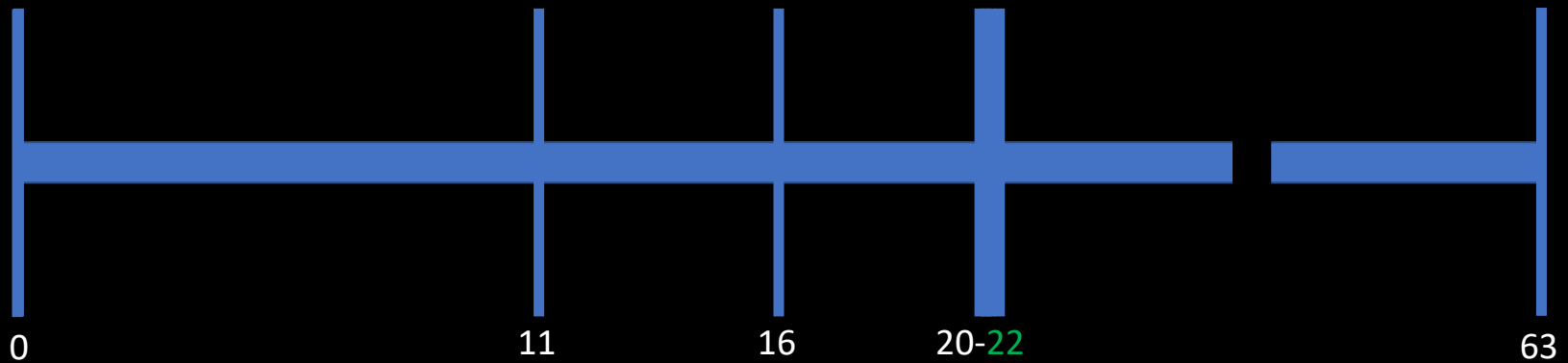
PPD 11

- Presenting with bleeding
- U/S consistent with RPOC
- D&C
- Transfused 2 units

PPD 16

- Presenting with bleeding
- U/S consistent with RPOC or vascular polyp
- D&C
- OBGYN suggests transfer to tertiary center if repeat presentation

PRBC: 5
D&C: 3



PPD 20

- Presenting with bleeding
- Transferred to tertiary center

PPD 21 & 22

- MR demonstrates AVM
- Angio demonstrates AVM and UAE embolization is performed

PPD 63

- US shows minimal residual flow in AVM

Take Aways

Uterine AVM should be considered when patients present with abnormal vaginal bleeding or significant menorrhagia, especially in the context of prior instrumentation or repeat presentations

Doppler flow ultrasonography is recommended for initial evaluation with MR being the modality for diagnostic confirmation

UAE is a safe and effective first line treatment with hysterectomy reserved for when UAE fails or at the preference of the patient

Data concerning fertility is limited: pregnancy is possible with an optimistic study suggesting no impairment

Data concerning pregnancy is limited, there is a possible association with placental abnormalities

References

- Sridhar DI, Vogelzang RL. Diagnosis and treatment of uterine and pelvic arteriovenous malformations. *Endovasc Today*. 2018;17(1):73.
- Yazawa H, Soeda S, Hiraiwa T, Takaiwa M, Hasegawa-Endo S, Kojima M, Fujimori K. Prospective evaluation of the incidence of uterine vascular malformations developing after abortion or delivery. *Journal of Minimally Invasive Gynecology*. 2013 May 1;20(3):360-7.
- Ghai S, Rajan DK, Asch MR, Muradali D, Simons ME, TerBrugge KG. Efficacy of embolization in traumatic uterine vascular malformations. *Journal of vascular and interventional radiology*. 2003 Nov 1;14(11):1401-8.
- Delplanque S, Le Lous M, Proisy M, Joueidi Y, Bauville E, Rozel C, Beraud E, Bruneau B, Levêque J, Lavoué V, Timoh KN. Fertility, pregnancy, and clinical outcomes after uterine arteriovenous malformation management. *Journal of Minimally Invasive Gynecology*. 2019 Jan 1;26(1):153-61.
- Ghanaati H, Firouznia K, Moradi B, Behestani S. Fertility Outcomes After Uterine Artery Embolization for Symptomatic Uterine Arteriovenous Malformations: A Single-Center Retrospective Study in 33 Women. *CardioVascular and Interventional Radiology*. 2022 Mar 16:1-9.
- Mekaru K, Oishi S, Akamine K, Heshiki C, Aoki Y. Spontaneous regression of uterine arteriovenous malformations with conservative management. *Case Reports in Obstetrics and Gynecology*. 2017 Feb 16;2017.
- Badawy SZ, Etman A, Singh M, Murphy K, Mayelli T, Philadelphia M. Uterine artery embolization: the role in obstetrics and gynecology. *Clinical imaging*. 2001 Jul 1;25(4):288-95.
- Maleux G, Timmerman D, Heye S, Wilms G. Acquired uterine vascular malformations: radiological and clinical outcome after transcatheter embolotherapy. *European radiology*. 2006 Feb;16(2):299-306.
- Yoon DJ, Jones M, Al Taani J, Buhimschi C, Dowell JD. A systematic review of acquired uterine arteriovenous malformations: pathophysiology, diagnosis, and transcatheter treatment. *American Journal of Perinatology Reports*. 2016 Mar;6(01):e6-14.
- Wilms GE, Favril A, Baert AL, Poppe W, Van Assche FA. Transcatheter embolization of uterine arteriovenous malformations. *Cardiovascular and interventional radiology*. 1986 Mar;9(2):61-4.
- Kanter G, Packard L, Sit AS. Placenta accreta in a patient with a history of uterine artery embolization for postpartum hemorrhage. *Journal of Perinatology*. 2013 Jun;33(6):482-3.



THANK YOU FOR LISTENING



QUESTIONS?