

# CAIR Case of the Month

---

Case Courtesy of Dr. Hin-Boon Lew  
McGill University



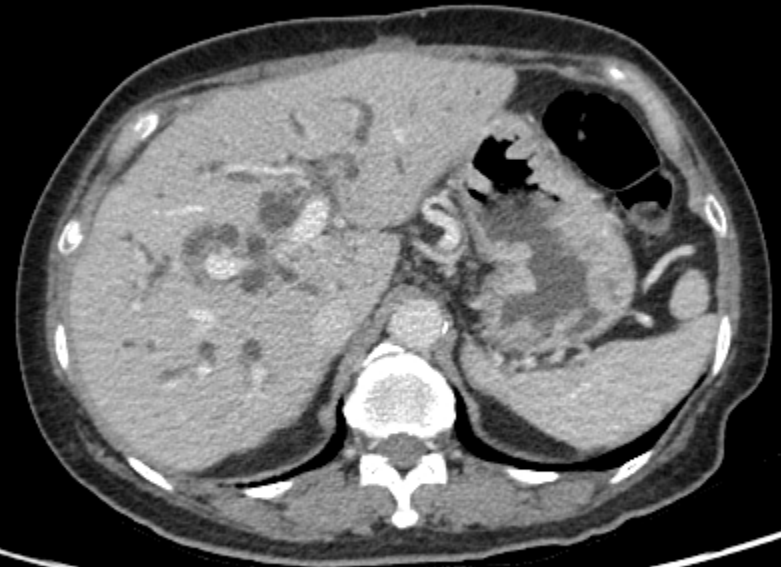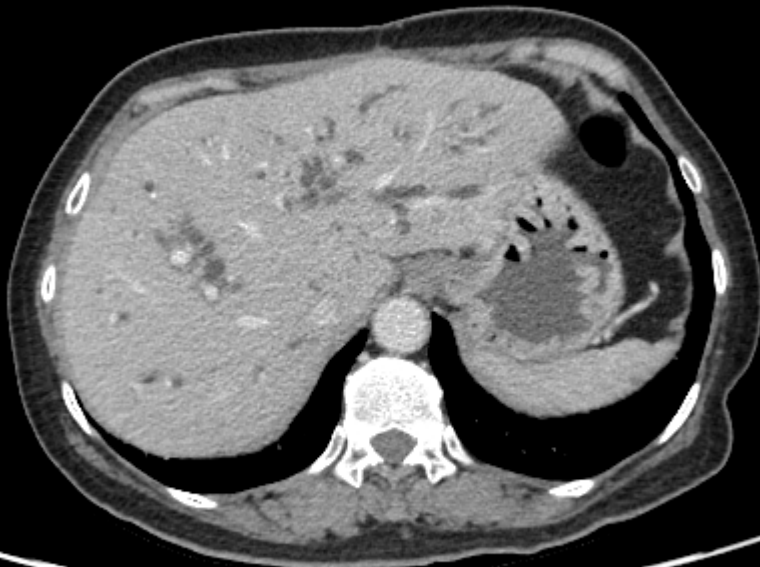# Patient History

---

- 63 year old female
- Gallbladder adenocarcinoma
  - September 2016
    - Cholecystectomy
    - Partial liver and duodenal resection
    - Gastrojejunostomy
- June 2017 – rising bilirubin to 122  $\mu\text{mol/l}$ 
  - CT showed hilar biliary obstruction from recurrent tumor

# CT Abdomen 27<sup>th</sup> June 2017

---



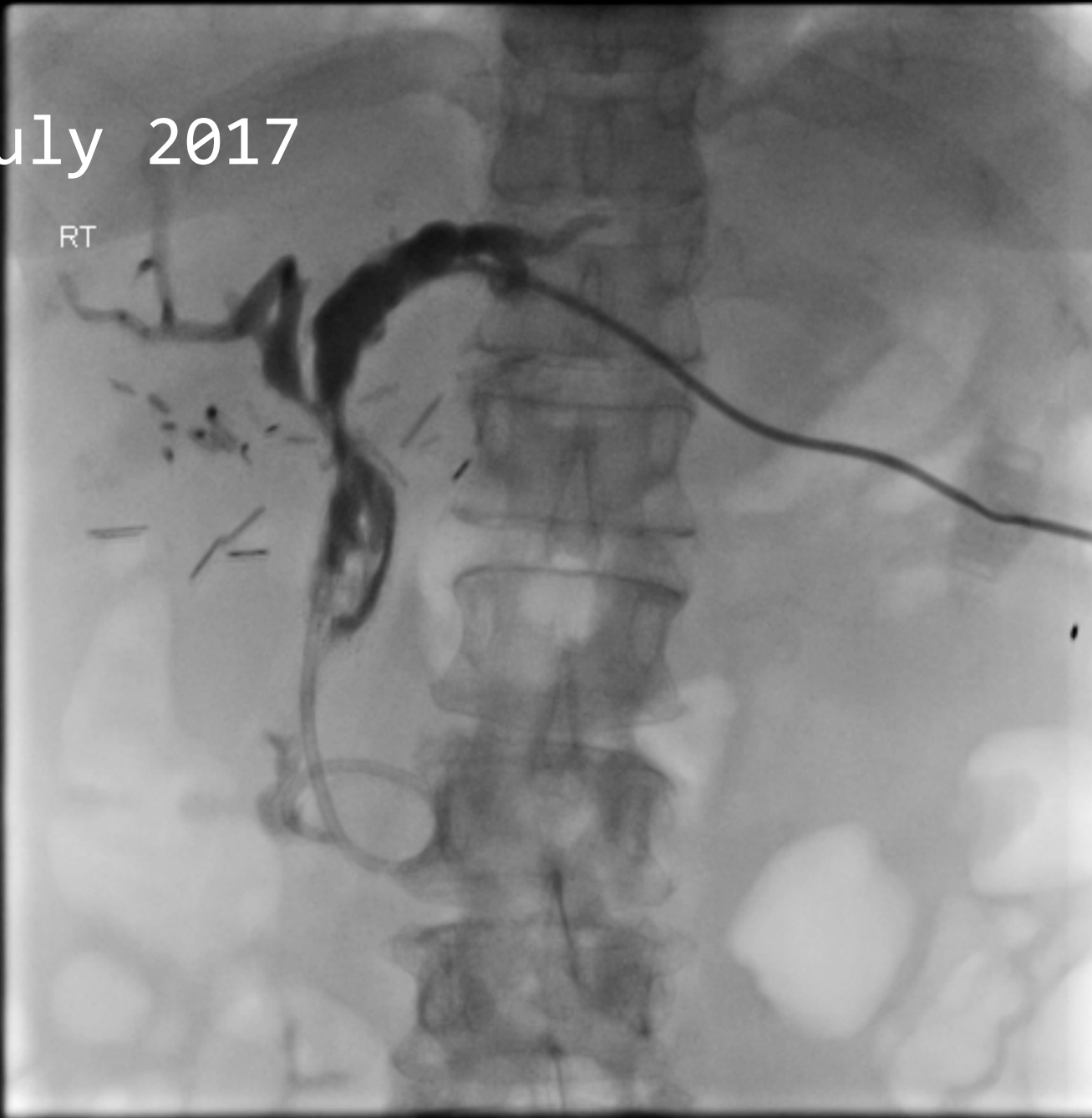# July 2017

---

- Initially left-sided biliary drain inserted but this did not result in drainage of the right side and a right-sided biliary drain was subsequently inserted
- Eventually parallel CBD stents (9 mm) placed

July 2017

RT



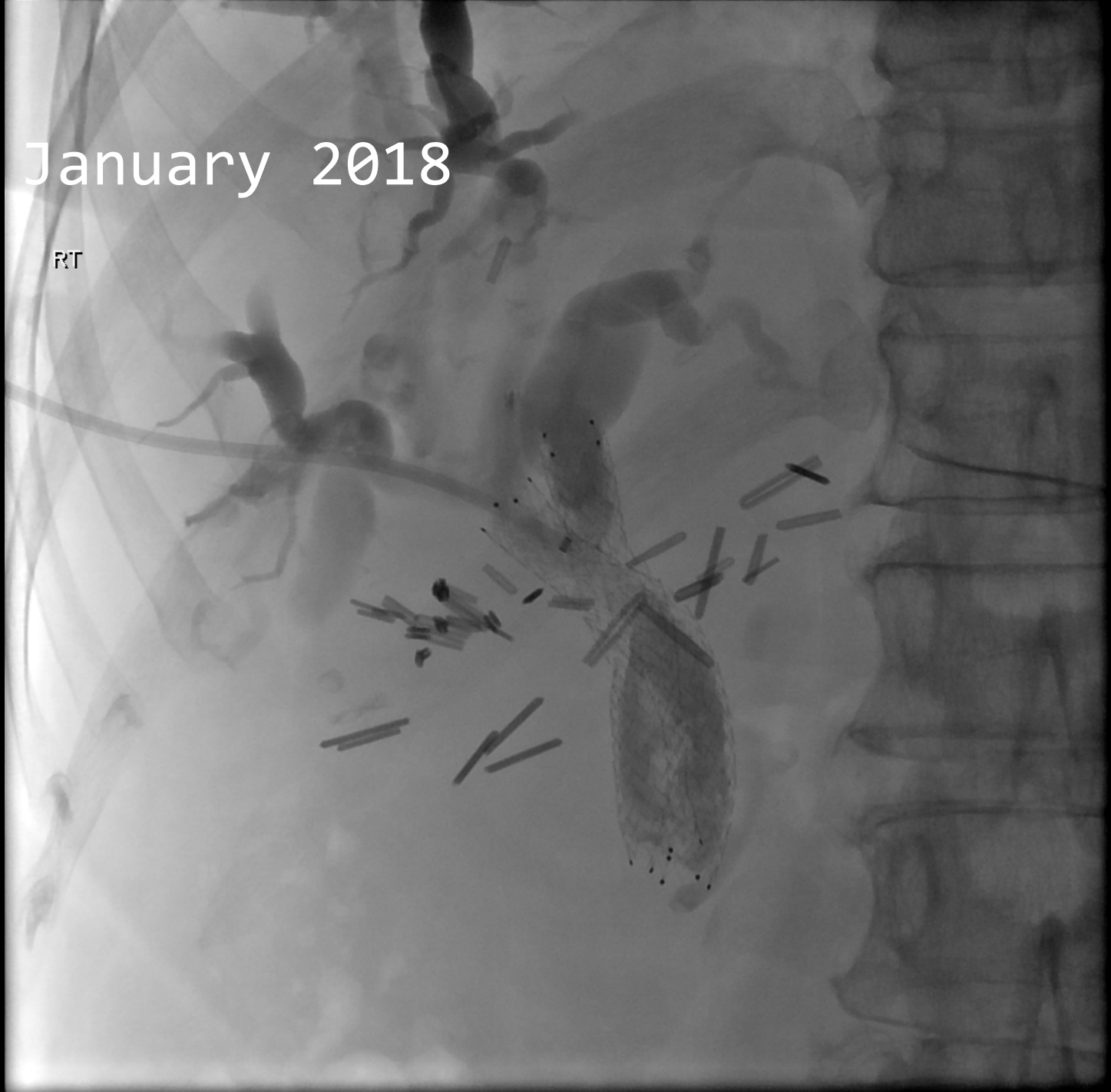# January 2018

---

- Ongoing episodes of cholangitis prompting hospital admissions and preventing chemotherapy
- New right-sided internal/external biliary drain placed
  - Cholangiogram showed obstructed biliary stents

January 2018

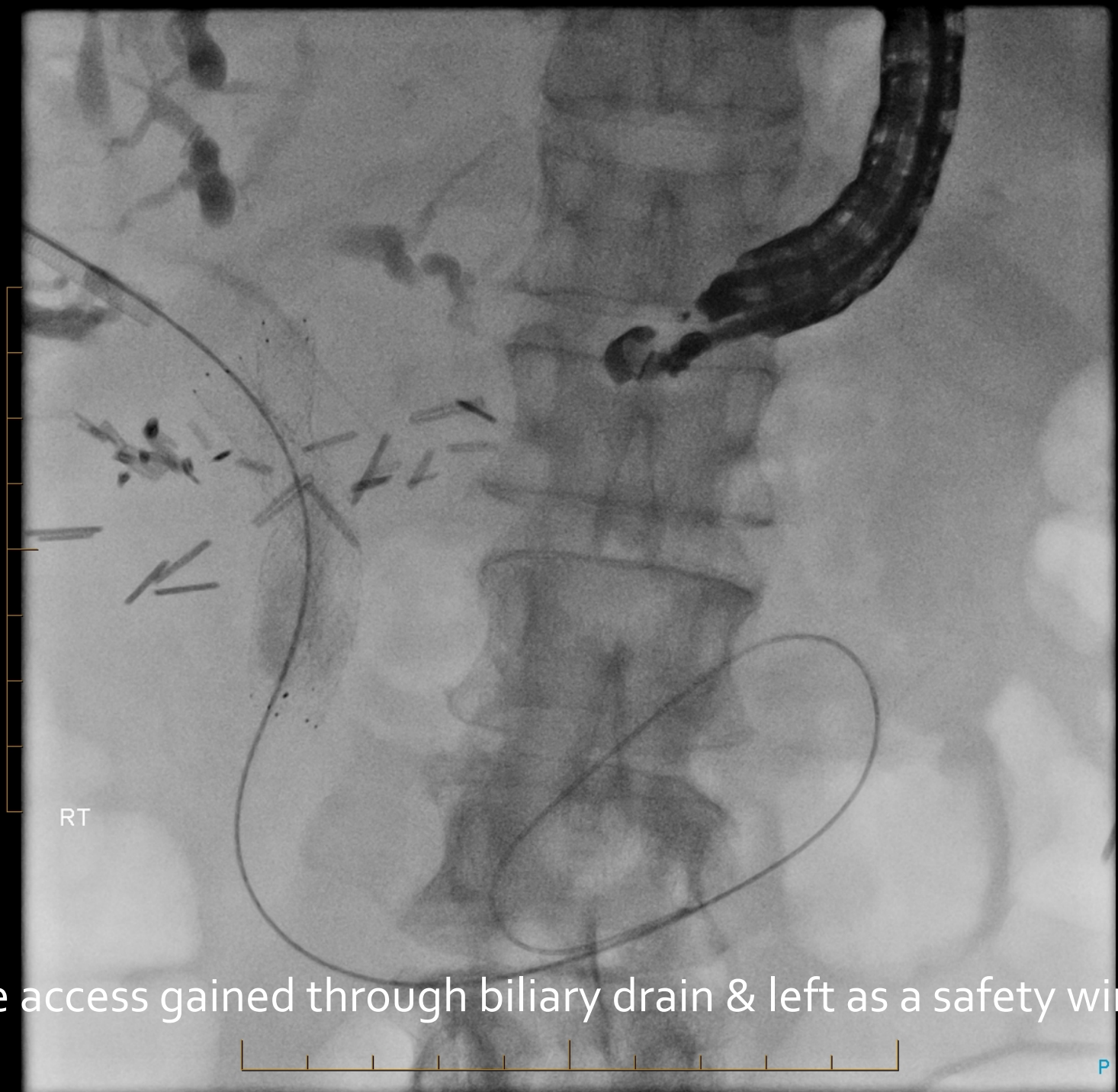RT



# Hepaticogastrostomy formation

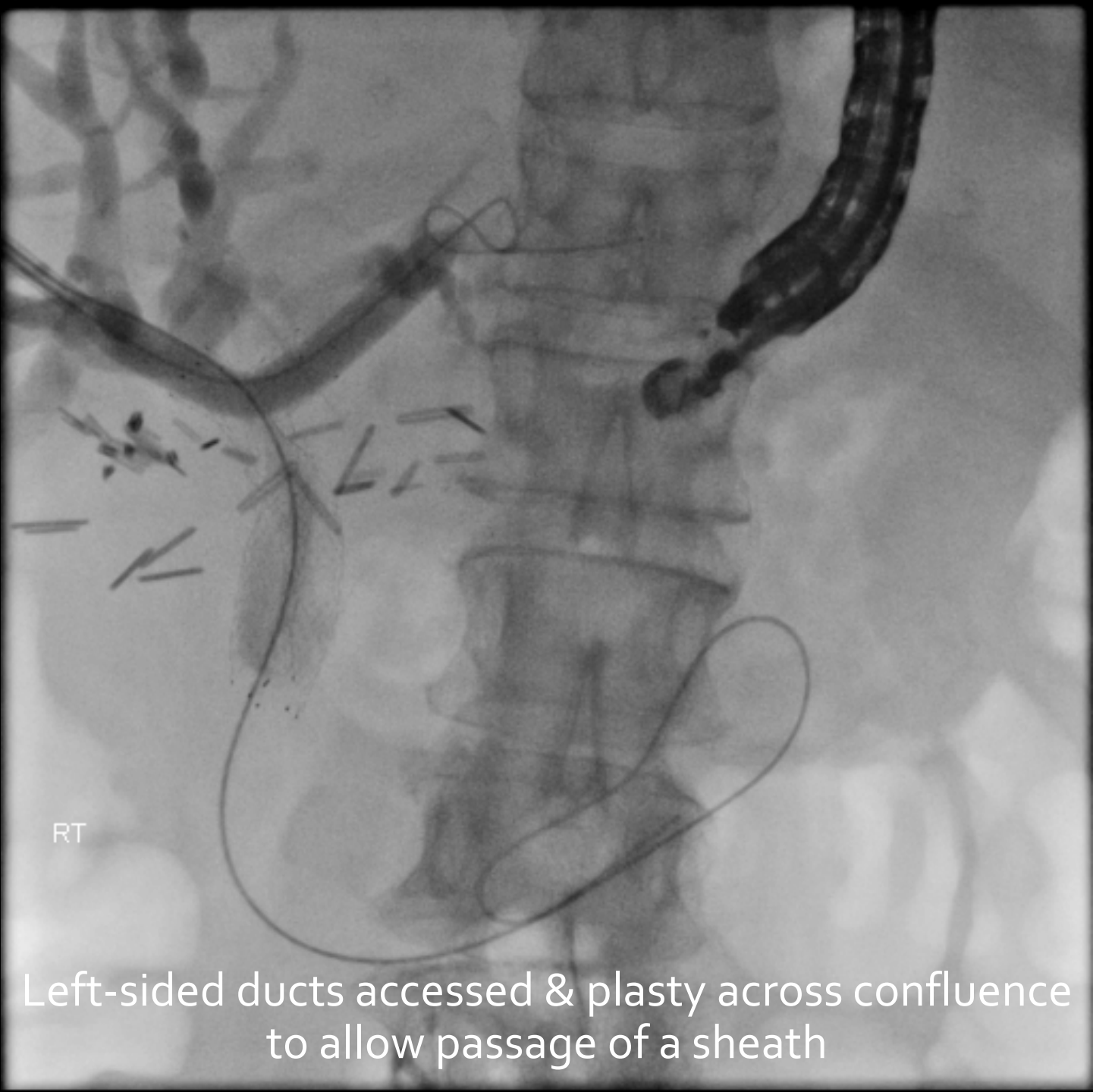
---

- To bypass central mass as CBD stents likely to block again with debris and expanding mass
- Biliary drainage directly to stomach
- Joint procedure with Gastroenterologist  
Endoscopist



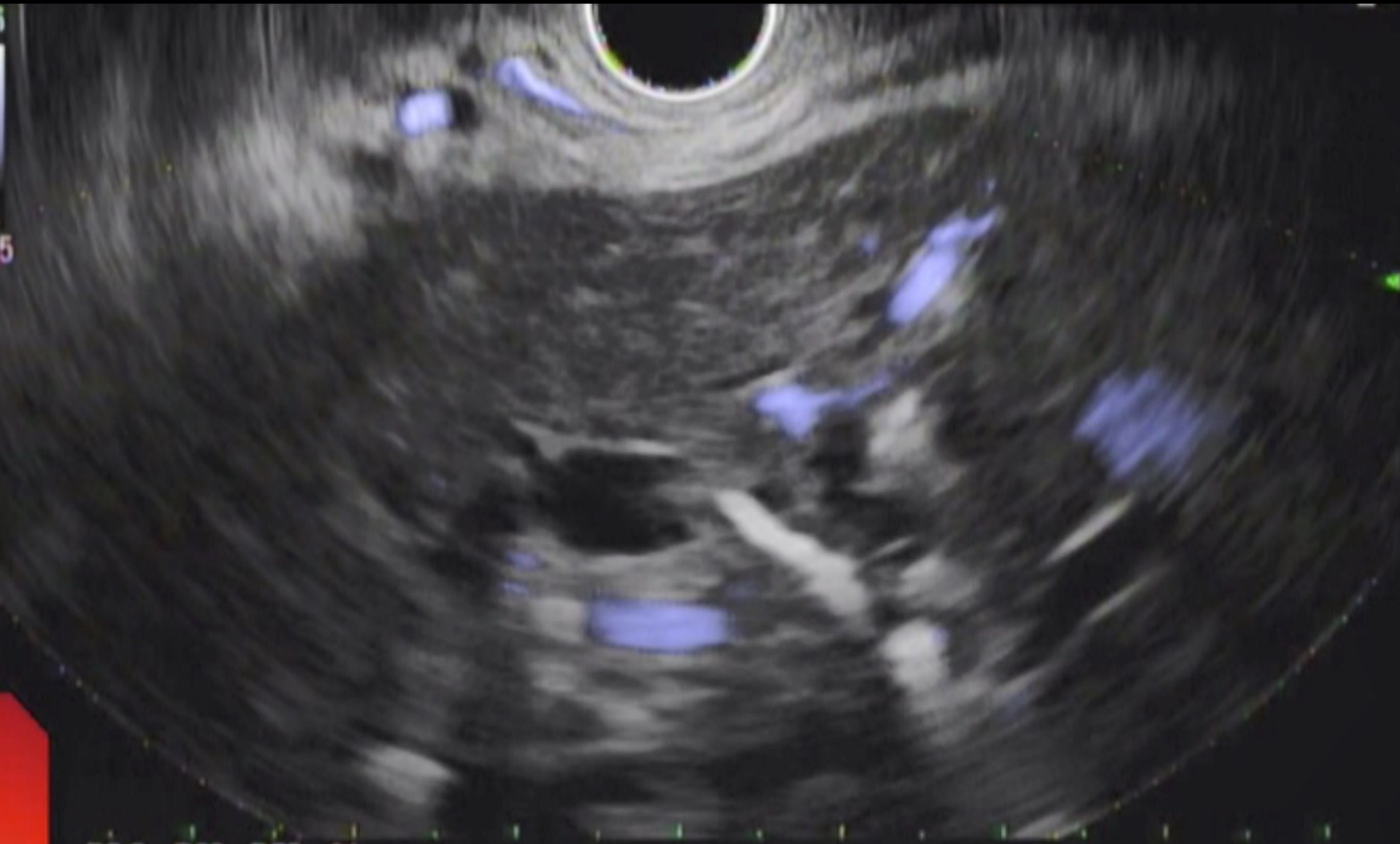
RT

Wire access gained through biliary drain & left as a safety wire

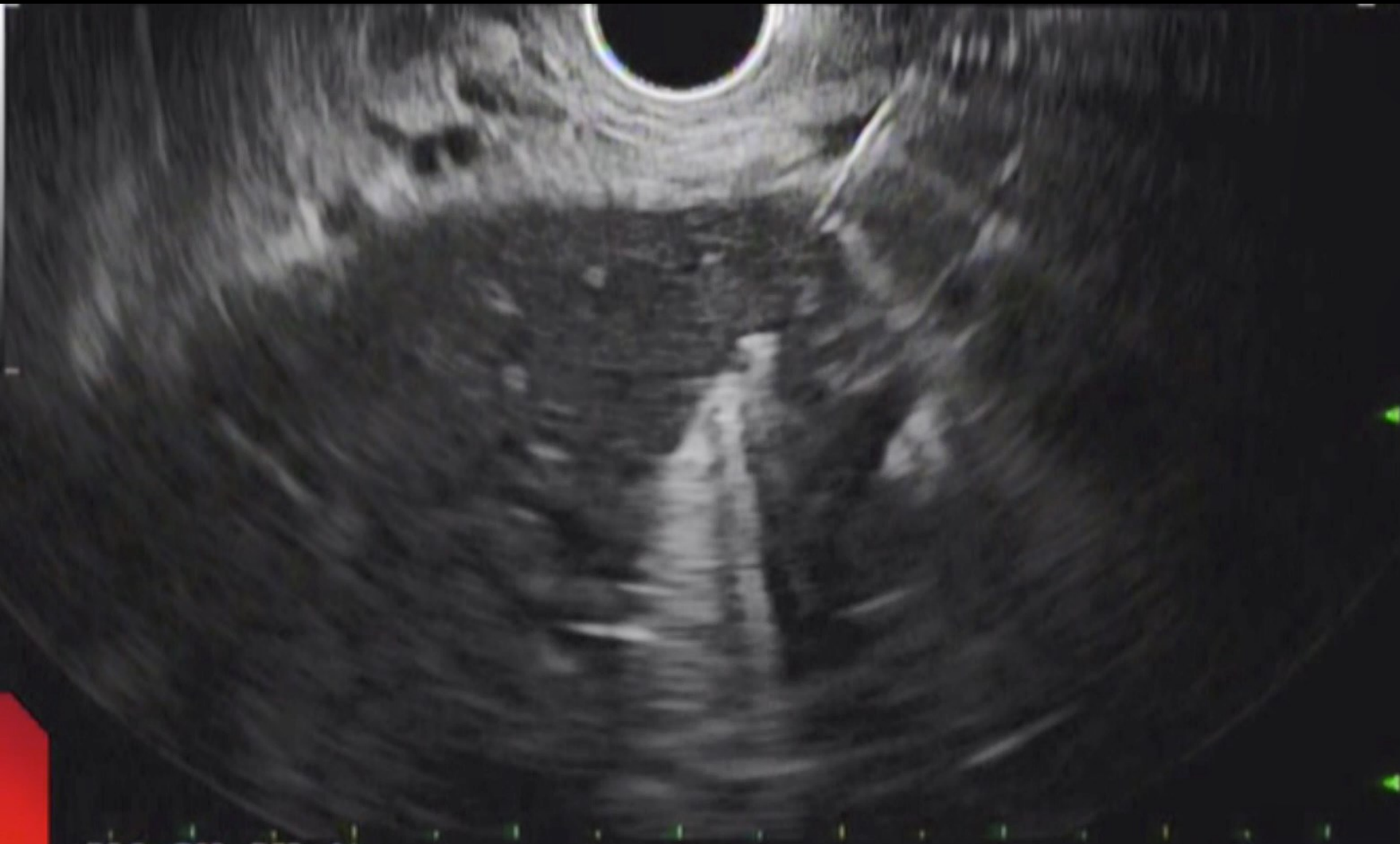


RT

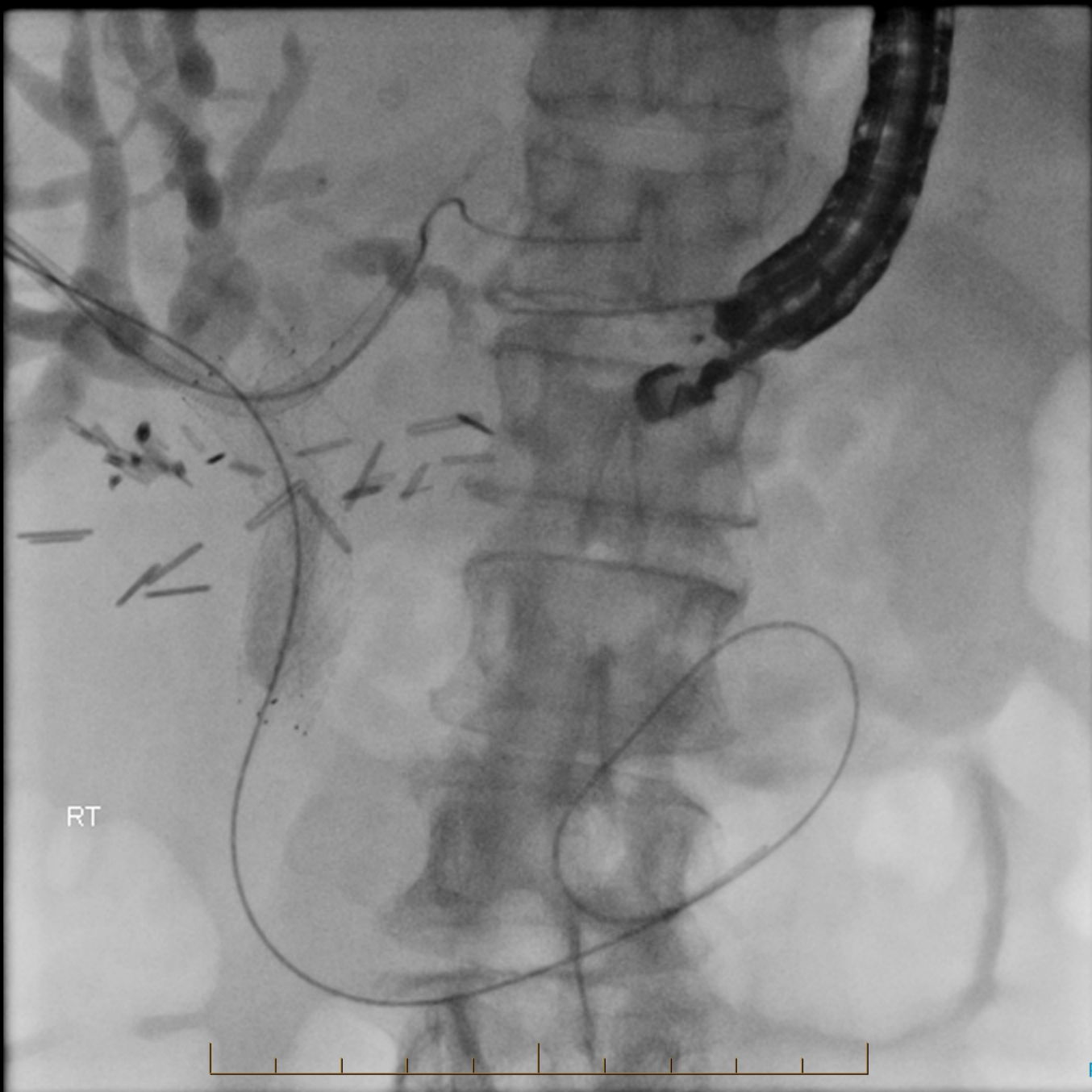
Left-sided ducts accessed & plasty across confluence to allow passage of a sheath



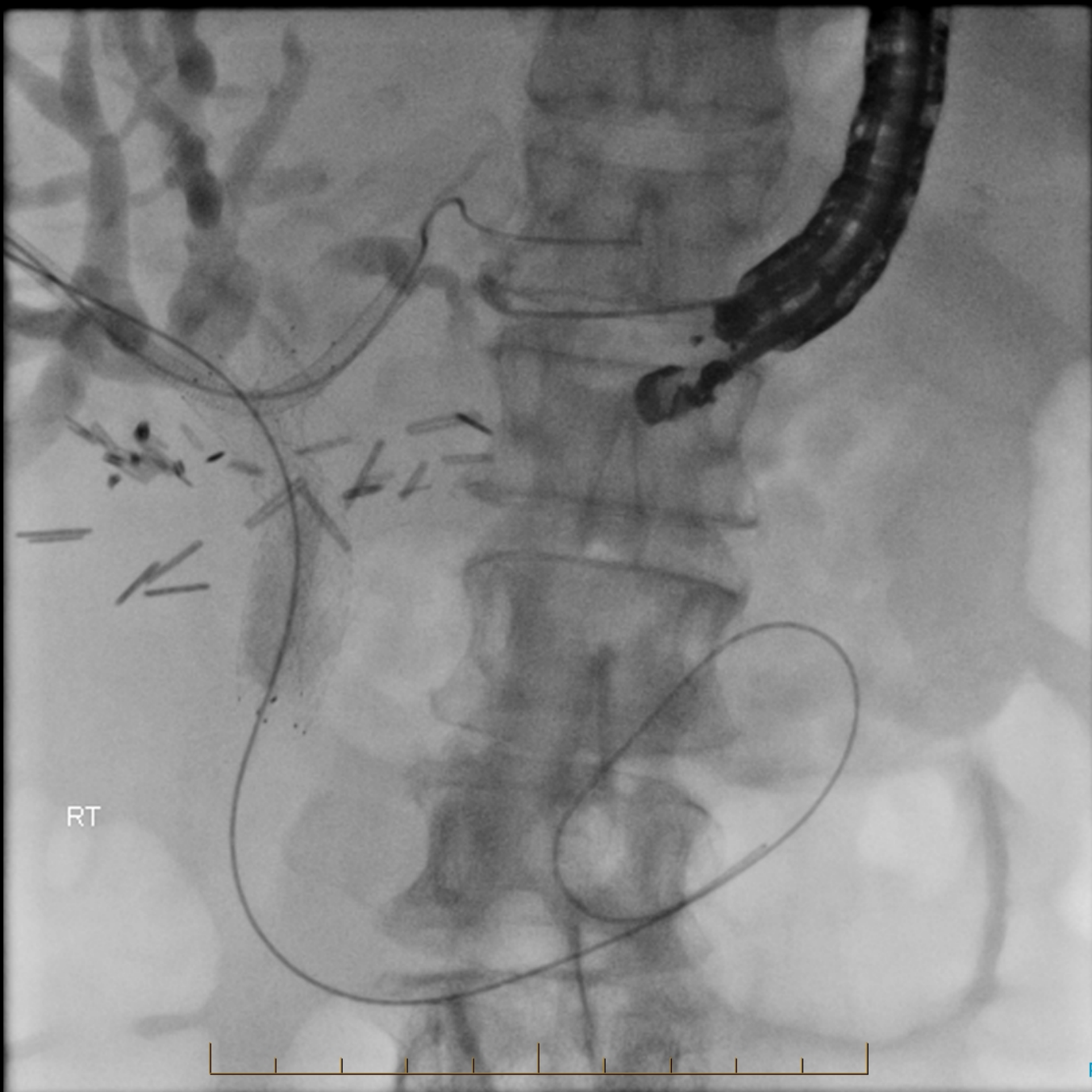
Endoscopic ultrasound image of dilated left side biliary ducts



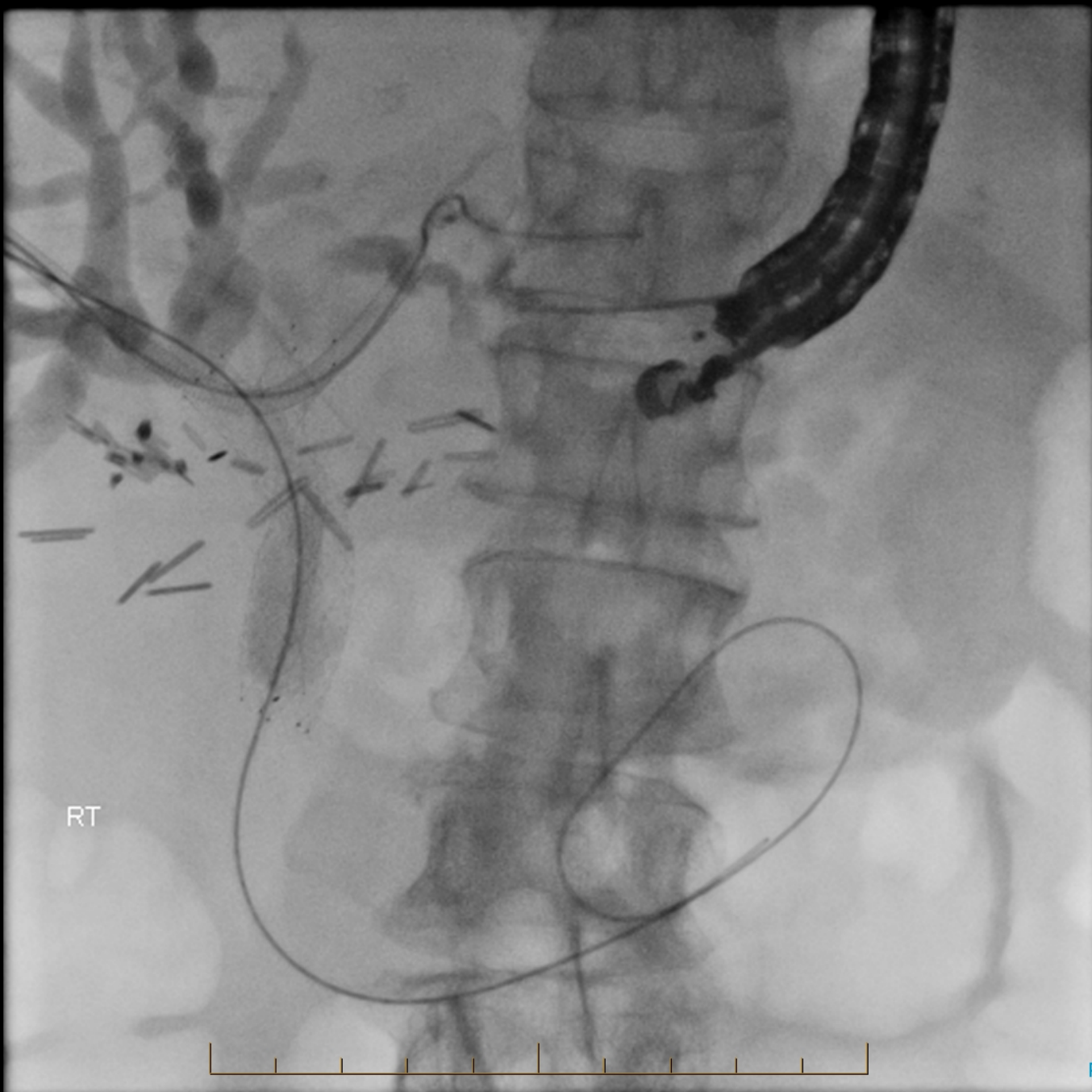
Endoscopic ultrasound image of puncture of biliary duct



Puncture position confirmed with contrast injection

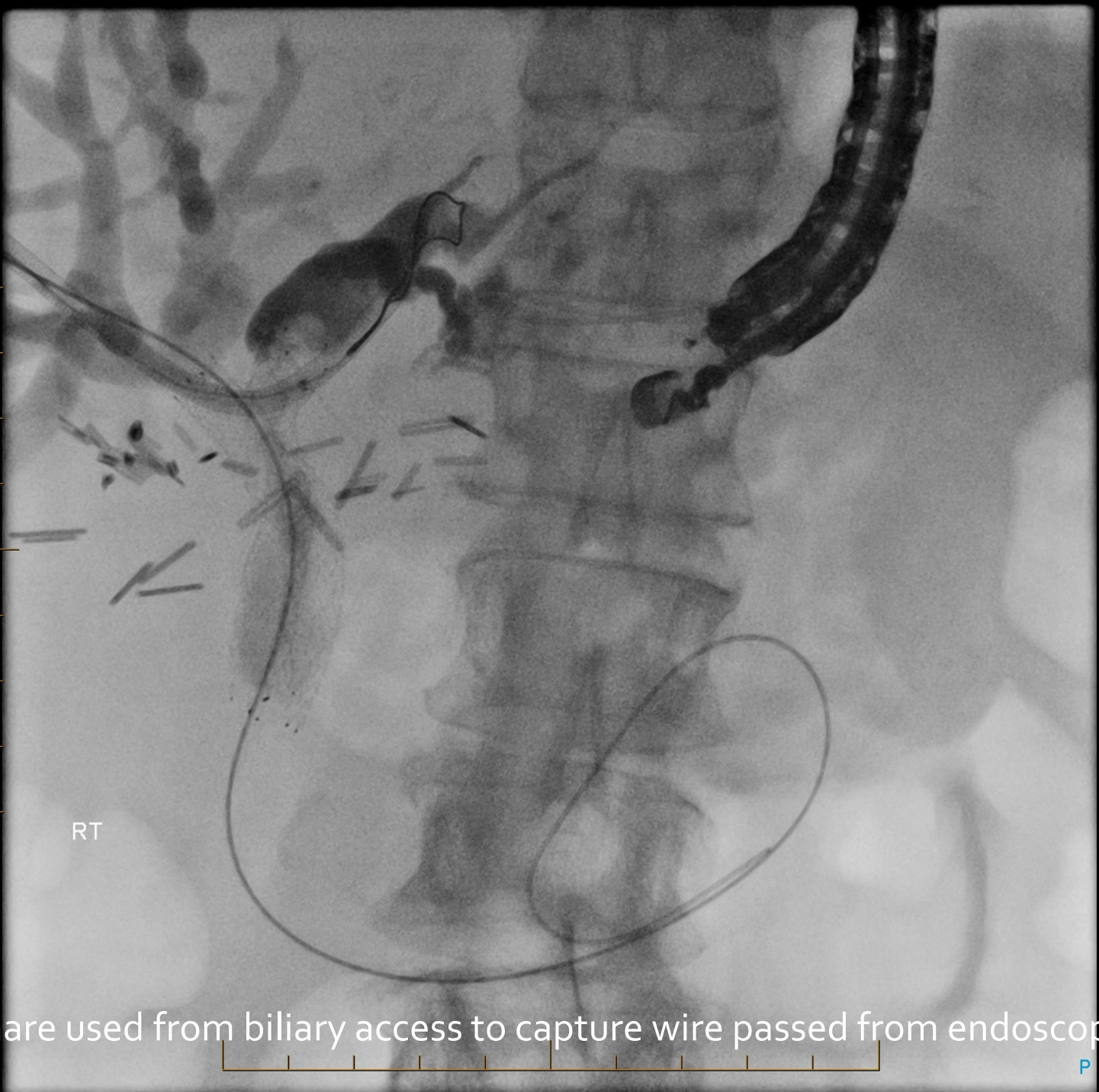

RT



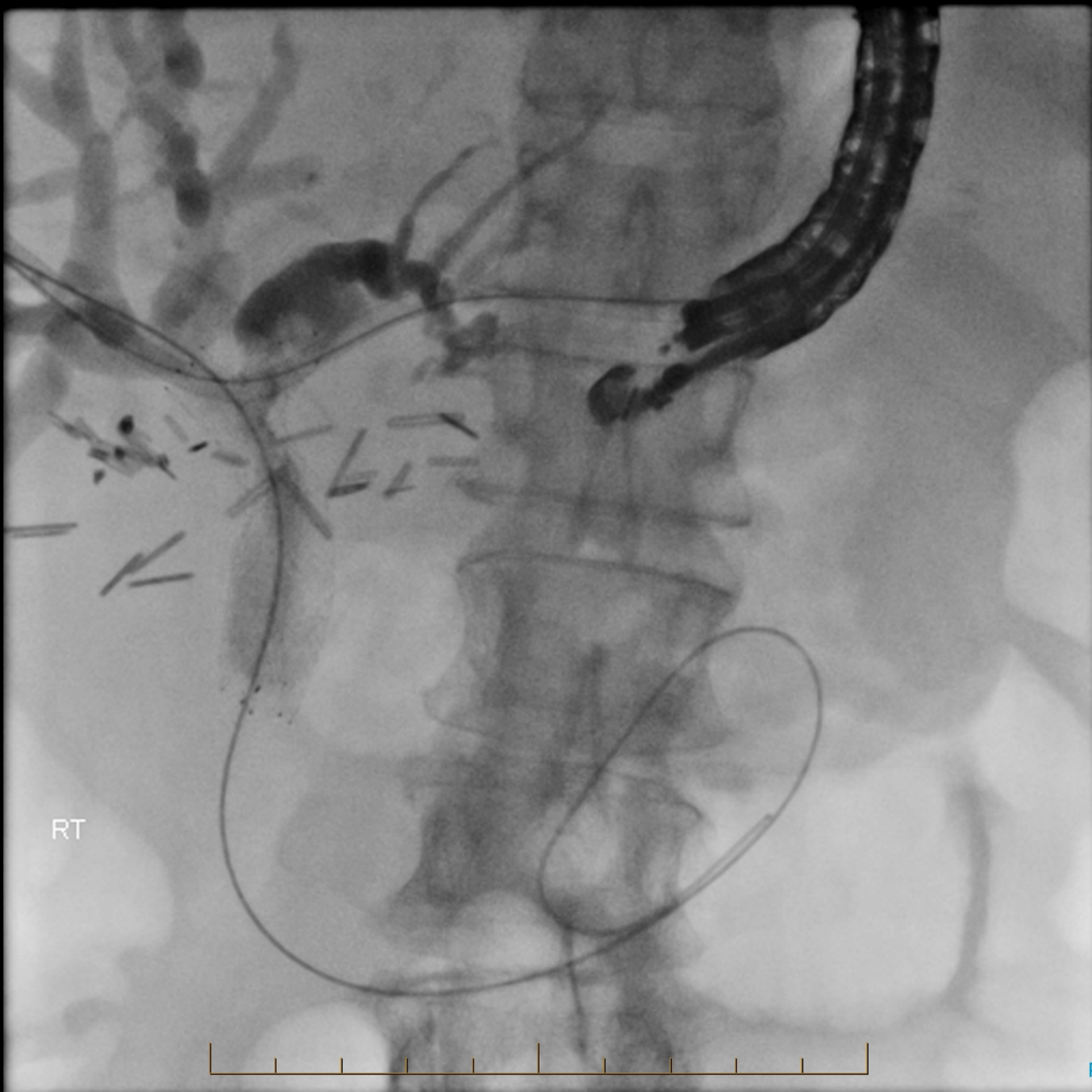
RT



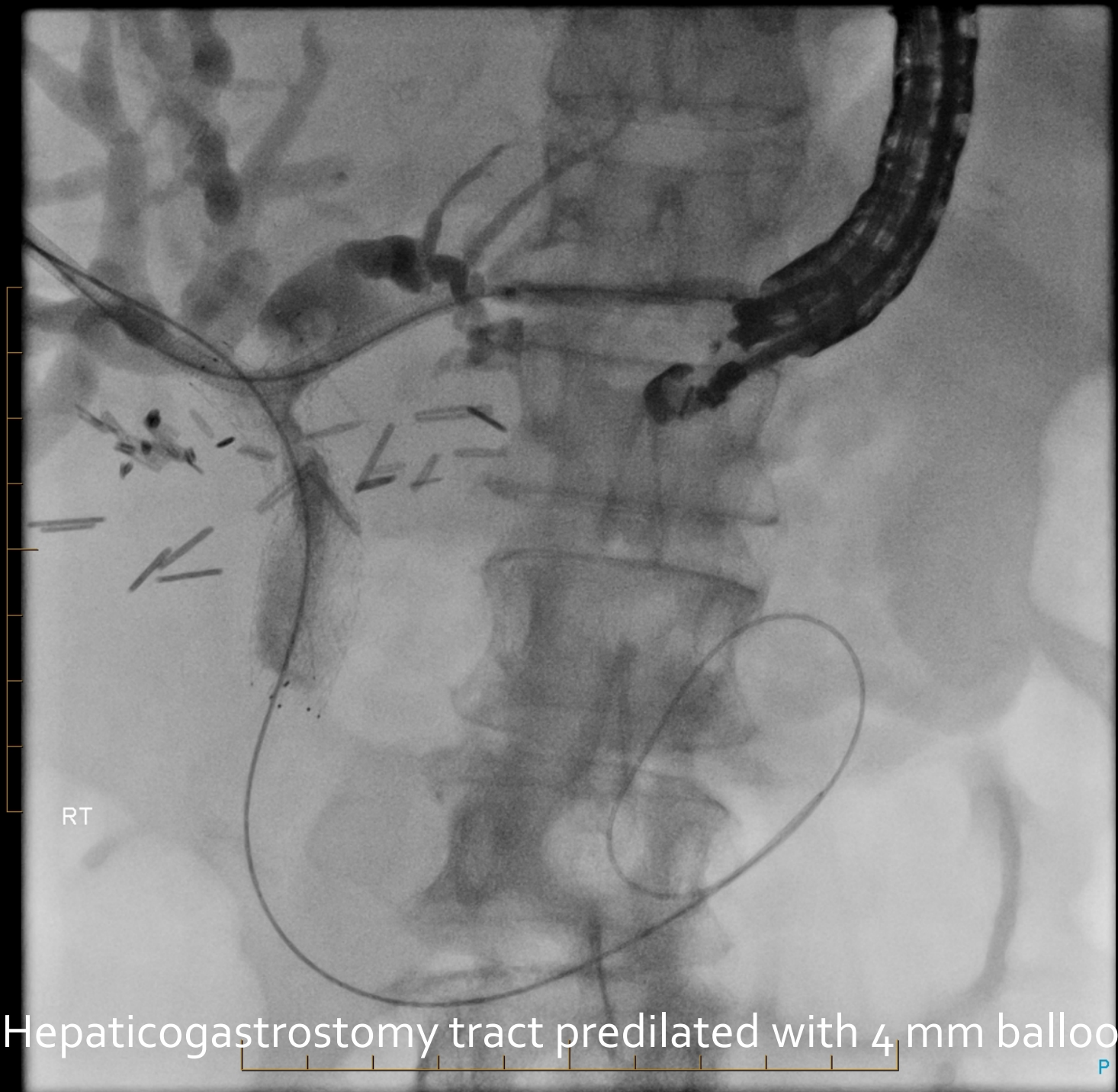


RT

Snare used from biliary access to capture wire passed from endoscope

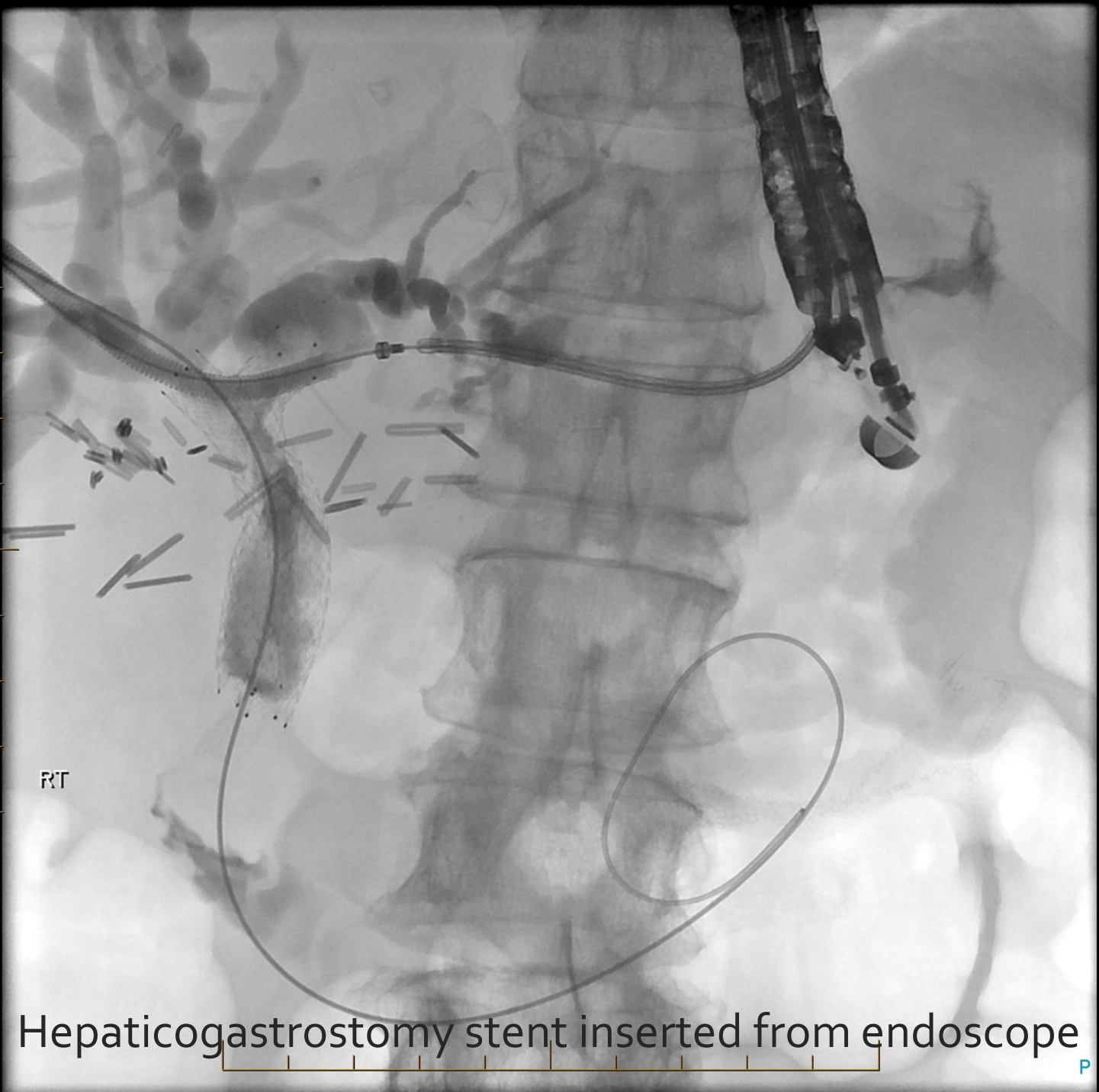

Resulting in through and through access from liver to mouth

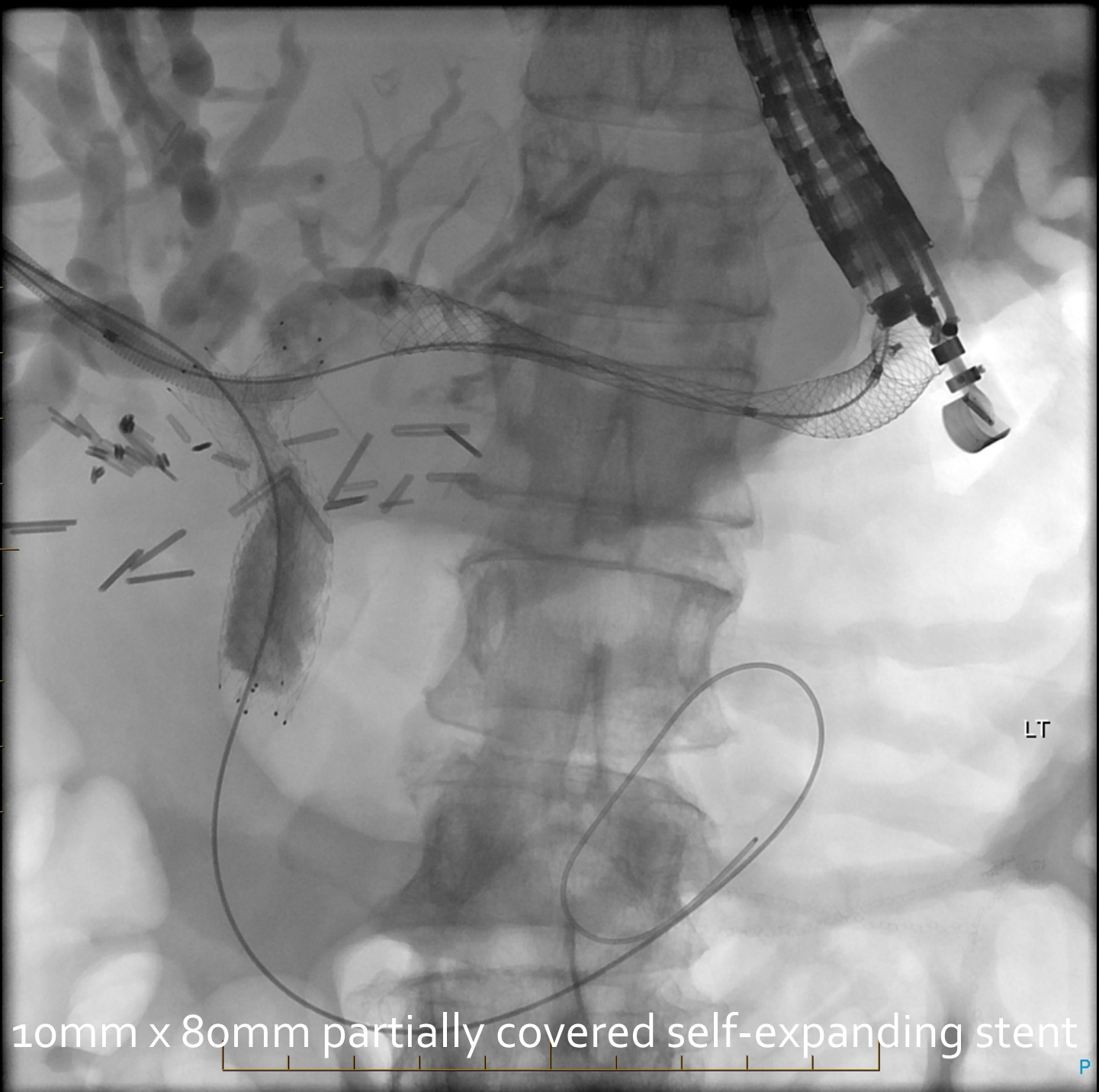

RT

Hepaticogastrostomy tract predilated with 4 mm balloon



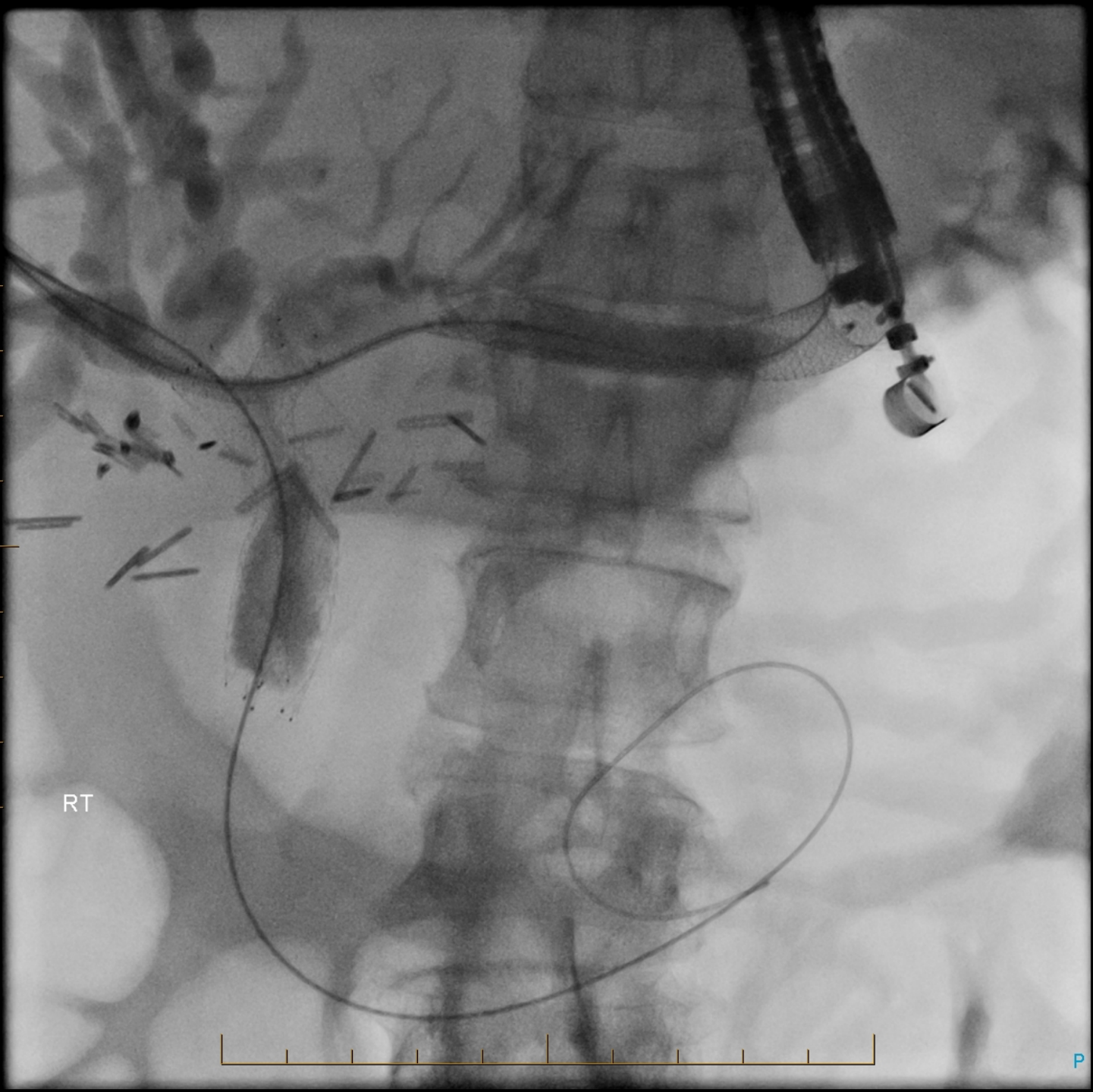
Hepaticogastrostomy stent inserted from endoscope



10mm x 80mm partially covered self-expanding stent

LT

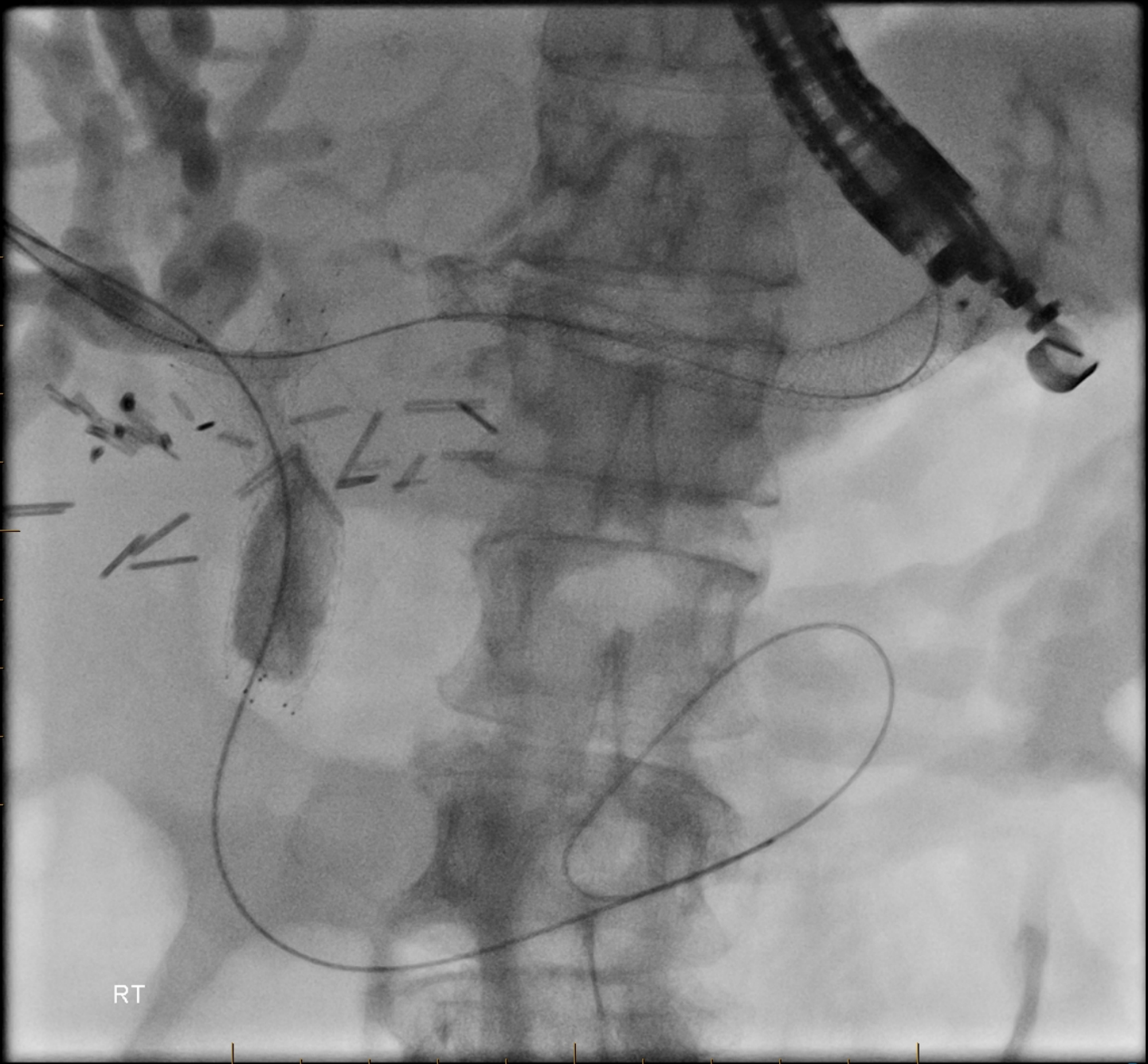





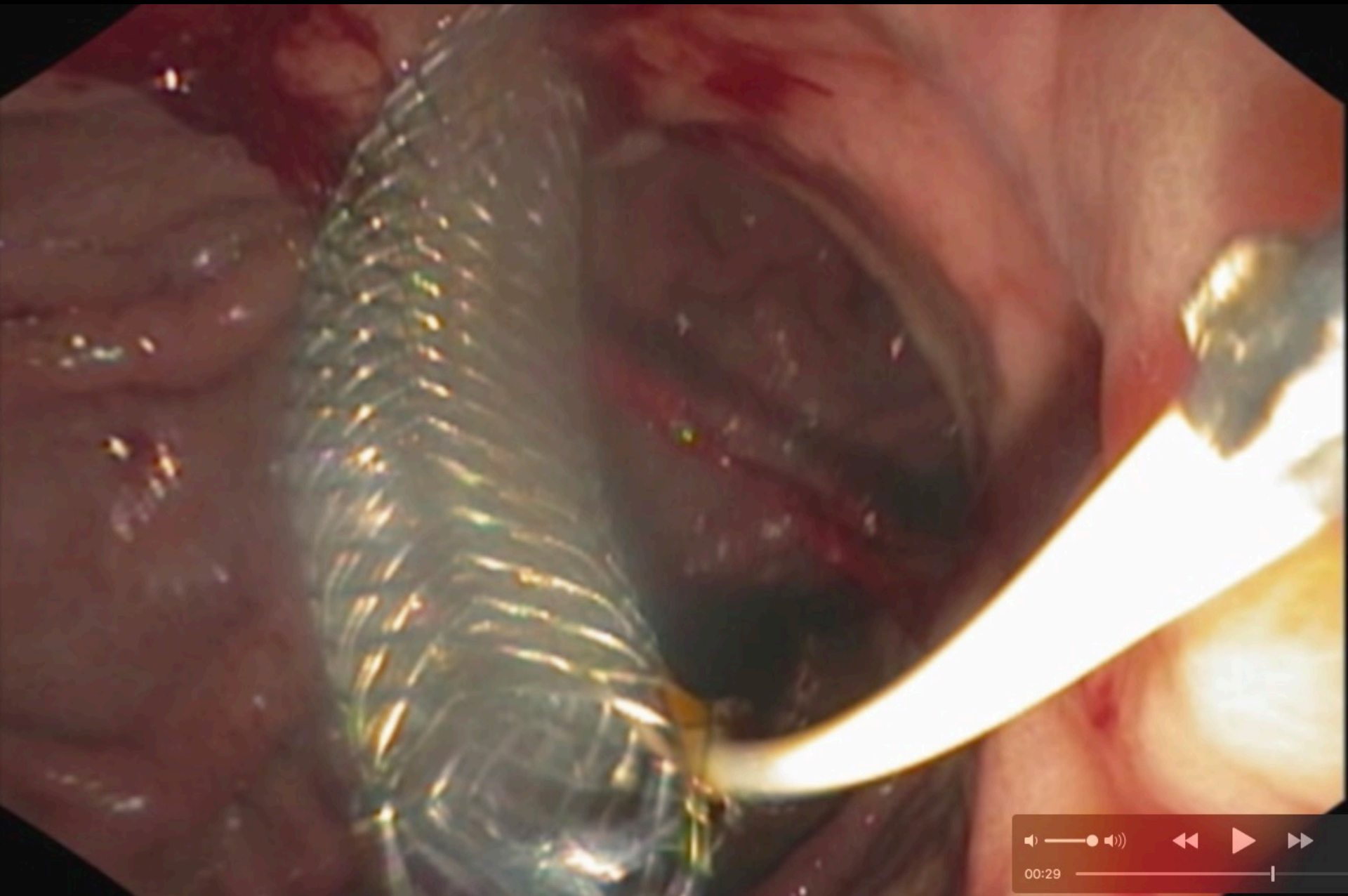
RT

P

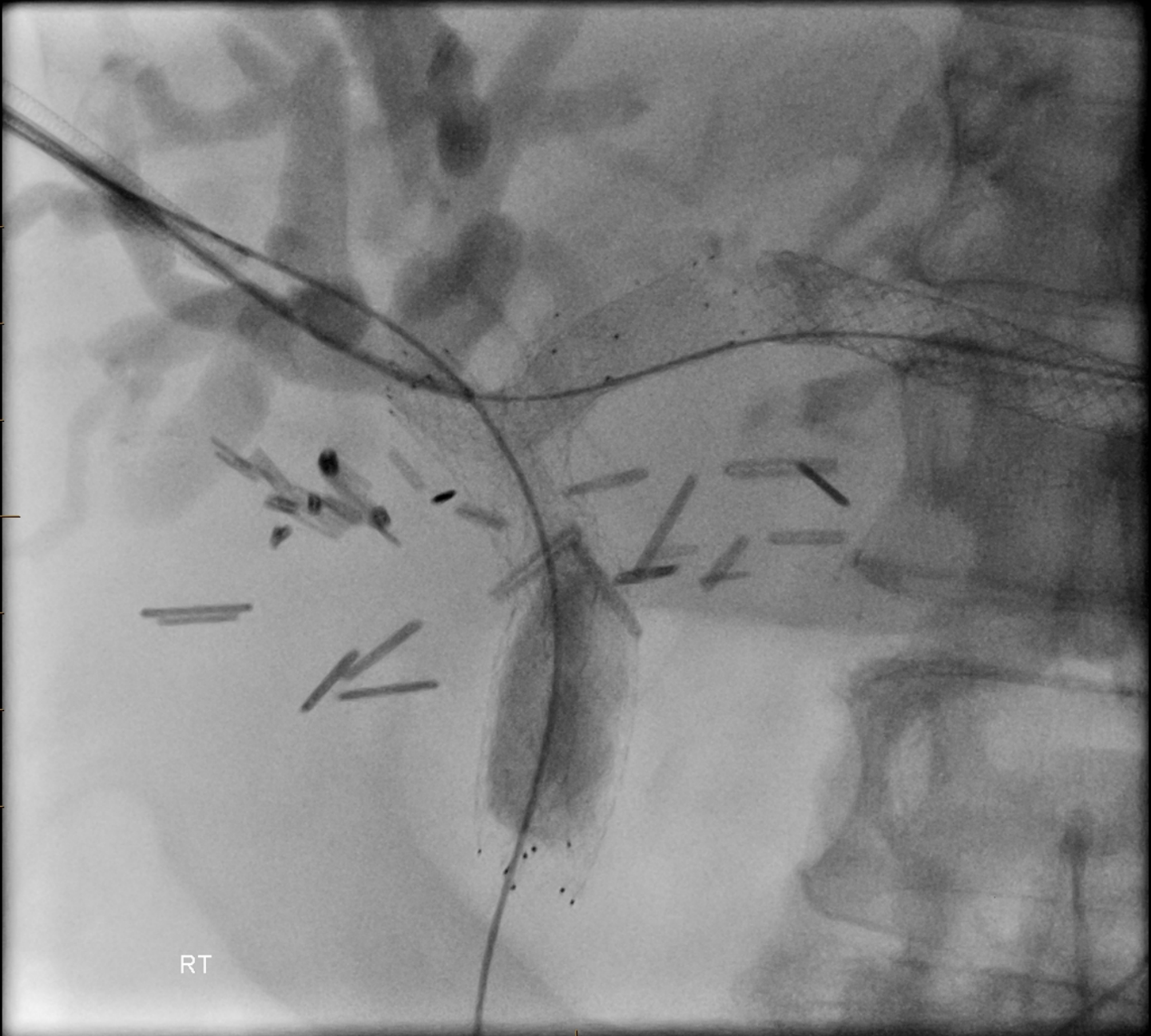



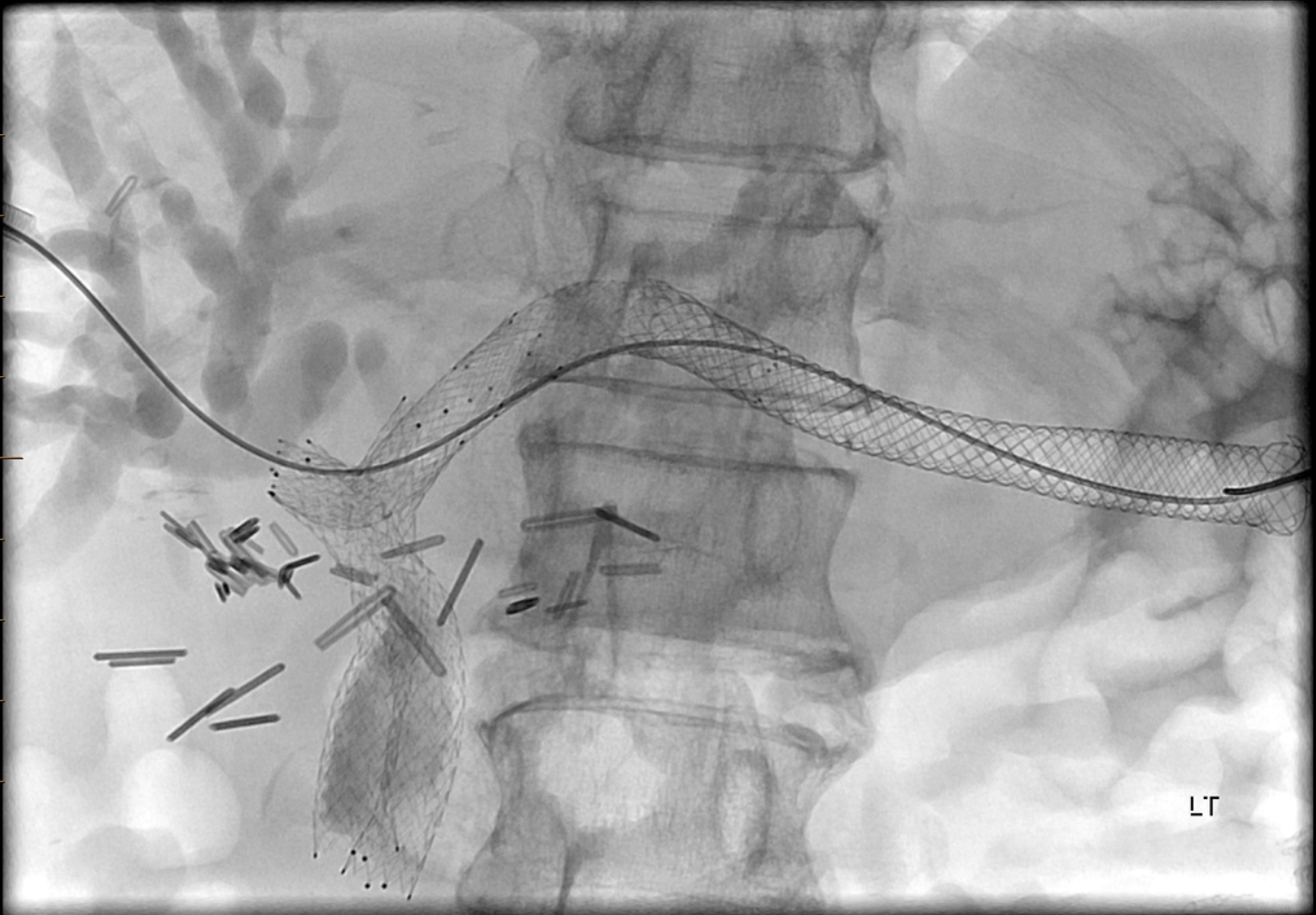
RT



Endscope image of the stent in the stomach

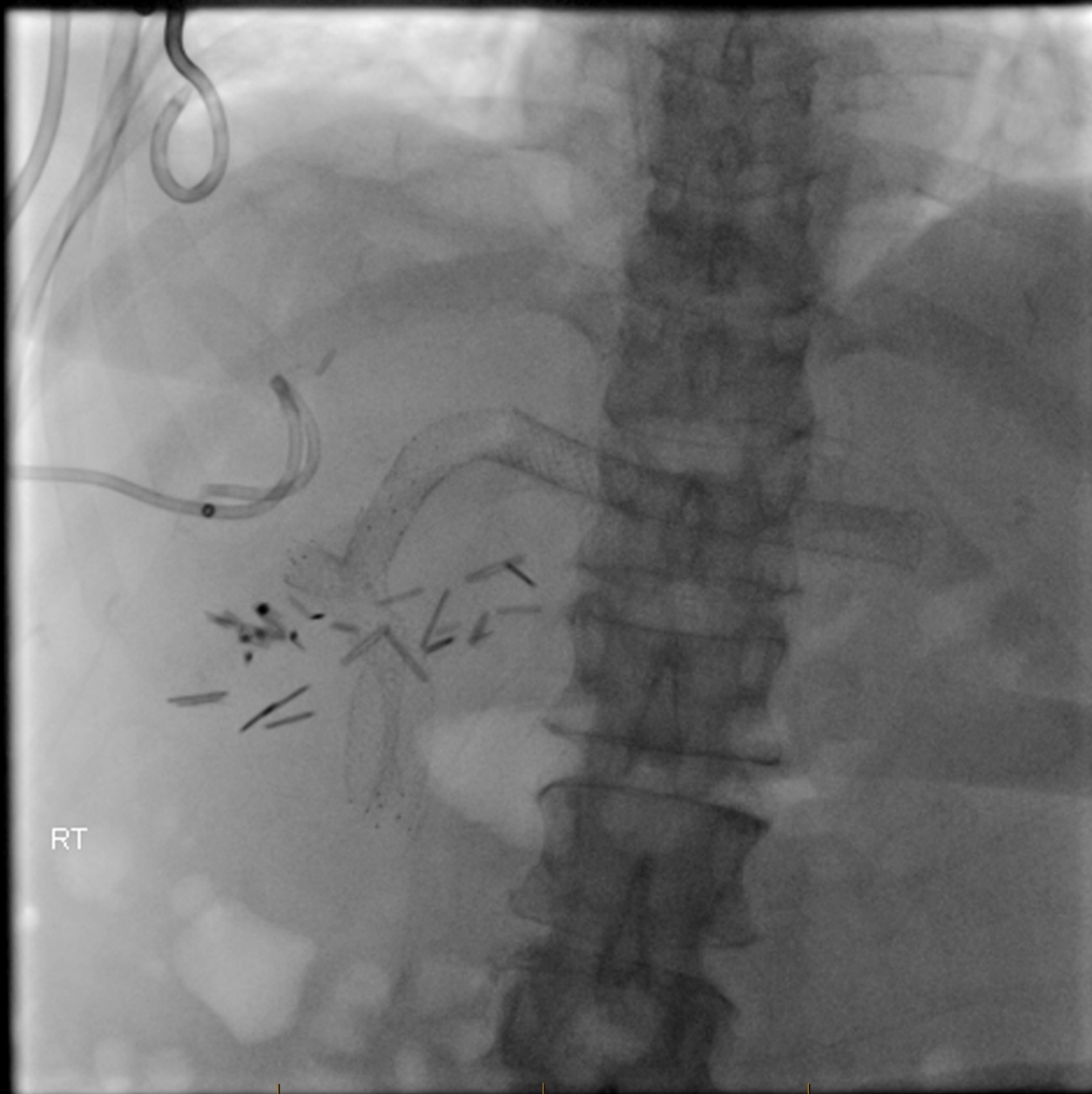


8 mm stent placed across biliary bifurcation to join left & right sides



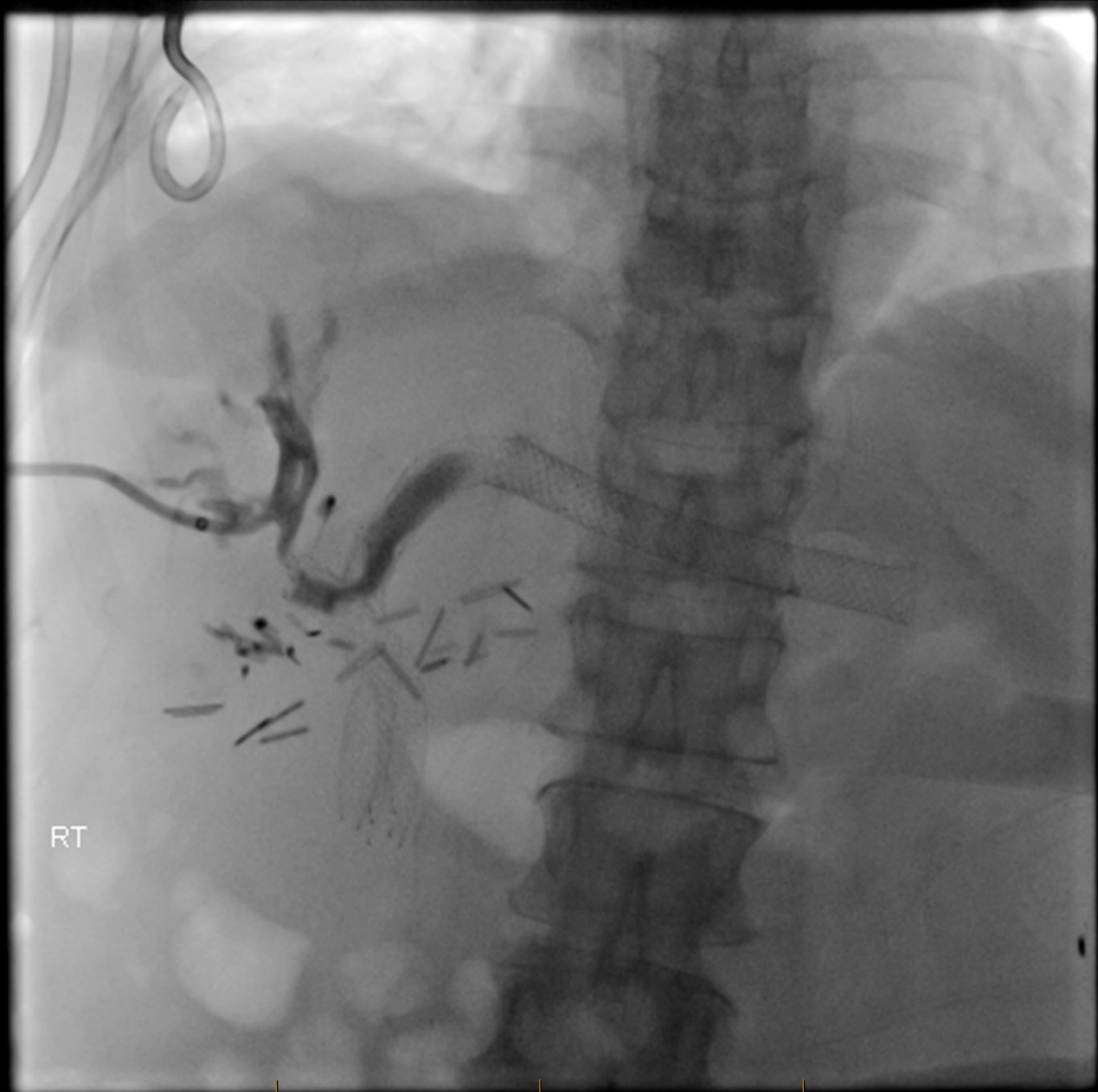
Another stent placed from left biliary duct to hepaticogastrostomy





RT

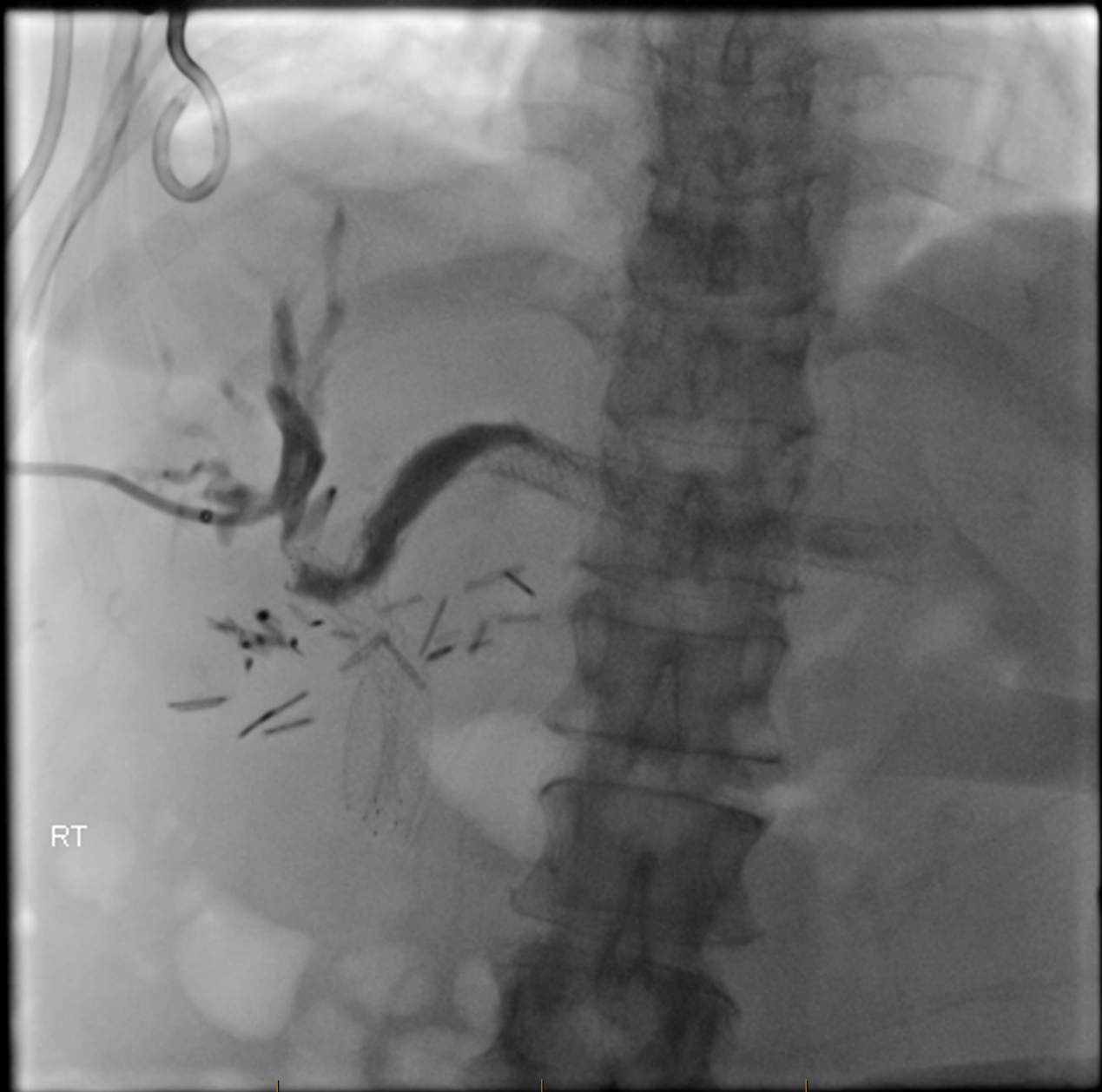Cholangiogram - 1 week later



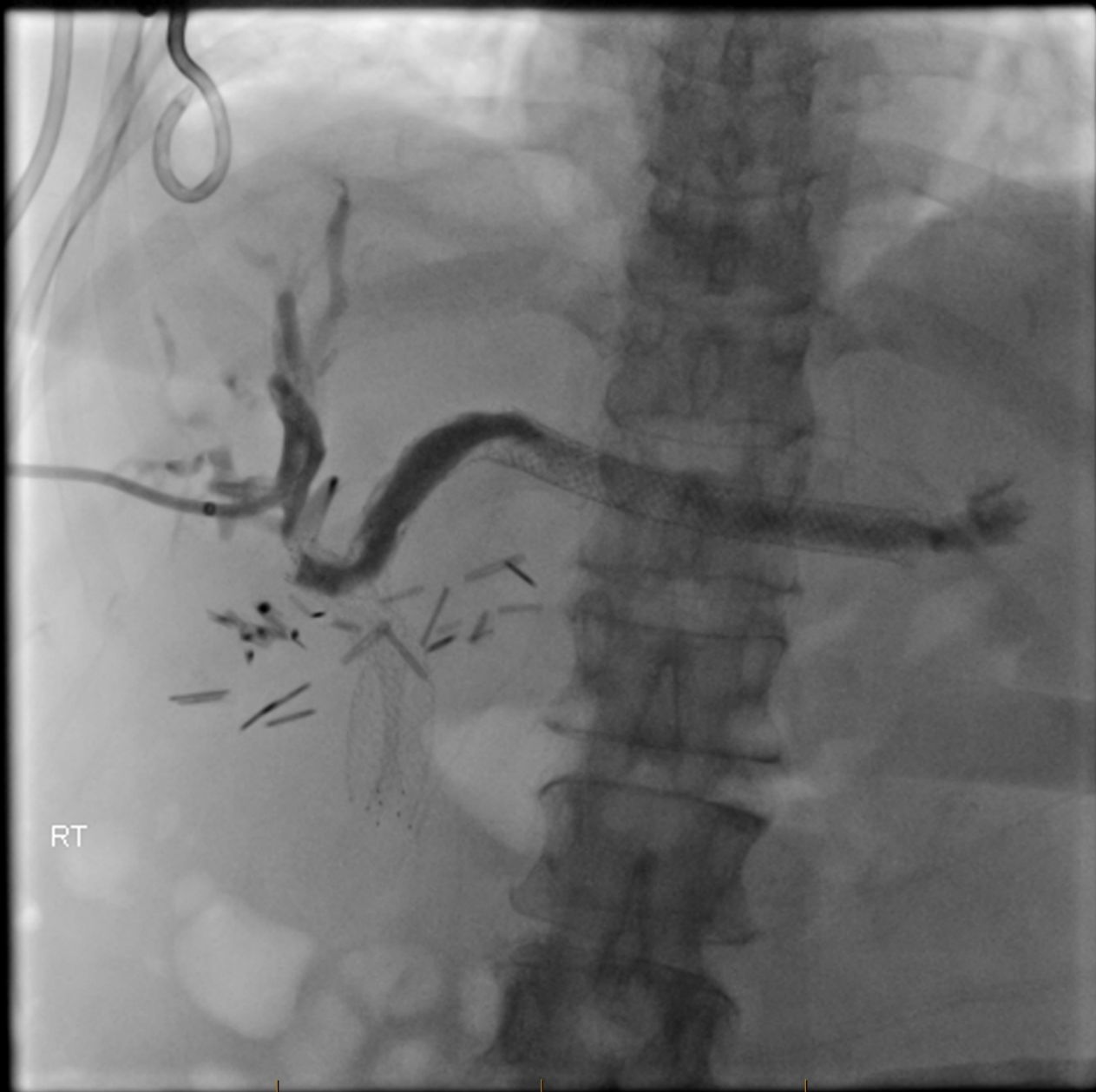RT



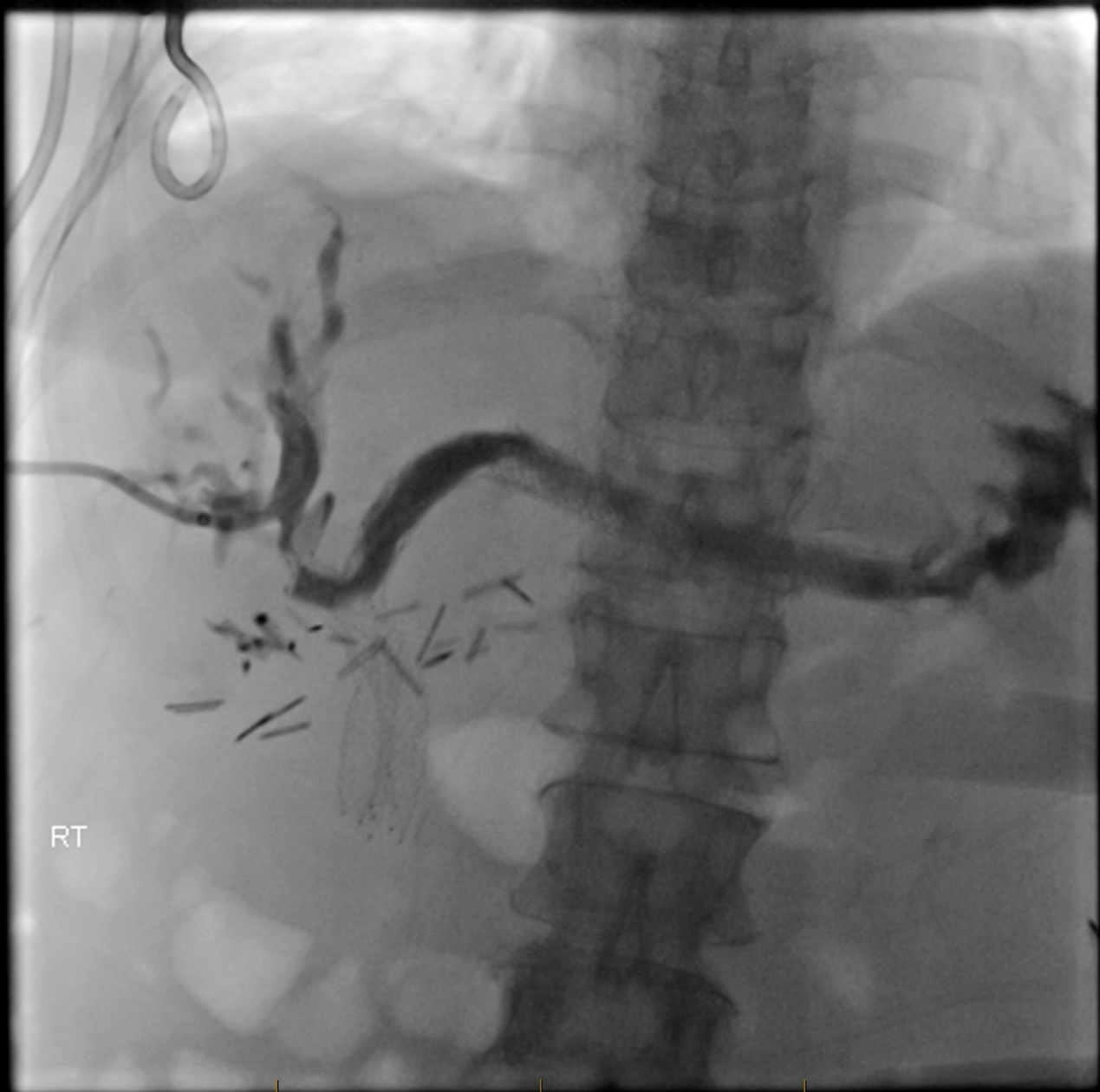P ●



RT



RT



RT



# Clinical Progress

---

- No clinical evidence of cholangitis for 2 months following the procedure and chemotherapy was restarted