

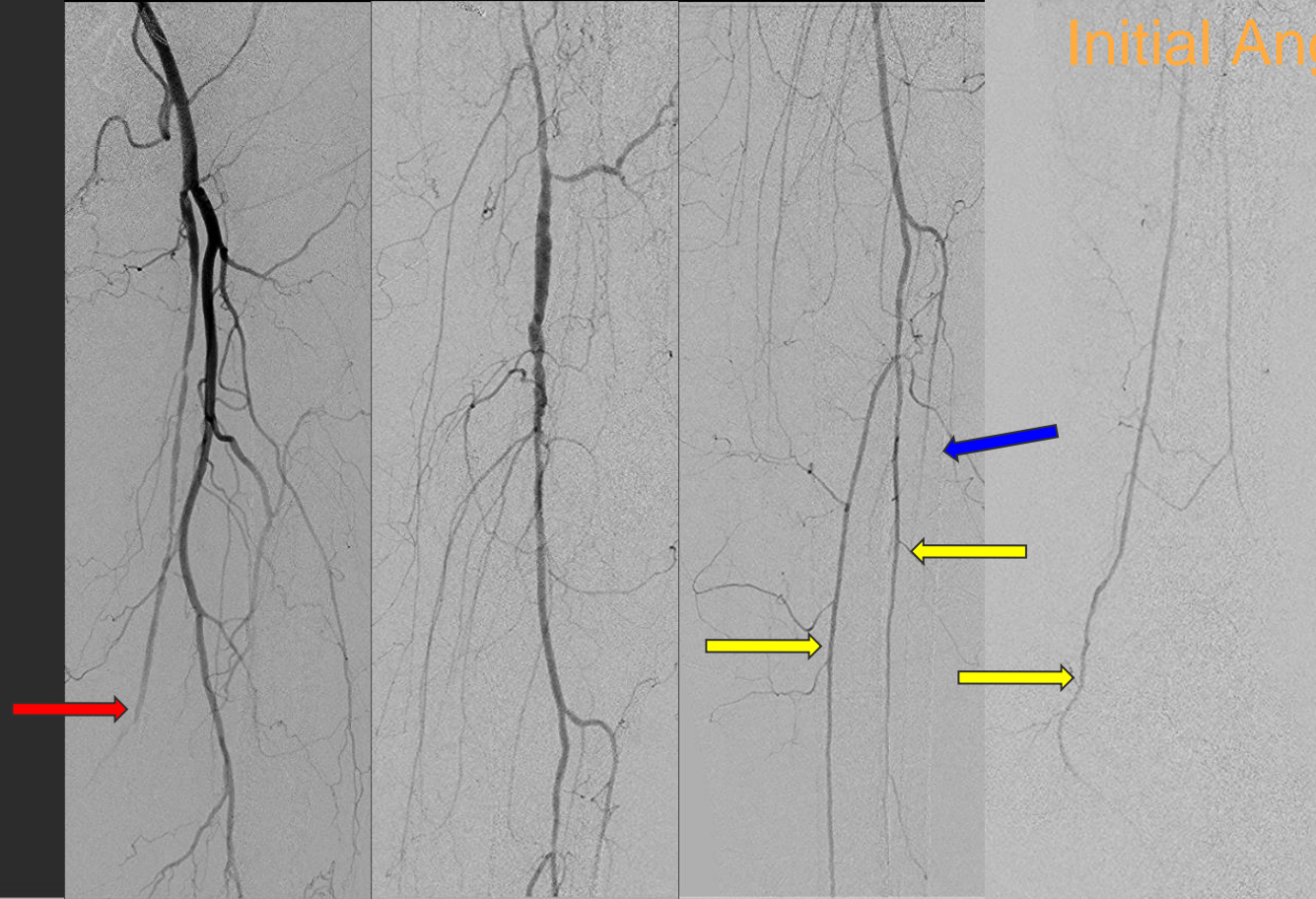
CAIR Case of the Month

Case Courtesy of Drs. A. Aziz Qazi, K. T. Tan and T. Chan
University of Toronto

CASE PRESENTATION

- 77 year old female presents with critical limb ischemia of the left foot - pain at rest
- Previous history of lung transplant, scleroderma and extensive arterial disease treated with femoral artery drug-eluting balloon angioplasty
- Patient had a diagnostic angiogram

Initial Angiogram



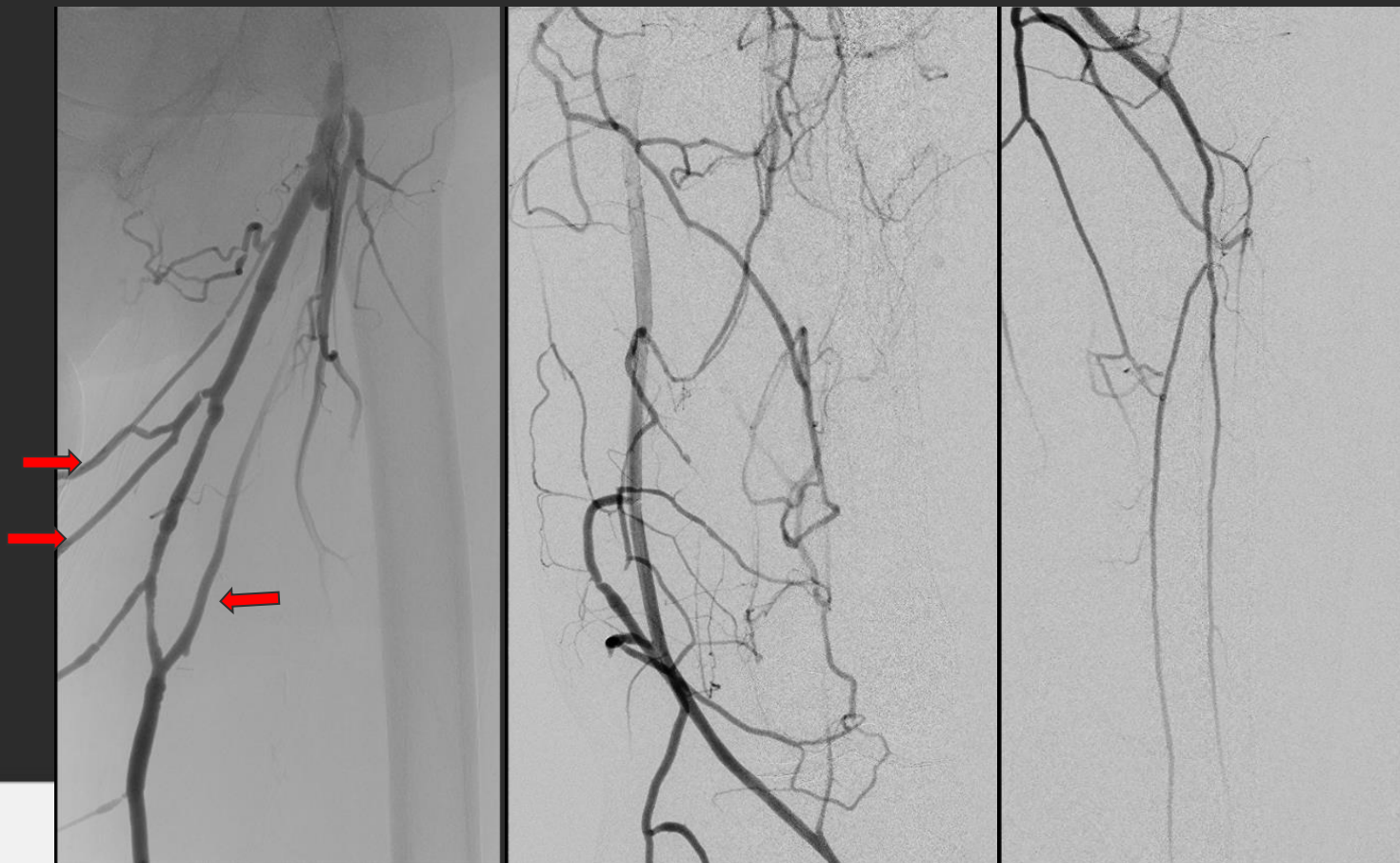
Initial Angiogram

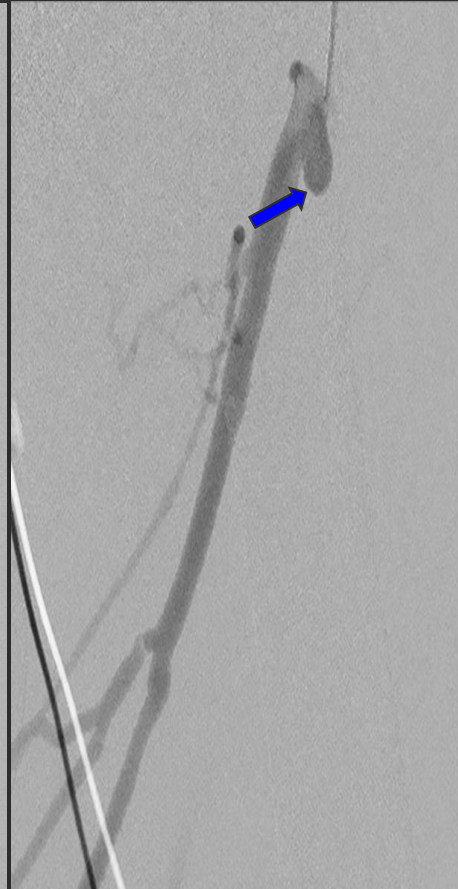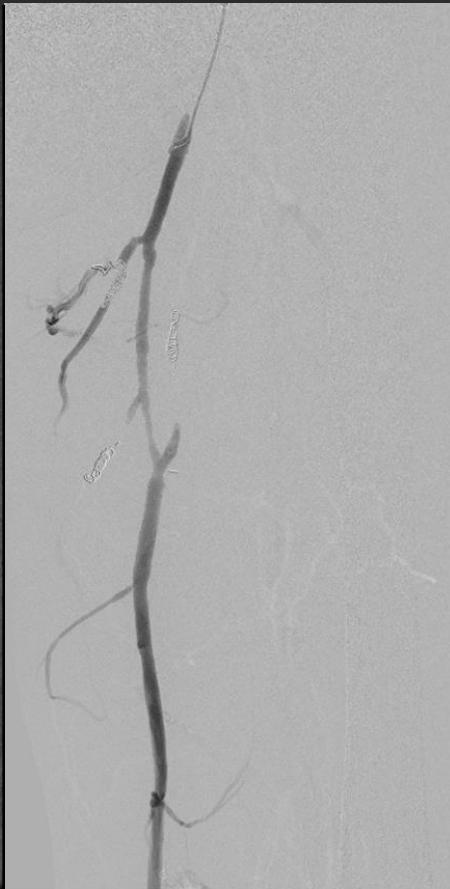
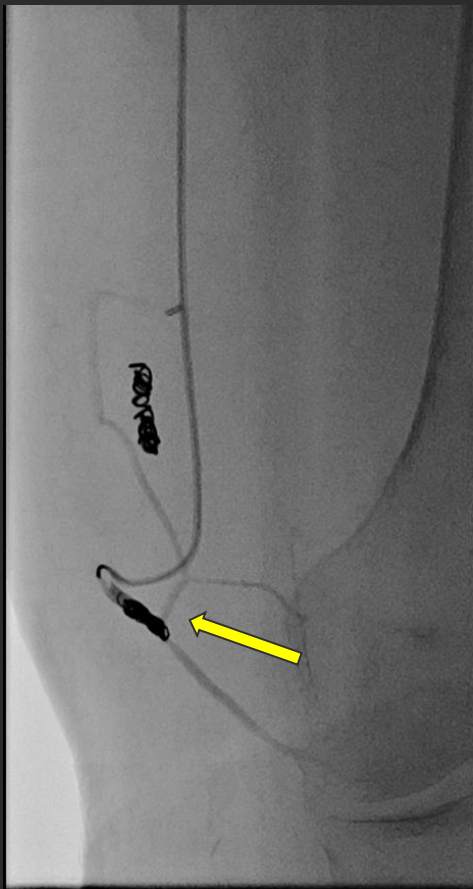
- Angiogram performed with right retrograde access and 5Fr Cobra catheter
- Multifocal SFA stenosis with **sluggish proximal flow and distal occlusion**
- **ATA occluded mid-calf**
- **Two vessel runoff with PTA and peroneal**
- Patient randomized to BEST-CLI trial
- Underwent left femoral-tibial in situ great saphenous bypass graft

Follow-up - 3 Months

- Patient had arterial doppler 3 months after bypass
- Patent femoral-tibial artery bypass graft
- Hemodynamically significant stenosis proximal graft (PSV 412 cm/s) and mid graft (PSV 320 cm/s)
- Small pseudoaneurysm/outpouching (0.6 x 0.6 cm) at proximal anastomosis
- Repeat angiogram requested

Follow-up Angiography

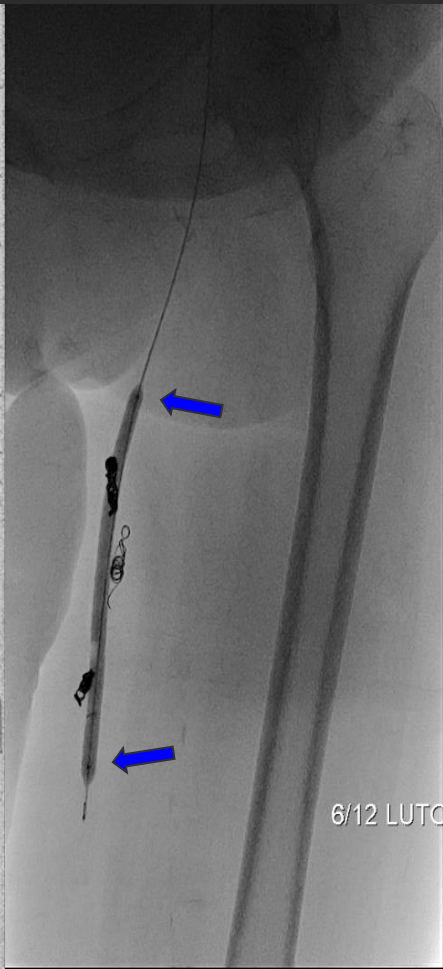
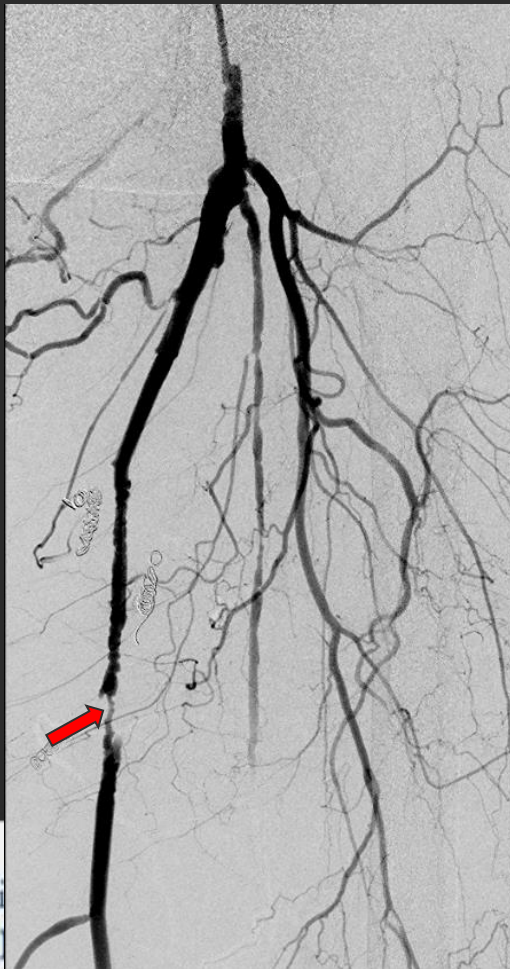



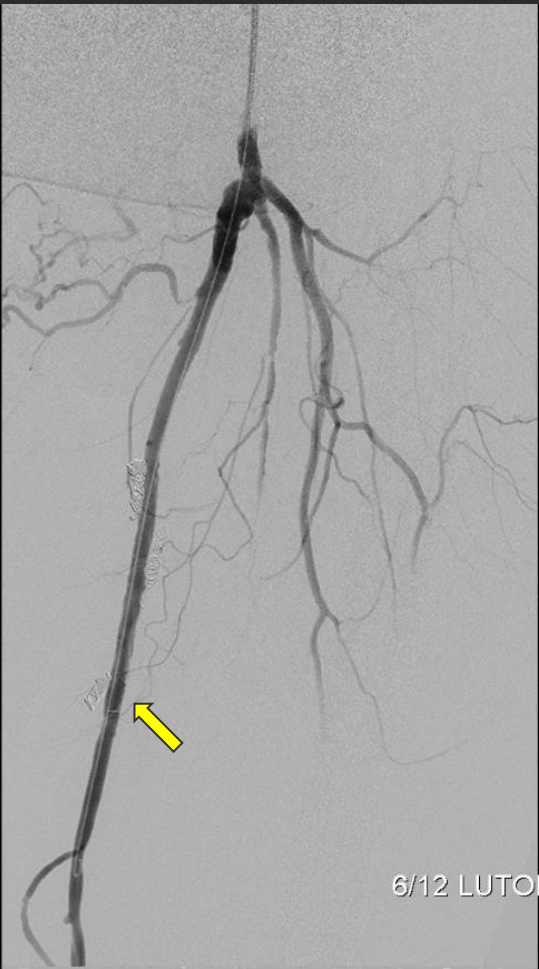
Follow-up Angiography

- **Extensive venous collateral** causing shunting from the bypass graft
- **6 collateral veins were embolized** with coils using a combination of 100 cm 5Fr DAV, 2.4Fr Progreat microcatheter and double-angled GT glidewire
- **Small pseudoaneurysm at the proximal bypass treated conservatively**

6 Month Follow-up Angiography



LT
6/12 LUTONIX

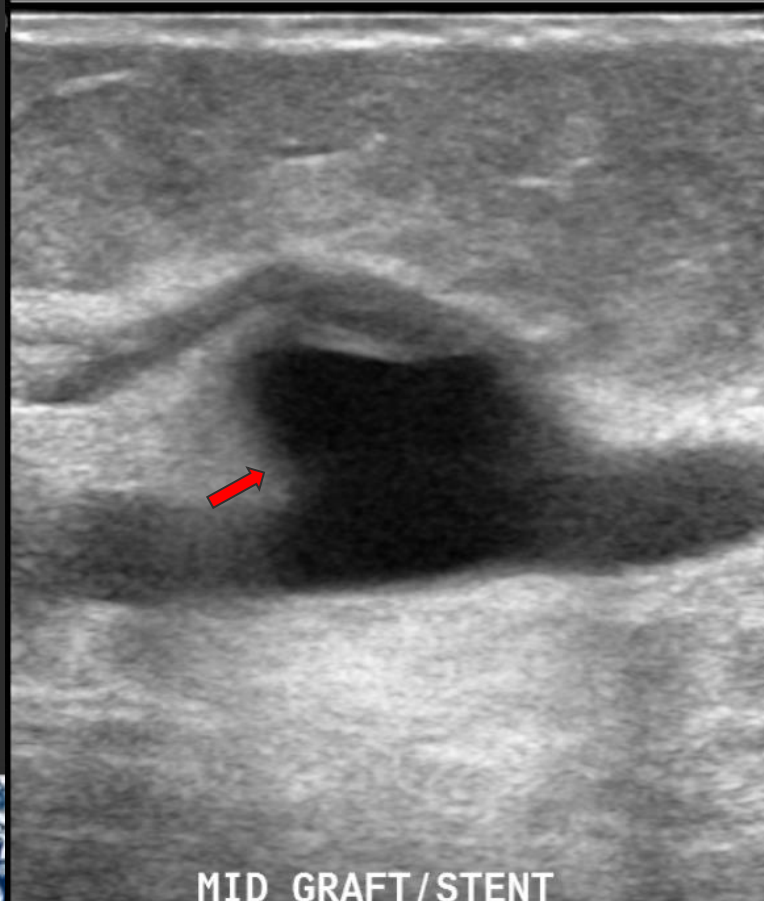


6/12 LUTONIX

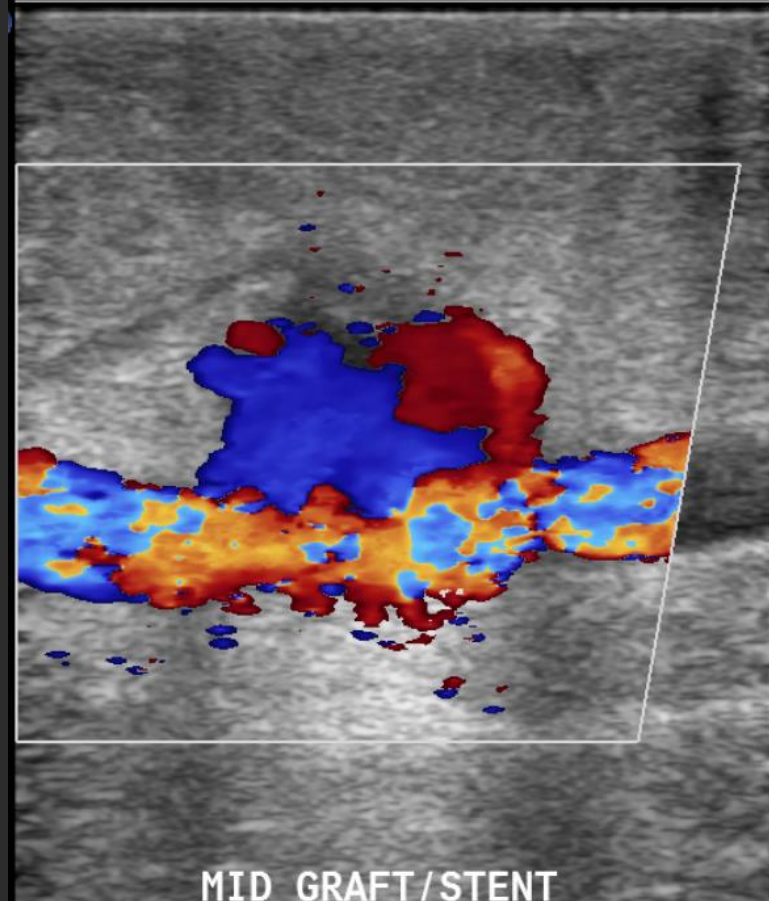
6 Month Follow-up Angiography

- **Focal severe stenosis** of the bypass graft
- Bypass graft angioplastied using overlapping segments with a 5 x 40 mm Mustang balloon
- Re-angioplastied with **6 x 120 mm Lutonix drug-coated balloon** to **good angiographic results**
- Residual venous collaterals embolized

Arterial Doppler Study - 1 month later

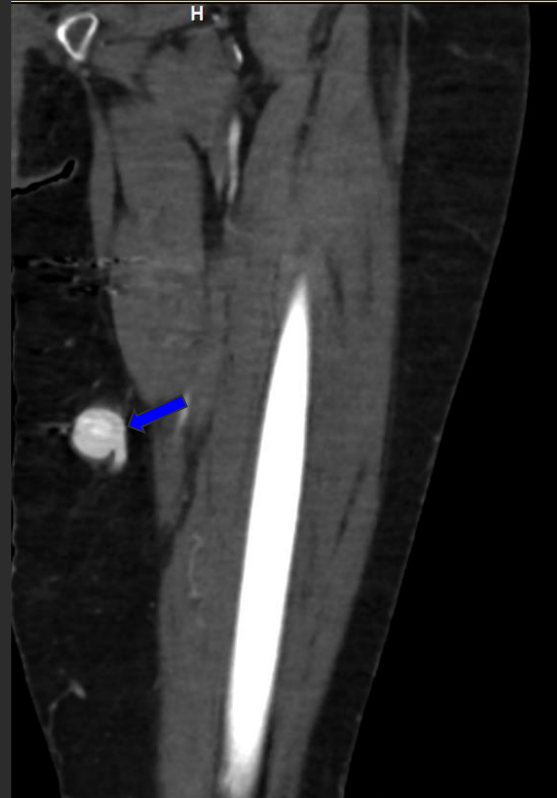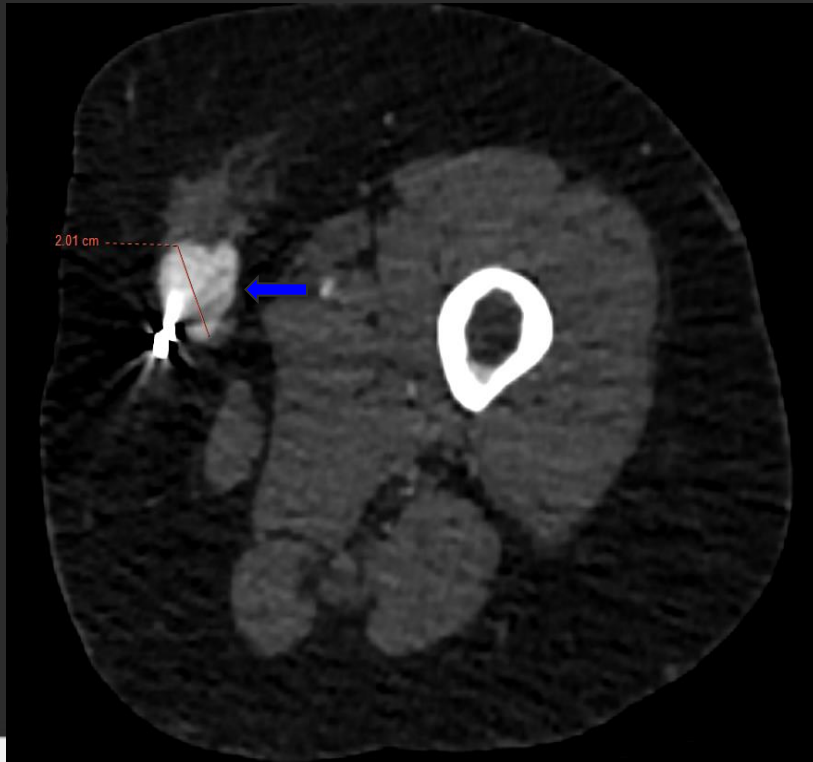


MID_GRAFT/STENT



MID GRAFT/STENT

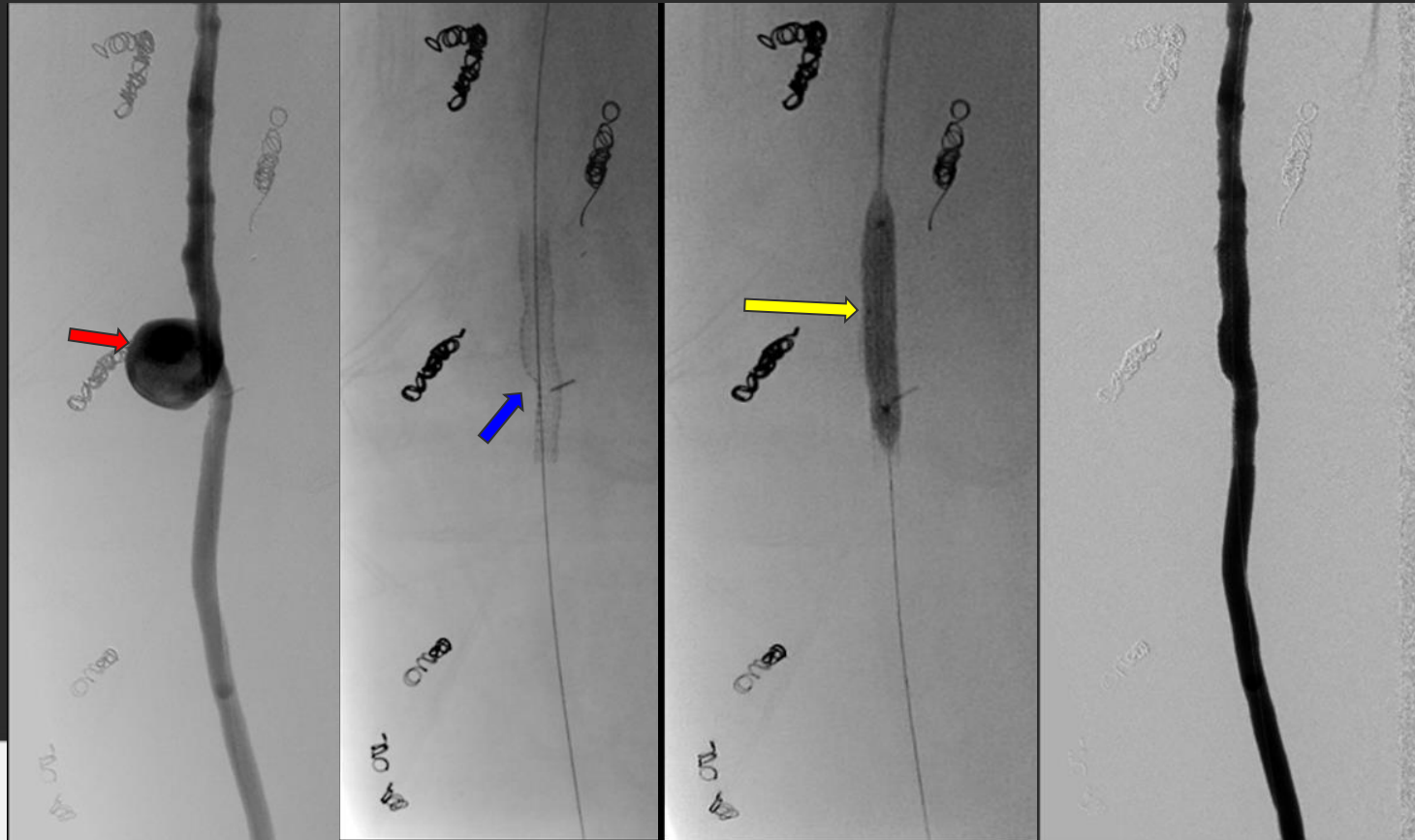
CT Angiogram - 1 month later



Follow-up - 1 month later

- F/U doppler study shows a 2.0 cm aneurysm arising from the mid-graft
- CT confirms finding - large saccular aneurysm arising from the mid femoral-popliteal graft

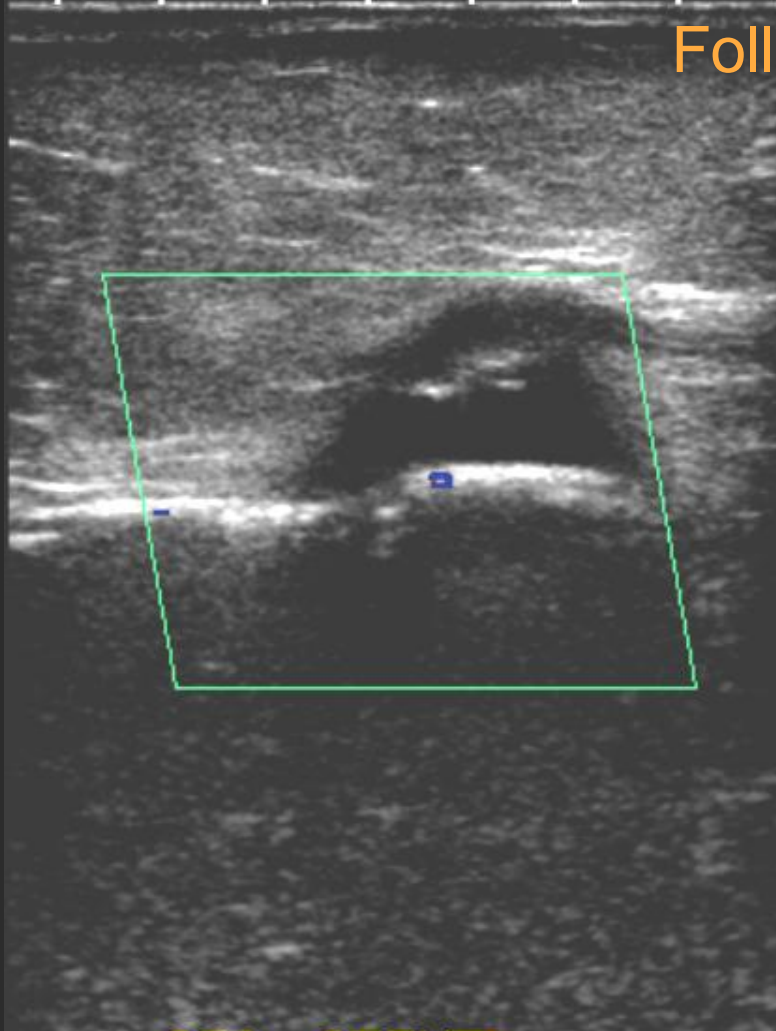
Follow-up - Angiogram



Follow-up - Angiogram

- Up and over angiogram with a 45 cm vascular sheath - angiogram performed shows a **large saccular aneurysm**
- A **7 x 50 mm Viabahn covered stent graft** deployed over a V18 wire over the aneurysm neck
- **Post dilated to 7 mm**
- Post angiography demonstrated complete exclusion of the aneurysm

Follow-up Ultrasound

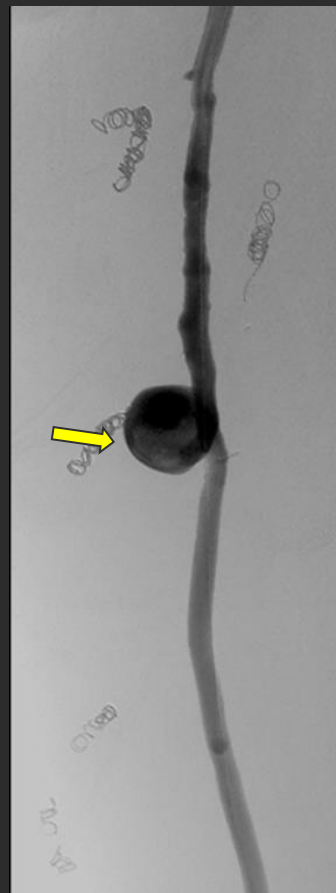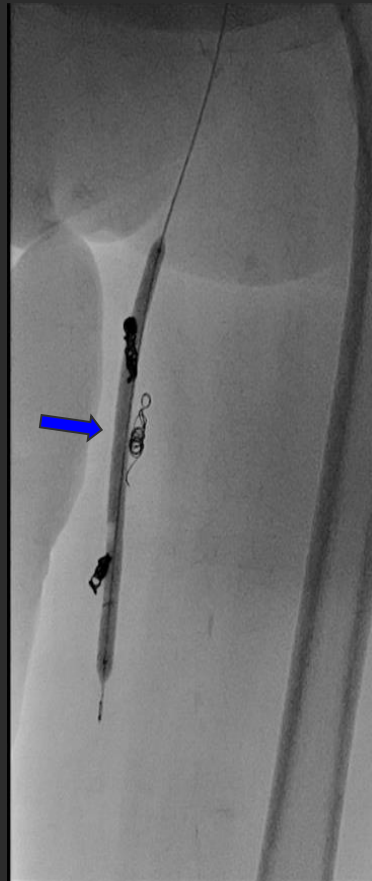

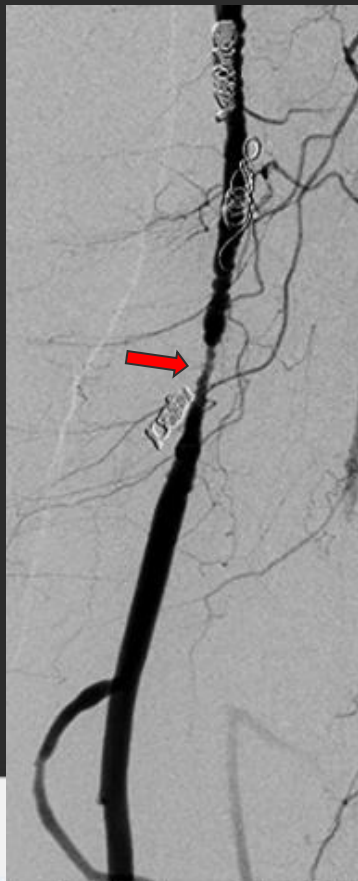
SFA STENT

Follow-up Ultrasound

- F/U doppler study shows complete exclusion of the aneurysm

SUMMARY



- **Focal severe stenosis of mid fem-pop** in-situ venous bypass graft **treated with drug-coated balloon** results in **aneurysm formation** at the treatment site

DISCUSSION

- Drug eluting devices (DED) are commonly used for a multitude of vascular problems
- Recent meta-analysis has brought controversy around the use of DED - 28 RCT – increased risk of all-cause mortality with DED¹
- Multiple previous studies have shown a rare small risk of arterial aneurysm with the use of DED - TAXUS V² (coronary arteries - 1.2%) and ELUVIA³ (8%)

DISCUSSION

- Histologic analysis of non-anastomotic vein graft has shown obliteration of normal vessel architecture with penetrating atherosclerotic plaque
- Szilagyi et al found aneurysmal change in 3.8% of venous stent grafts (377 total patients)⁴
- Case reports have noted Paclitaxel-associated aneurysm in venous grafts- poorly understood mechanism⁵

KEY POINT

- Non-anastomotic aneurysm formation in vein bypass grafts post drug-eluting balloon angioplasty
 - Controversy exists if this is related to paclitaxel use or atherosclerotic changes in the vein graft

REFERENCES

1. Katsanos et al. Risk of death following application of paclitaxel-coated balloons and stents in the femoropopliteal artery of the leg: A systematic review and meta-analysis of randomized controlled trials. 2018. Journal of the American Heart Association. 7:24.
2. Stone et al. Paclitaxel-eluting stents vs vascular brachytherapy for in-stent stenosis with bare metal stents; the TAXUS V ISR randomized trial. 2006. JAMA. 15;295(11):1253-63.
3. Bisdas et al. 1-year all-comers analysis of the ELUVIA drug-eluting stent for long femoropopliteal lesions after subintimal angioplasty. 2018. Cardiovascular Interventions. Volume 11, Issue 10, 957-966.
4. Alexander et al. Atherosclerotic aneurysm formation in an in situ spahenous vein graft. Journal Vascular surgery. 1994. 20;4-p660-664.
5. Diamantopoulos et al. Paclitaxel-coated balloons and aneurysm formation in peripheral vessels. 2015. Journal of Vascular Surgery. 62; 5. 1320- 1322.