

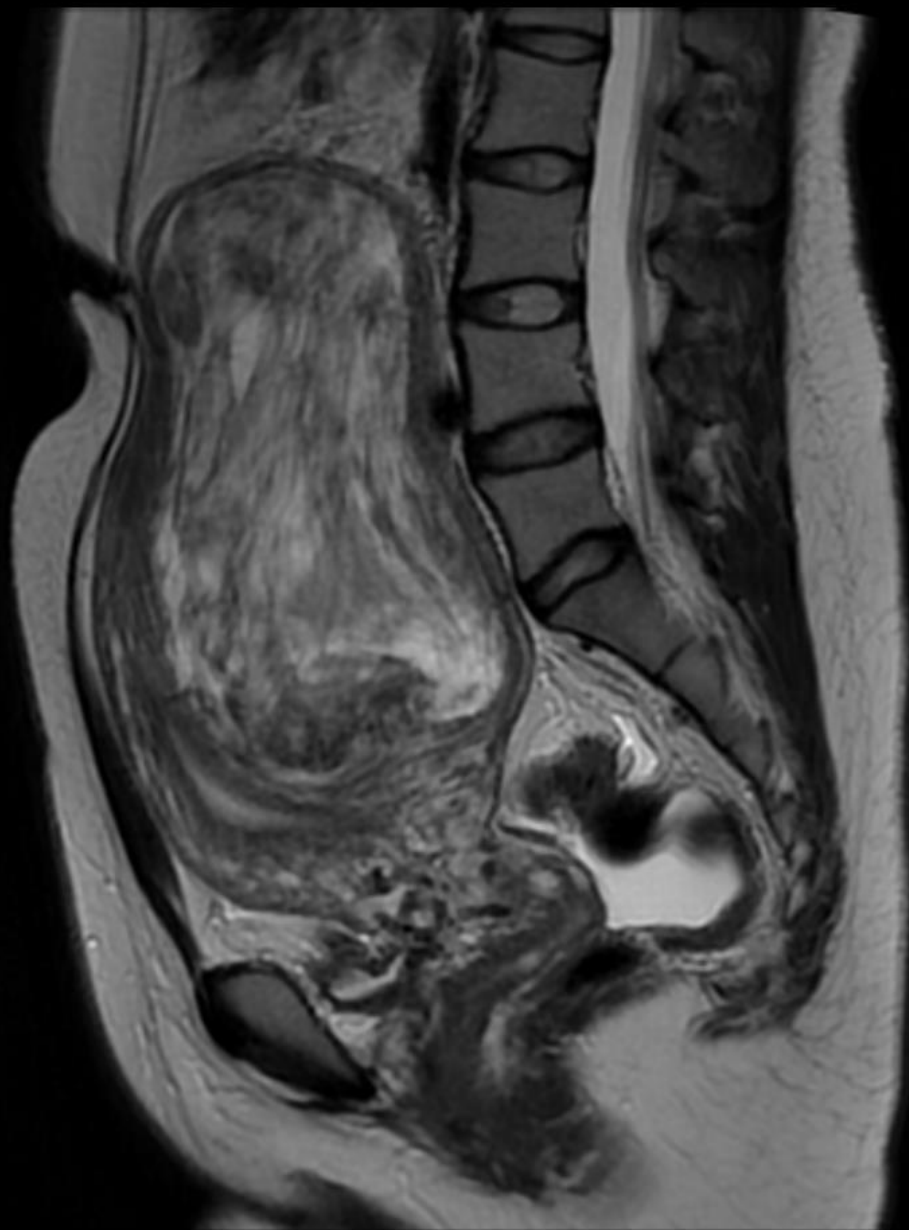CAIR Case of the Week

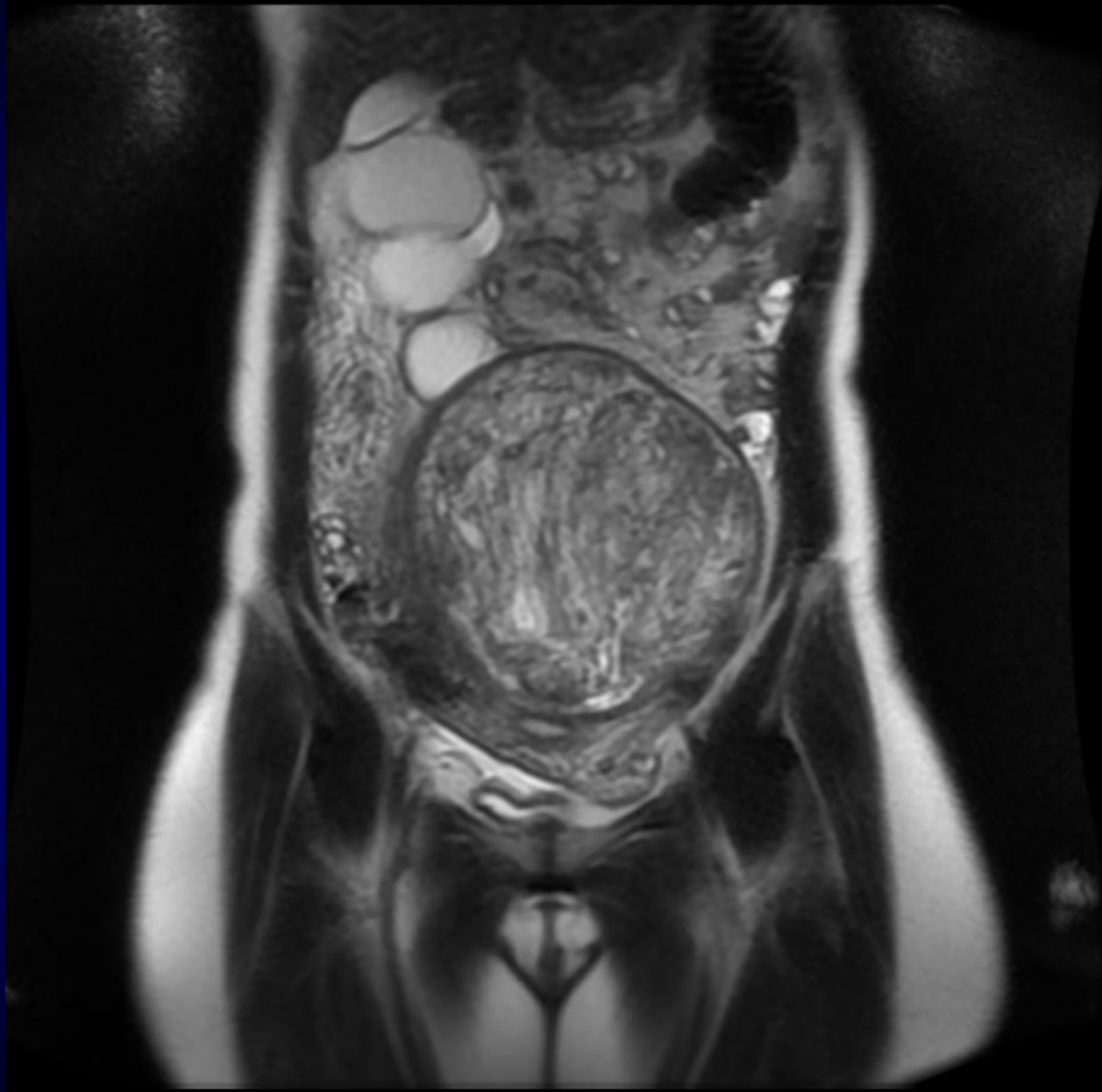
Case Courtesy of Drs. S. Bailey and M. Simons
University of Toronto

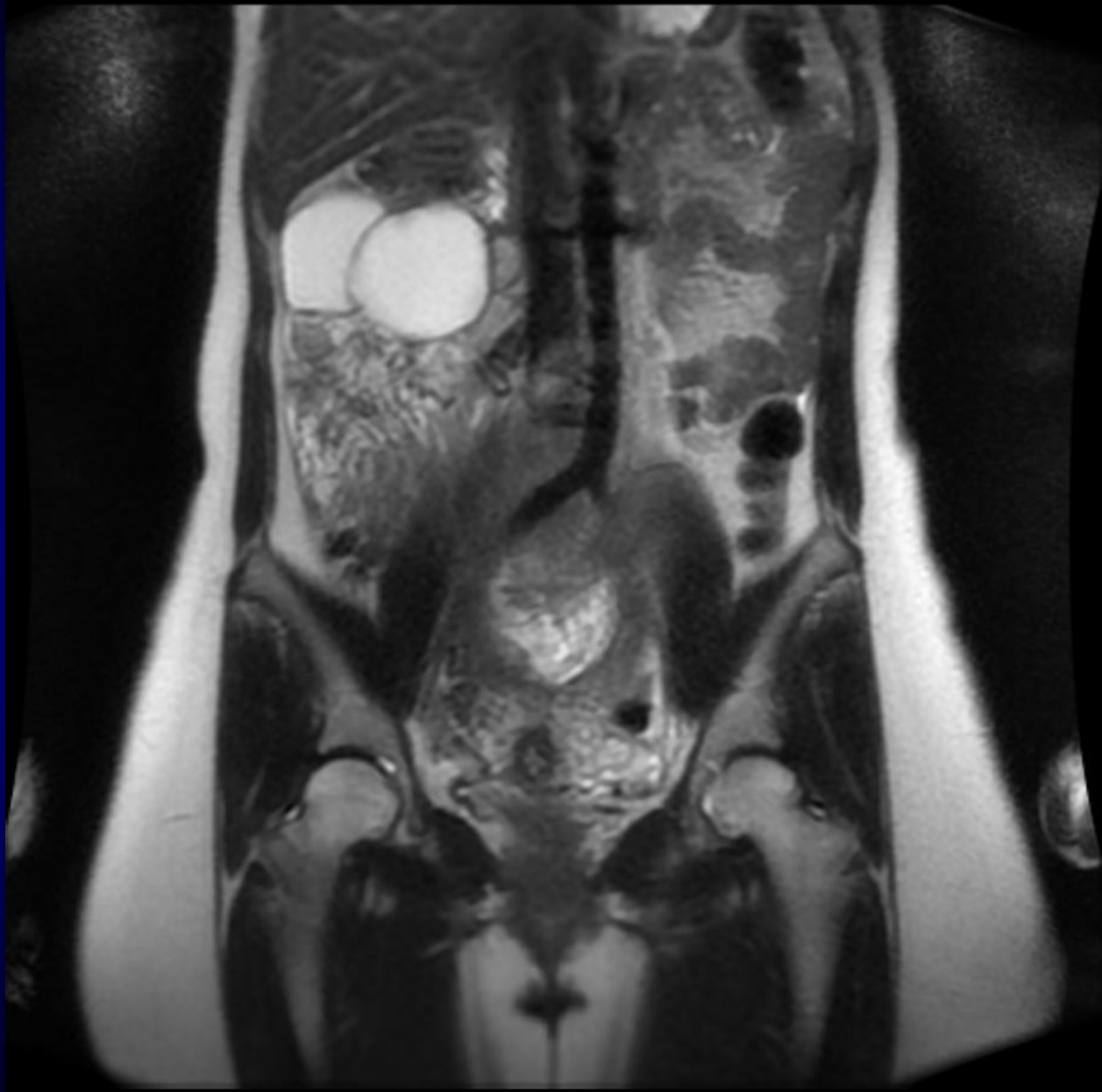
Clinical Presentation – Ms. O

- 31 year-old female G1P1
- No significant medical or surgical history
- Symptomatic uterine fibroid x 5 years
 - irregular periods
 - menorrhagia with secondary iron deficiency anemia
 - dysmenorrhea
 - pelvic mass

Baseline Imaging

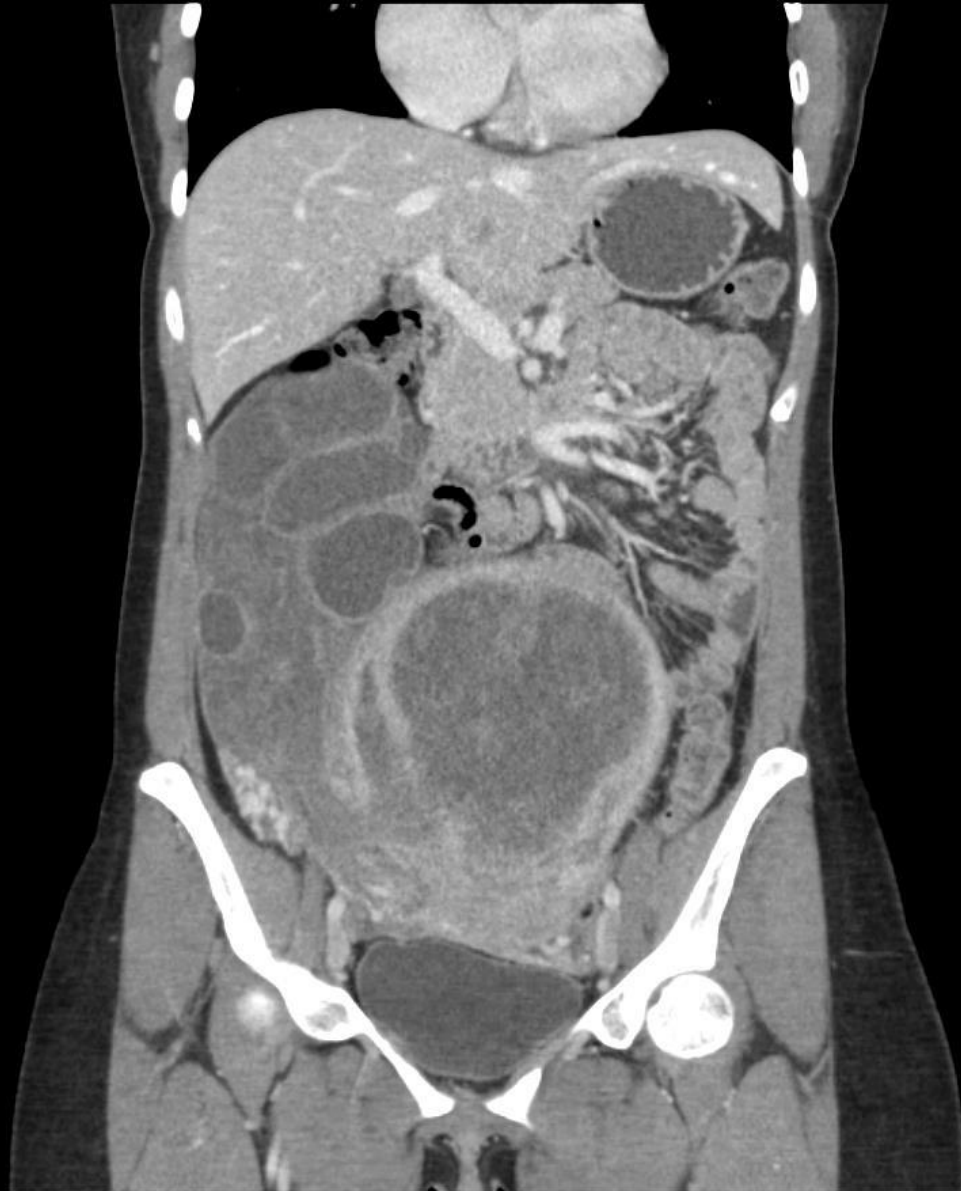


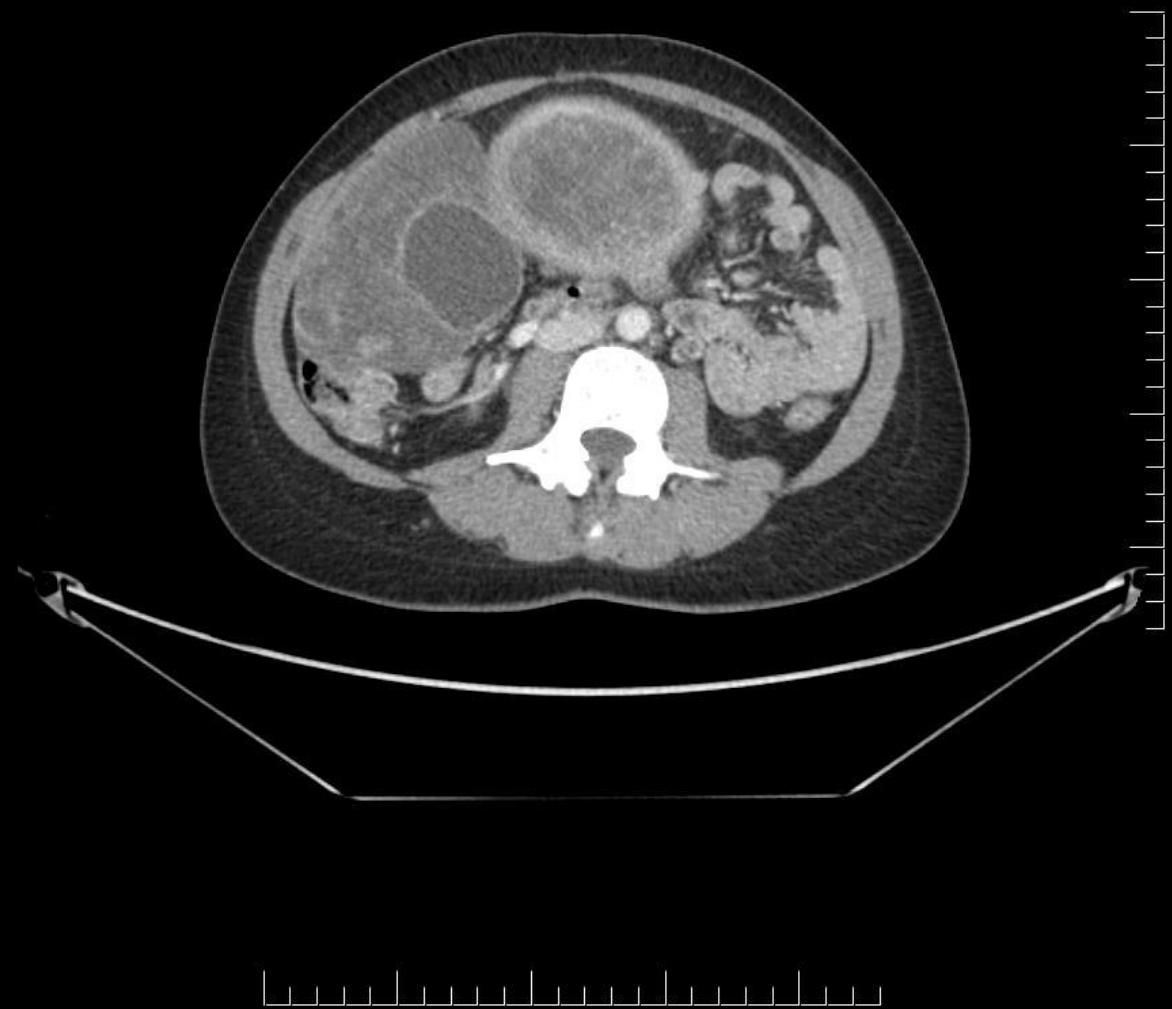


Initial MRI

- Large central fibroid measuring 12 x 6 x 15 cm
- Enlarged right ovary displaced into the RUQ with suspected AVM
- Left ovary is normal



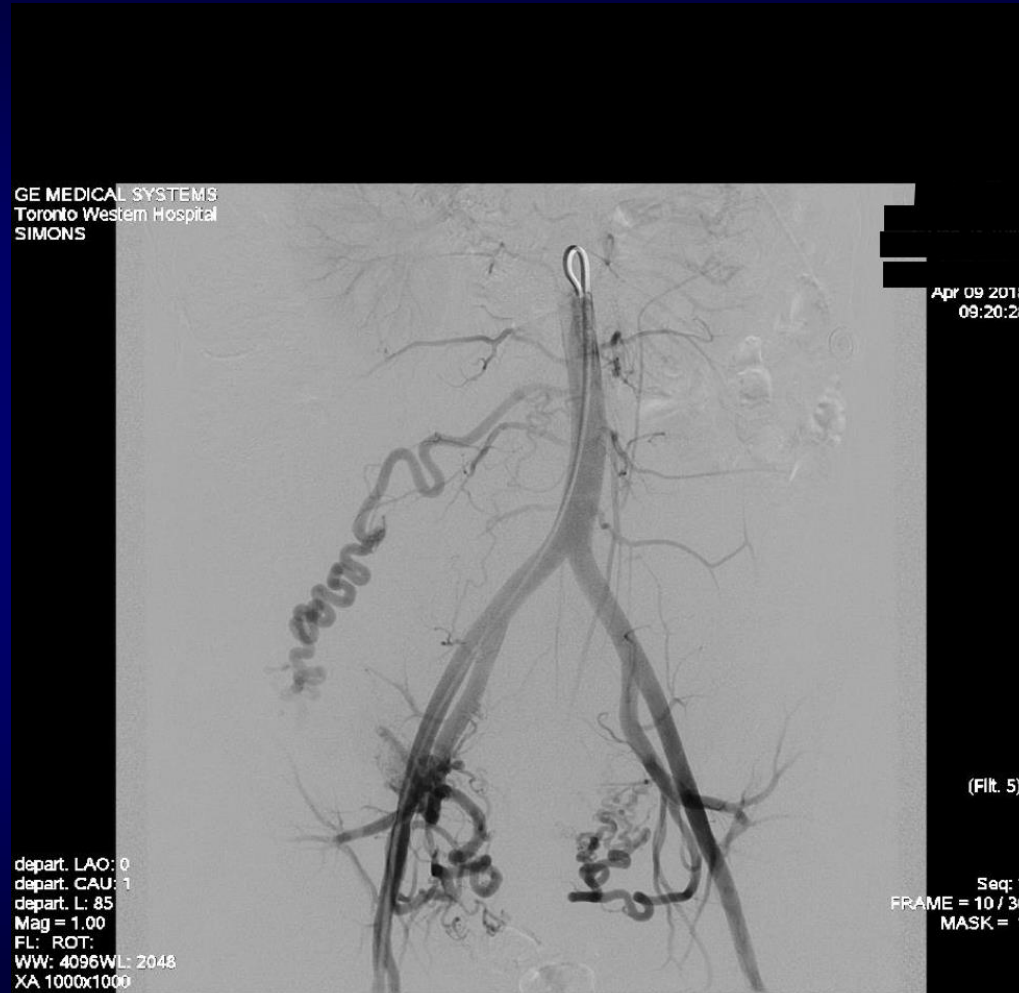

Initial CT

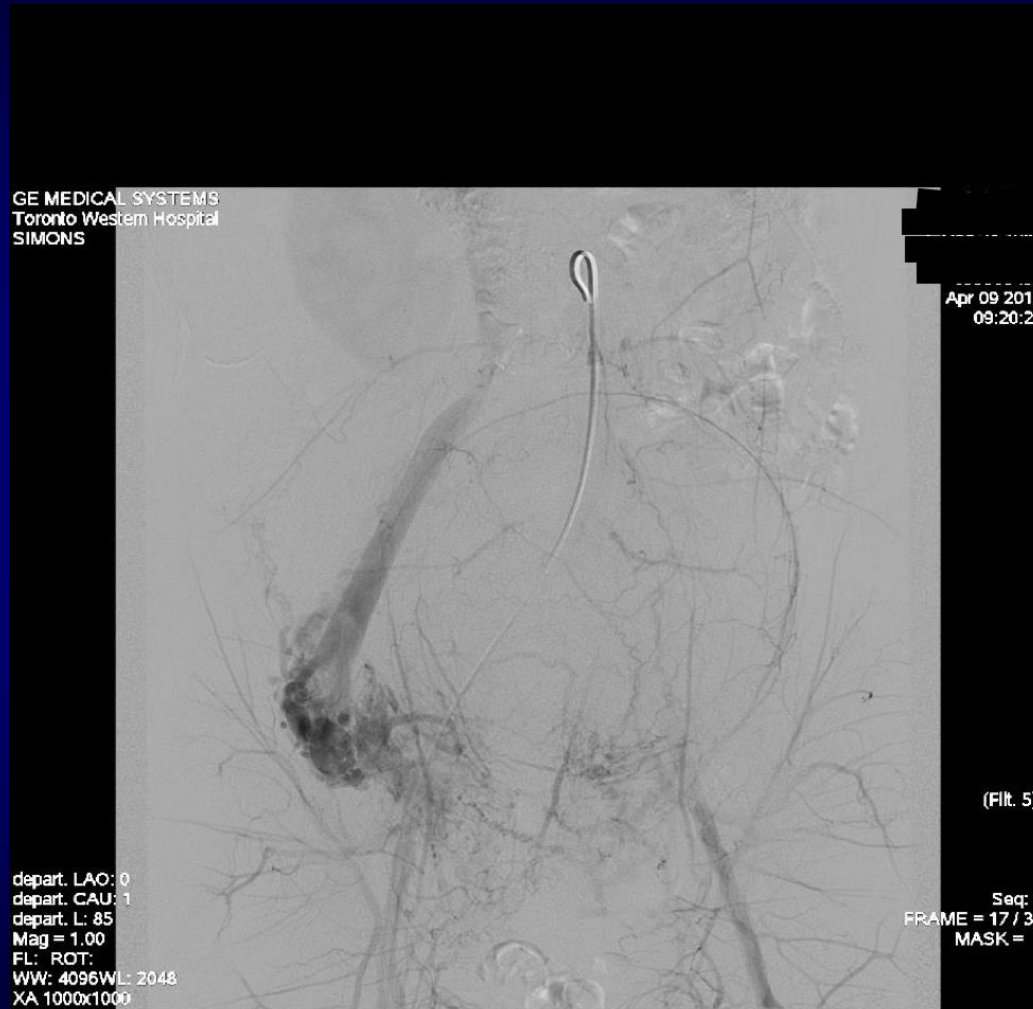- Large central fibroid measuring 12 x 6 x 15 cm
- Enlarged congested right ovary

Booked for uterine fibroid and pelvic
AVM embolization

Initial Aortogram



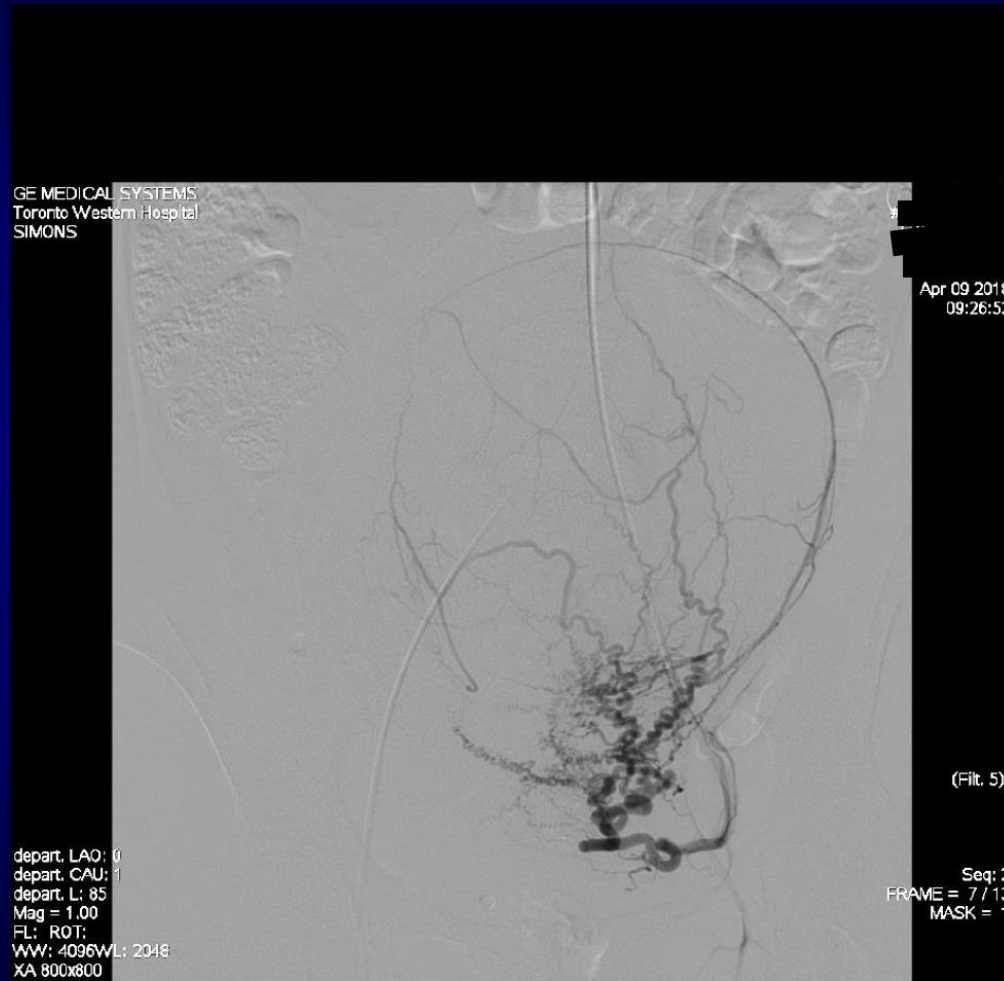
Initial Aortogram



Initial Aortogram

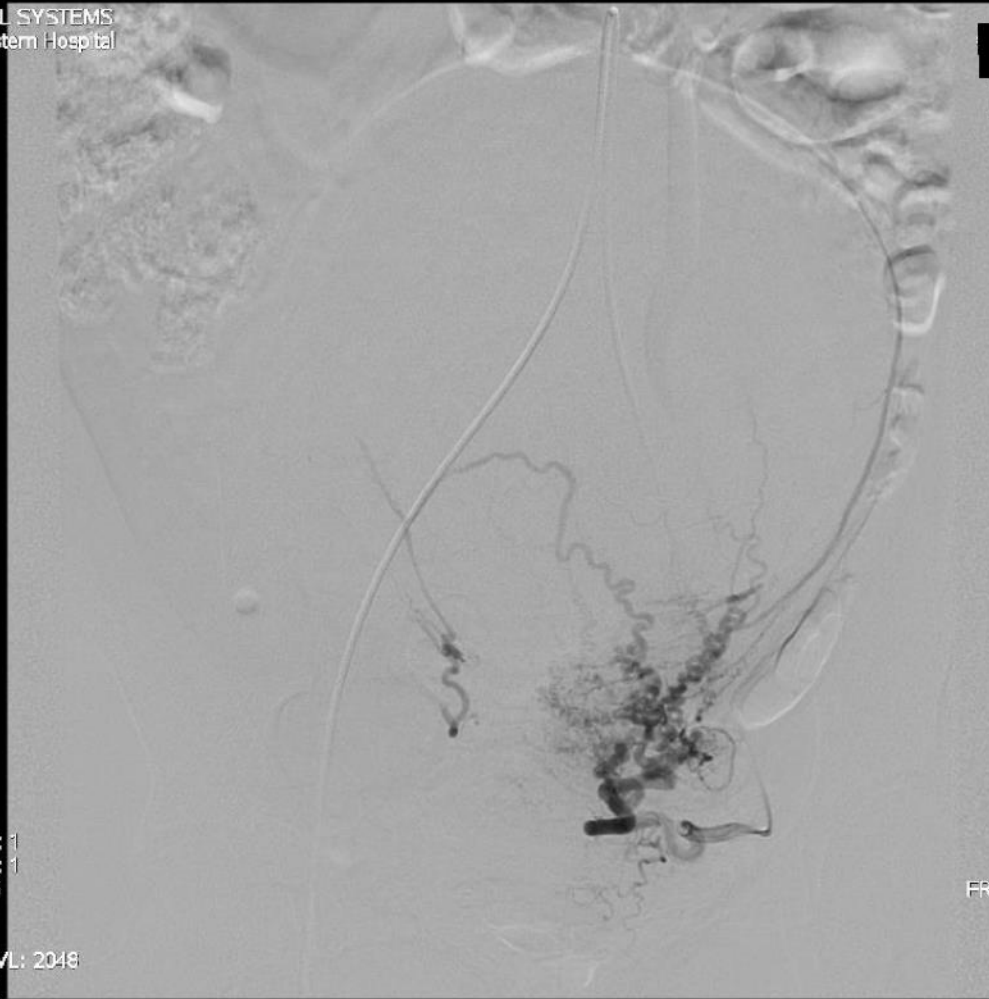
- Dilated tortuous uterine arteries bilaterally
- Rapid flow into a dilated right gonadal artery with shunting to an enlarged right gonadal vein

Initial left uterine artery run



GE MEDICAL SYSTEMS
Toronto Western Hospital
SIMONS

Apr 09 2018
09:33:18



depart. RAO: 1
depart. CAU: 1
depart. L: 85
Mag = 1.00
FL: ROT:
WW: 4096WL: 2048
XA 800x800

(Filt. 5)

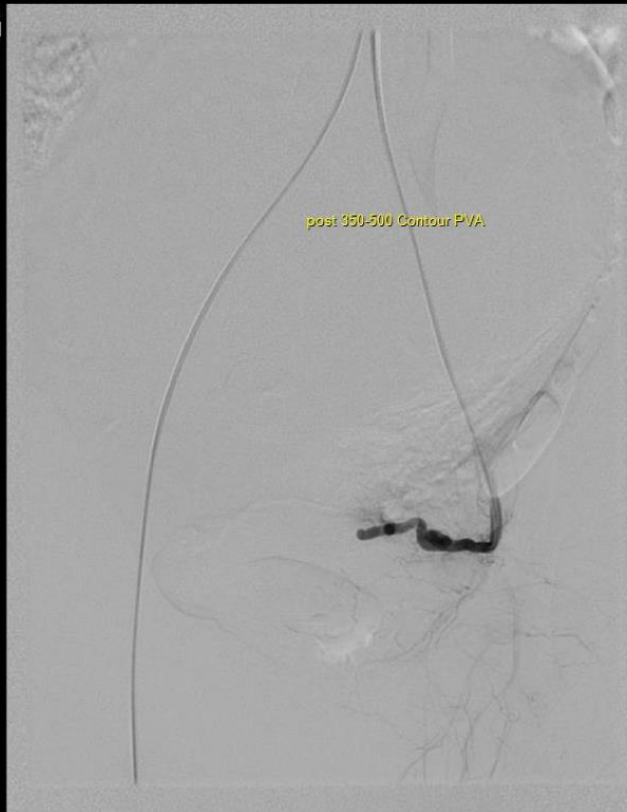Seq: 3
FRAME = 11 / 17
MASK = 1

Initial left uterine artery run

- A 5 Fr Roberts catheter was inserted and used to select the left internal and then left uterine artery at its transverse segment
- Embolization was performed to near stasis using approximately 3.5 vials of 355-500 micron PVA particles
- 10 ml of 1% lidocaine was instilled after embolization

Left uterine artery post-embolization

GE MEDICAL SYSTEMS
Toronto Western Hospital
SIMONS



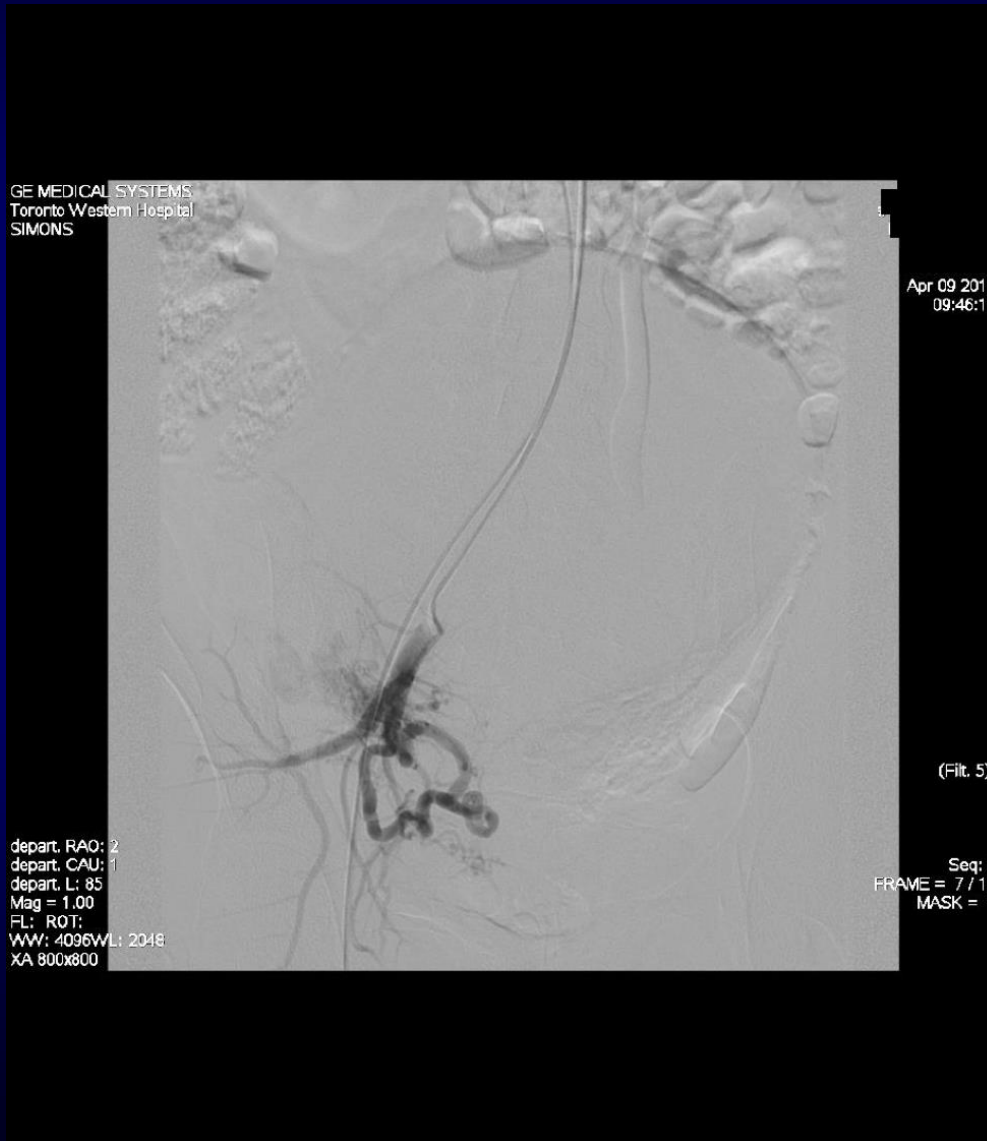
Apr 09 2018
09:44:21

(Filt. 5)
(Shut.)

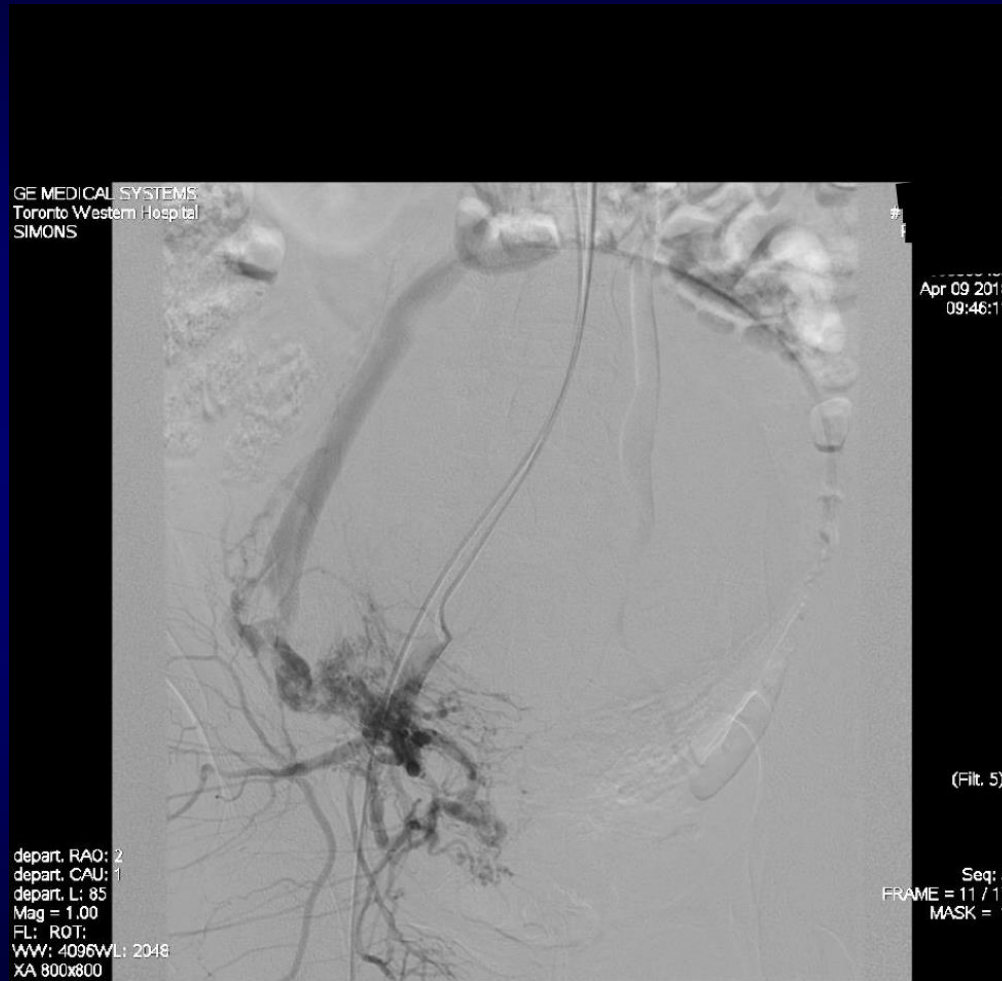depart. RAO: 1
depart. CAU: 1
depart. L: 85
Mag = 1.00
FL: ROT:
WW: 4096WL: 2048
XA 800x800

Seq: 4
FRAME = 12 / 12
MASK = 1

Right uterine artery run



Right uterine artery run



Right uterine artery run

- The Roberts catheter was used to select the right internal iliac artery
- Angiography demonstrated rapid shunting into a dilated right gonadal vein from the right uterine artery distribution

Right gonadal vein run

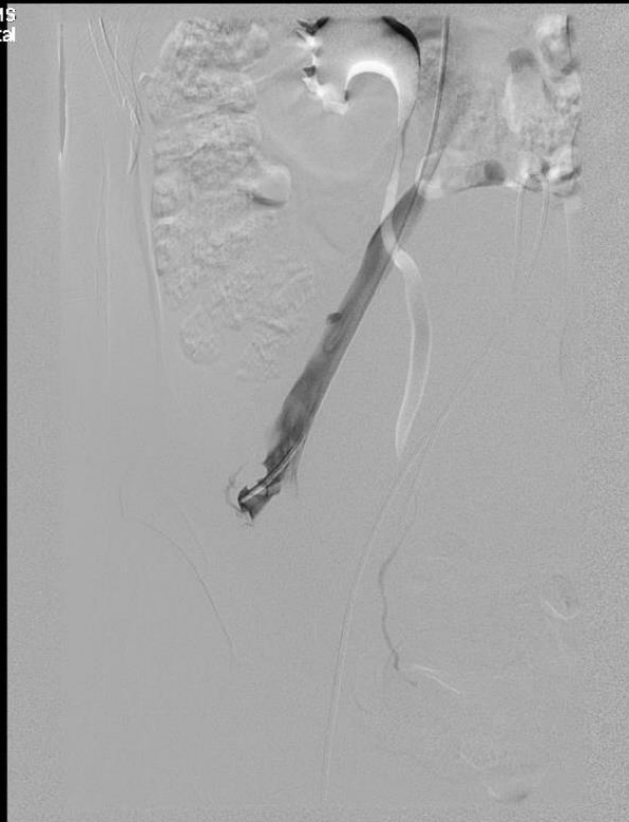GE MEDICAL SYSTEMS
Toronto Western Hospital
SIMONS

Apr 09 2018
10:06:17

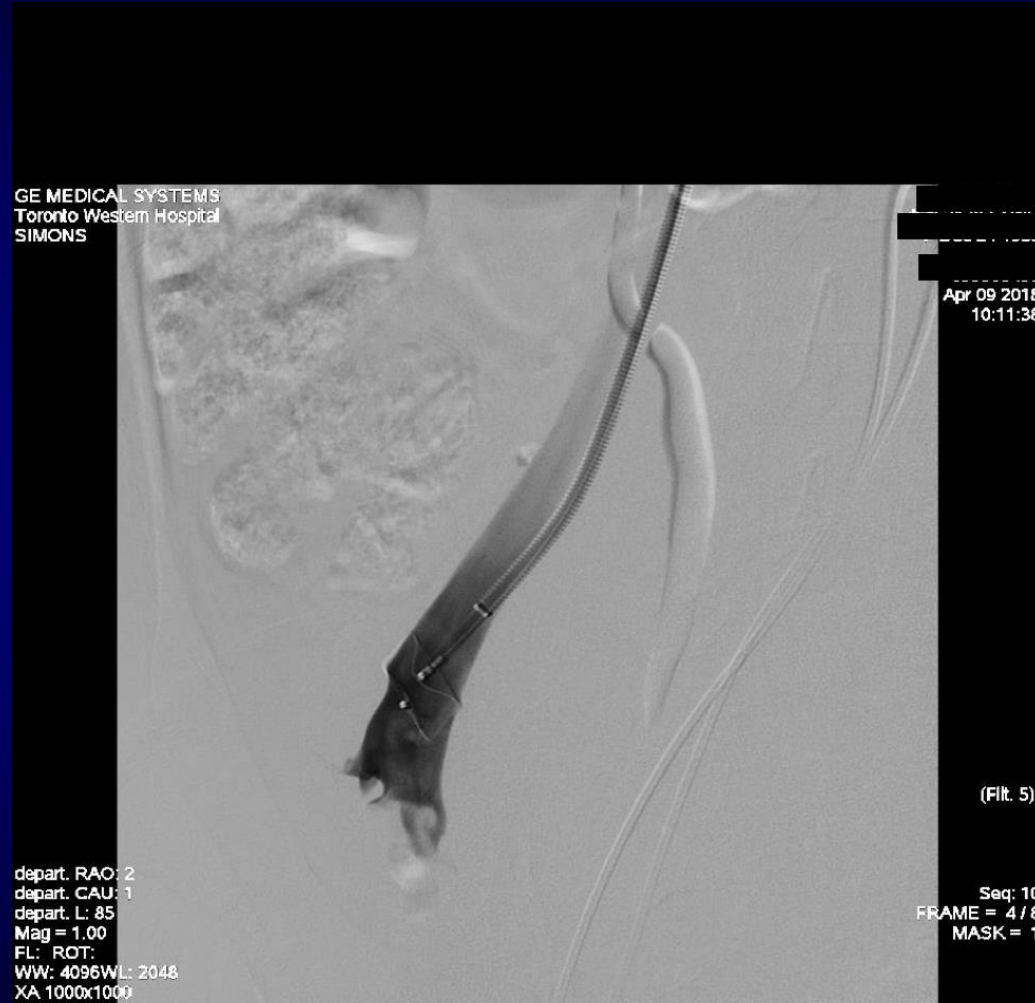depart. RAO: 2
depart. CAU: 1
depart. L: 85
Mag = 1.00
FL: ROT:
WW: 4096WL: 2048
XA 1000x1000

(Flt. 5)
(Shut.)

Seq: 9
FRAME = 8 / 12
MASK = 1



Right gonadal vein run



Right gonadal vein run

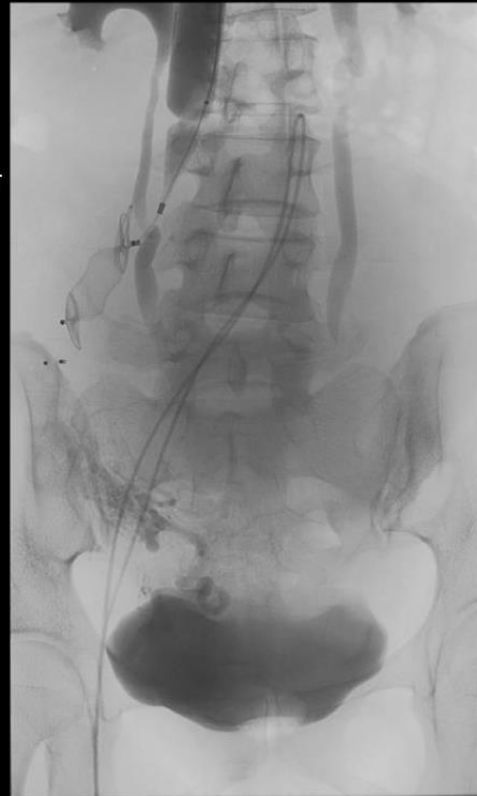
- The right internal jugular vein was punctured and a 7 Fr sheath was inserted into the dilated right gonadal vein
- Two Amplatzer plugs were deployed in the mid-portion of the right gonadal vein (16 mm and 20 mm type 1 and 2)
- An 18 mm x 4 cm angioplasty balloon was inflated in the proximal right gonadal vein

Right uterine artery

GE MEDICAL SYSTEMS
Toronto Western Hospital
SIMONS

Apr 09 2018
10:25:51

RT



(Flt. 5)
(Shut.)

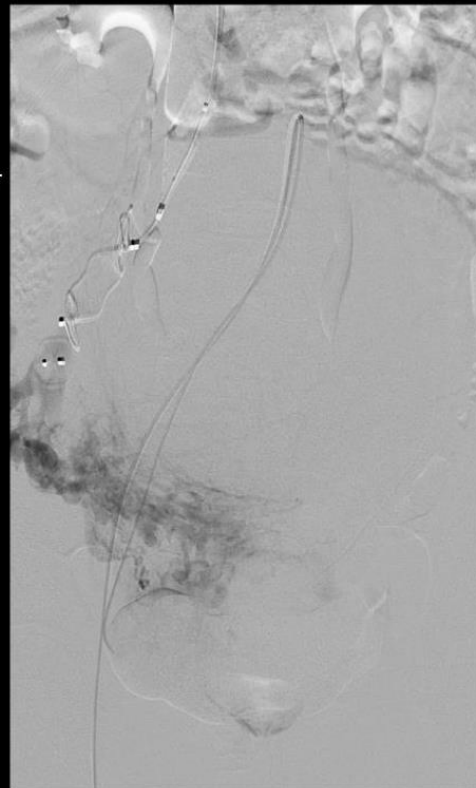
depart. RAO: 2
depart. CAU: 1
depart. L: 85
Mag = 1.00
FL: ROT:
WW: 4096WL: 2048
XA 1000x1000

Seq: 11
FRAME = 6 / 13

Right uterine artery

GE MEDICAL SYSTEMS
Toronto Western Hospital
SIMONS

RT



853503459
Apr 09 2018
10:25:51

(Filt. 5)
(Shut.)

depart. RAO: 2
depart. CAU: 1
depart. L: 85
Mag = 1.00
FL: ROT:
WW: 4096WL: 2048
XA 1000x1000

Seq: 11
FRAME = 13 / 13
MASK = 1

Right uterine artery

GE MEDICAL SYSTEMS
Toronto Western Hospital
SIMONS

853503459
Apr 09 2018
10:41:15

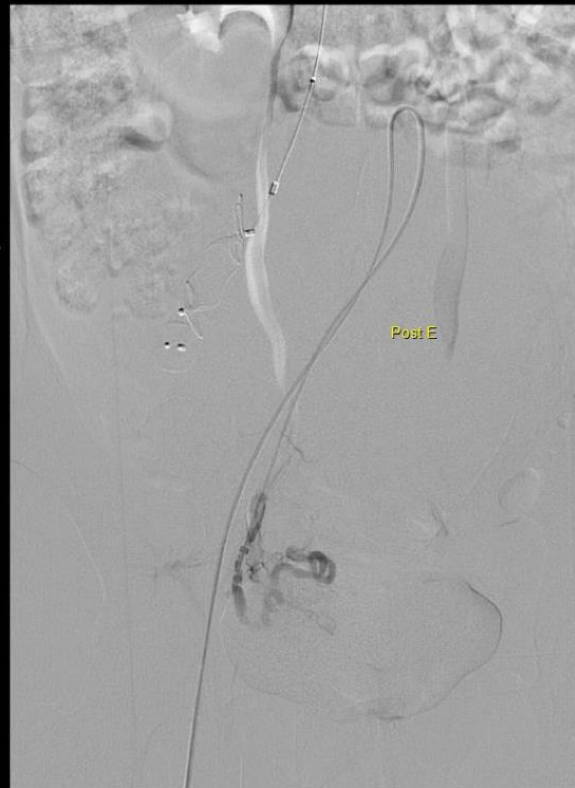RT

Post E

depart. LAO: 2
depart. CAU: 1
depart. L: 85
Mag = 1.00
FL: ROT:
WW: 4096WL: 2048
XA 1000x1000

(Flt. 5)
(Shut.)

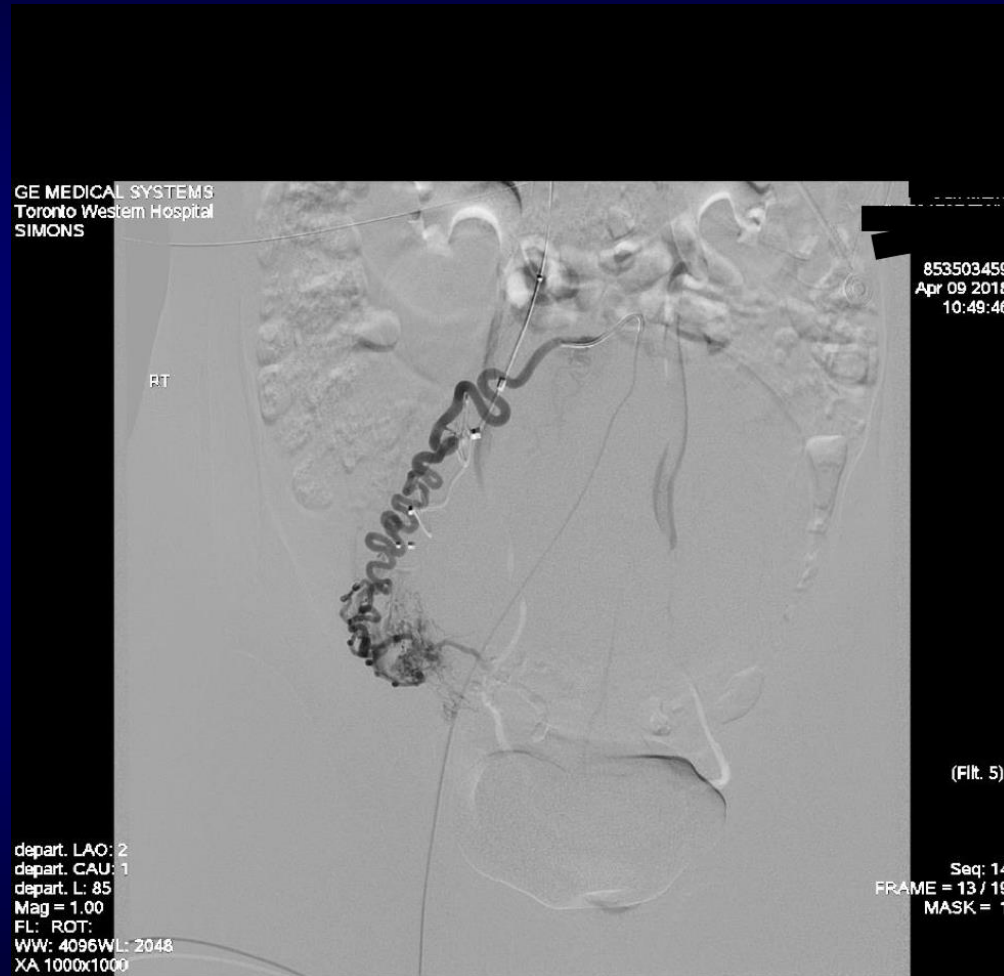Seq: 13
FRAME = 7 / 17
MASK = 1



Right uterine artery

- Repeat angiography through the Roberts catheter within the right uterine artery was performed demonstrating no filling of the gonadal vein
- The right uterine artery was embolized to near stasis using 3.75 vials of 355-500 micron PVA particles
- 10 ml of 1% lidocaine was instilled after embolization

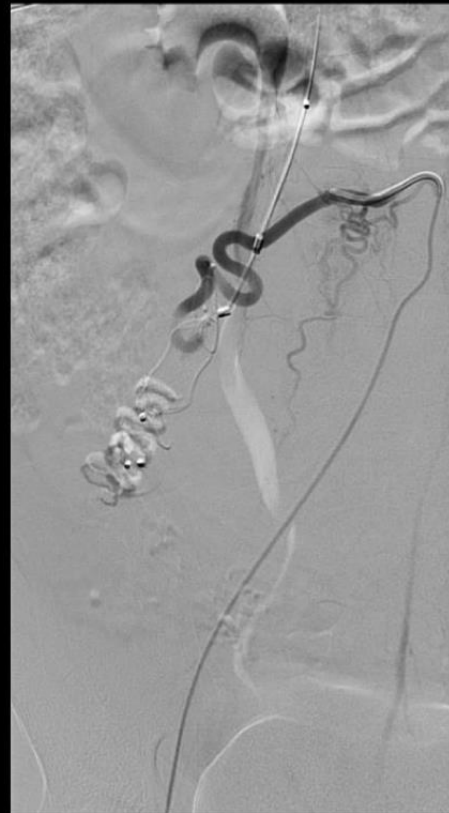Right ovarian artery



Right ovarian artery

GE MEDICAL SYSTEMS
Toronto Western Hospital
SIMONS

RT



11:00:21.1500

Apr 09 2018
11:04:14

(Flt. 5)
(Shut.)

depart. LAO: 4
depart. CAU: 2
depart. L: 85
Mag = 1.00
FL: ROT;
WW: 4096WL: 2048
XA 800x800

Seq: 16
FRAME = 12 / 12
MASK = 1

Right ovarian artery

- The right ovarian artery was selected using a 5 Fr Mikaelson catheter
- Angiography demonstrated opacification of the distal branches with no evidence of shunt to the right gonadal (ovarian) vein
- A micro catheter was then advanced distally and embolization was performed with a small amount of 1:2 dilution glue (cyanoacrylate:lipiodol)
- Final angiography with the balloon deflated within the right gonadal vein demonstrated stasis of the proximal right ovarian artery

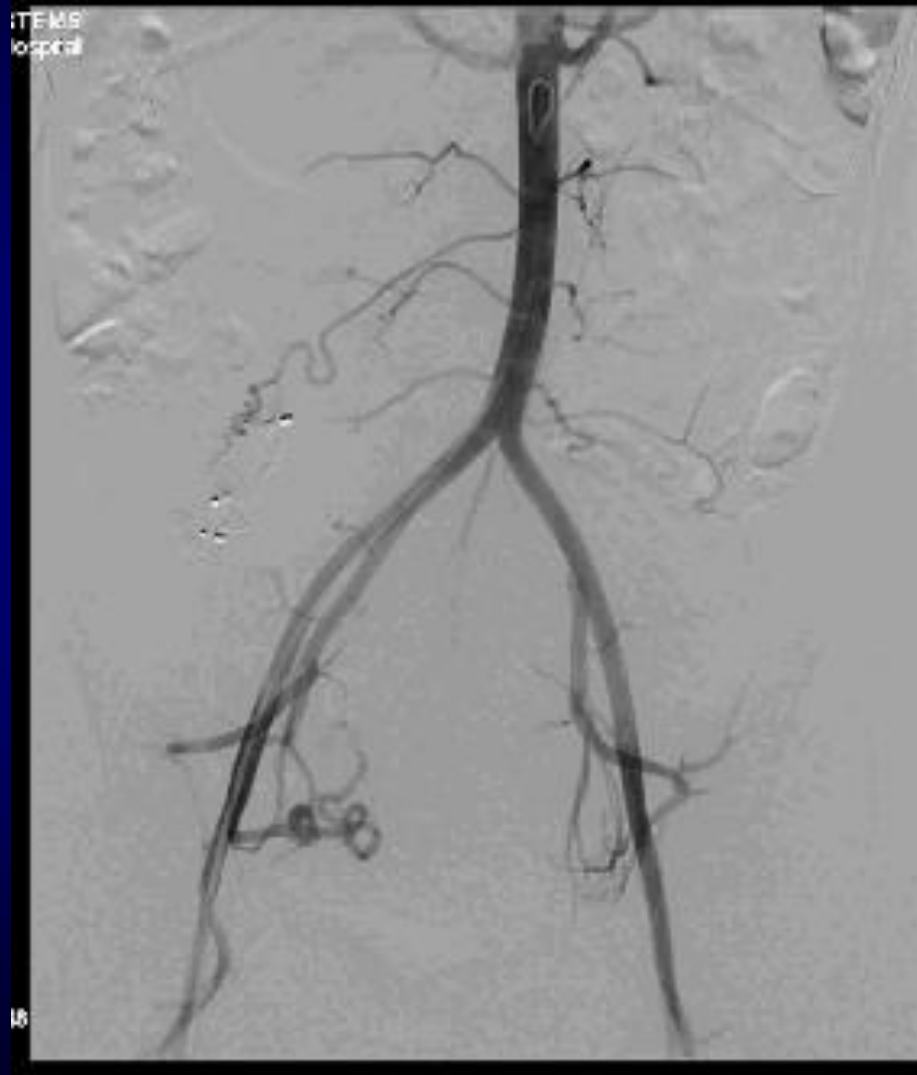6 Months Later...

- Follow up MRA
 - Persistent arterial filling of the known right pelvic AVM with multifactorial supply involving mainly the right uterine, but also likely contribution from the right gonadal
 - No new enlarged draining vein
 - Significant reduction in size of fibroid
 - No residual fibroid enhancement

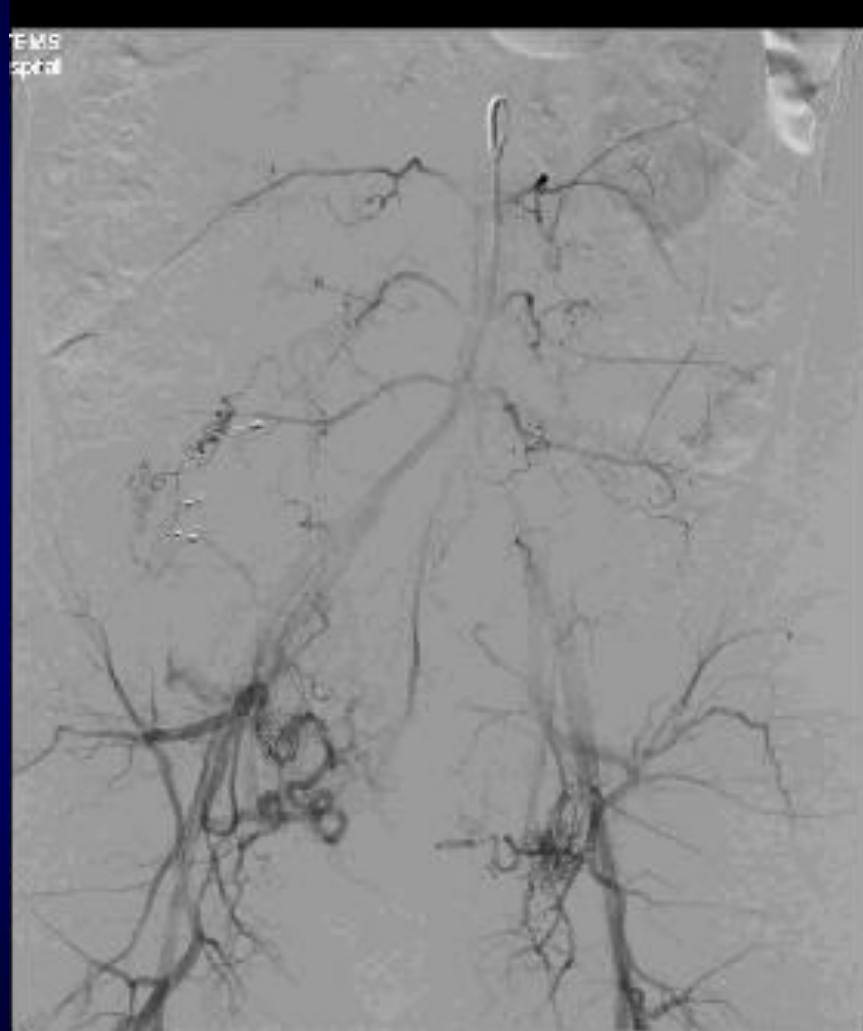
6 Month Follow-up

- Menorrhagia and dysmenorrhea improved
- Persistent right upper quadrant abdominal pain
- Scheduled for elective repeat embolization

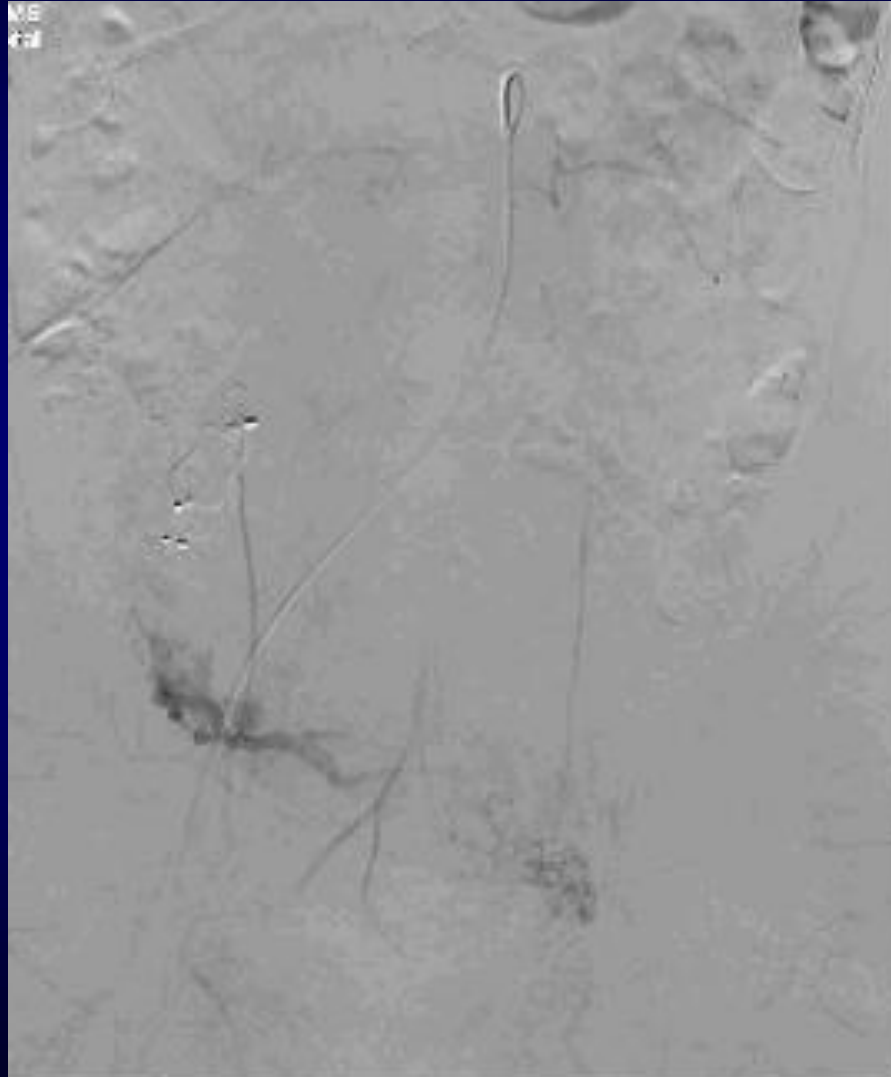
Follow-up aortogram



Follow-up aortogram



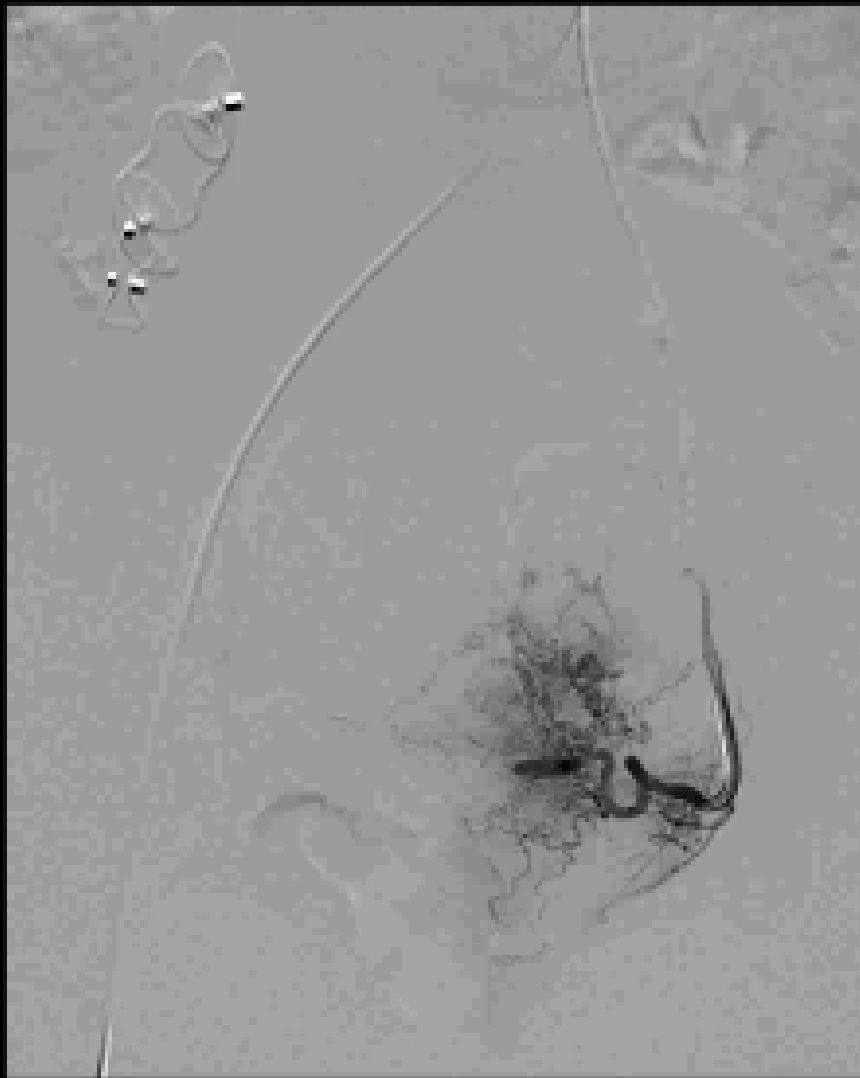
Follow-up aortogram



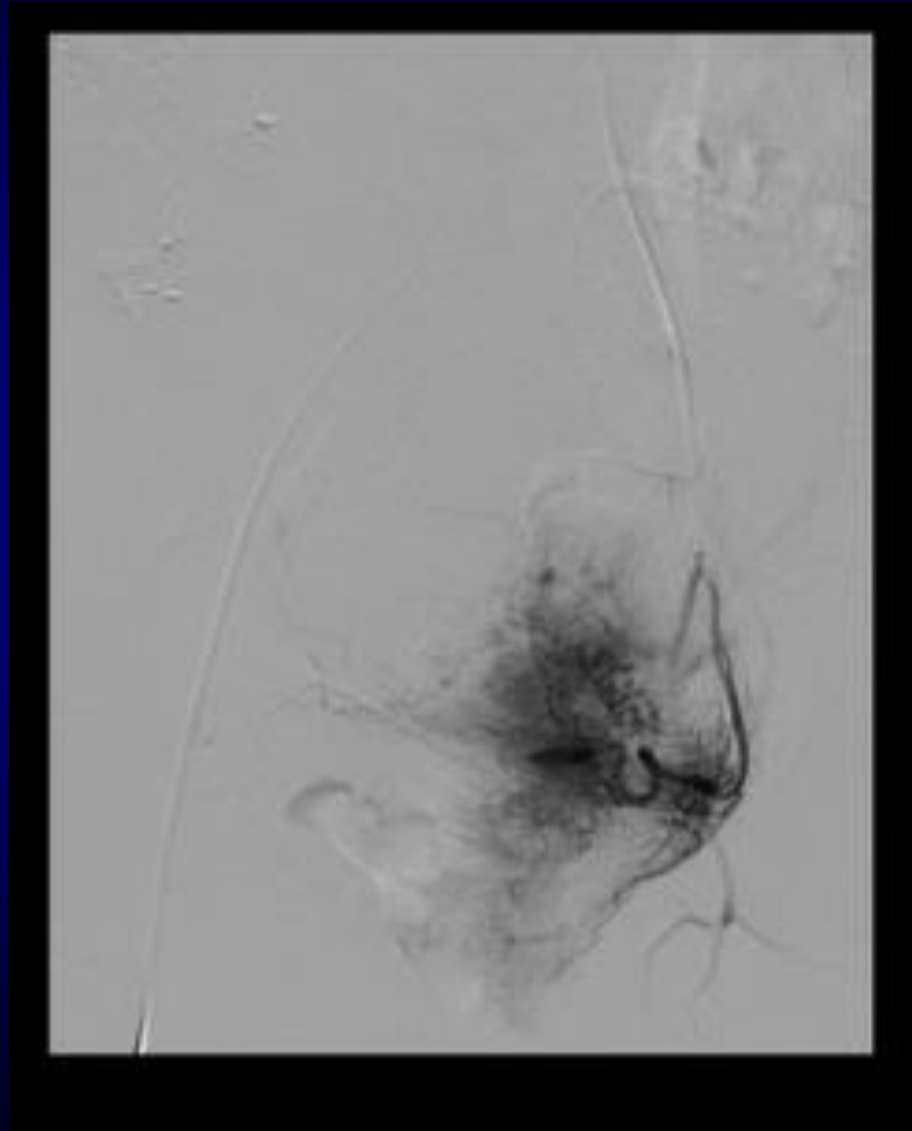
Follow-up aortogram

- Infrarenal aortogram was performed demonstrating recanalization of the bilateral uterine arteries
- Perfusion of a fibroid on the left side and likely on the right as well
- Persistent right abdominal/pelvic high flow vascular malformation with arterial supply via the right uterine and ovarian arteries
- Persistent flow to the previously embolized fibroid

Left uterine artery

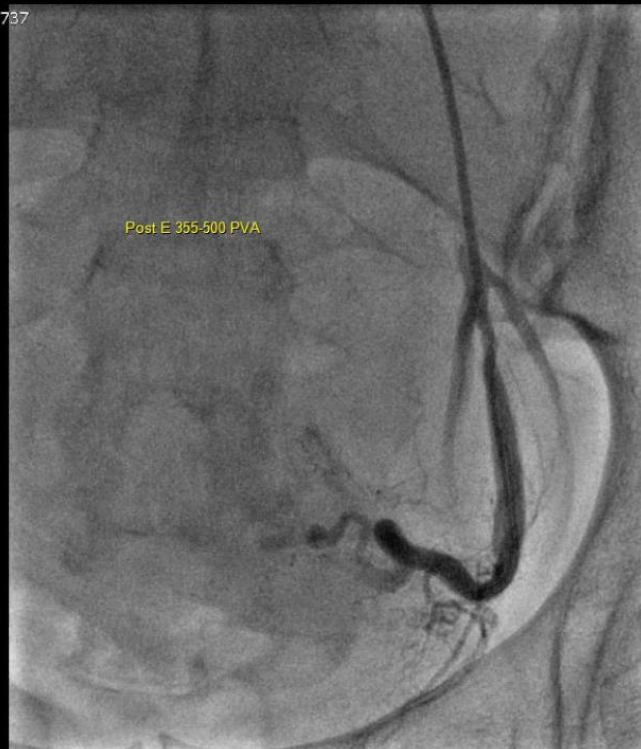

Left uterine artery



Left uterine artery

GE MEDICAL SYSTEMS TERRA
DL
Ex: 854017737/854017737
Se: 1
Im: 2



4021707 1771
Oct 09 2018
09:43:46 AM
Mag = 1.00
FL:
ROT:

LT

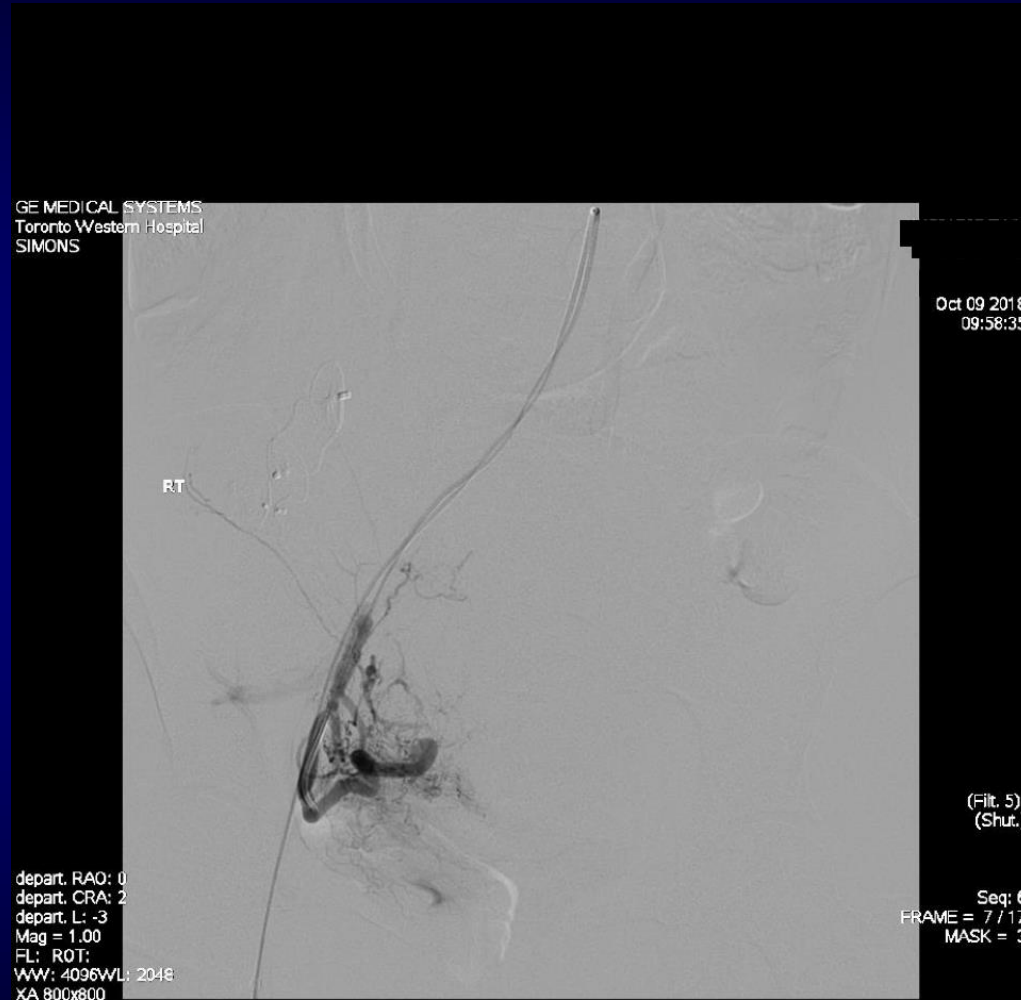
(Shut.)

WW: 256WL: 128

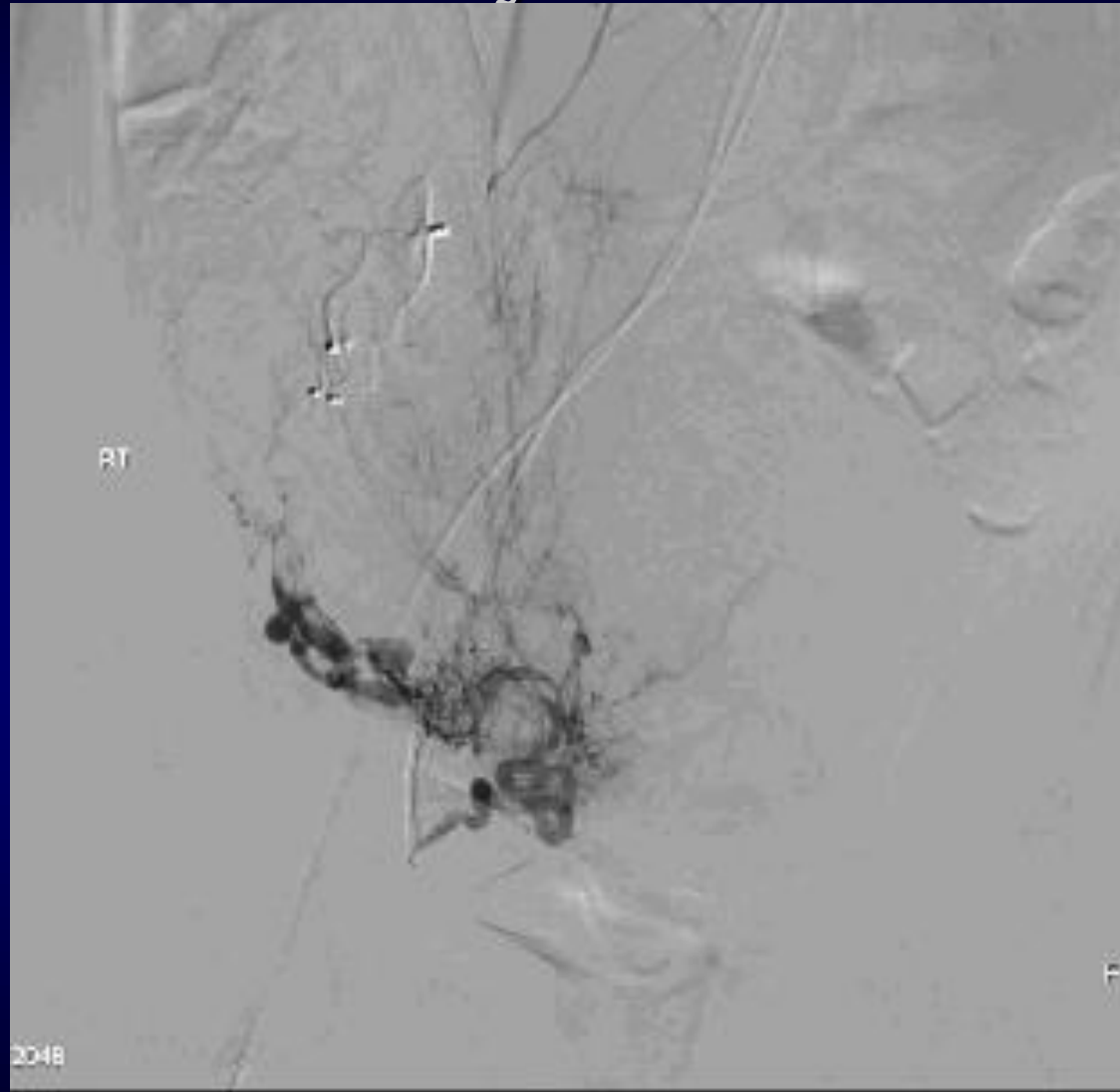
Left uterine artery

- The left internal iliac artery was selected and the catheter advanced to the left uterine artery transverse segment
- This vessel was embolized to near-complete stasis using 1 vial of polyvinyl alcohol (355-500 micron)
- Post-embolization angiogram showed no opacification of the fibroid with almost complete occlusion of the left uterine artery
- 10 mL of 1% intra-arterial lidocaine was slowly given

Right uterine artery



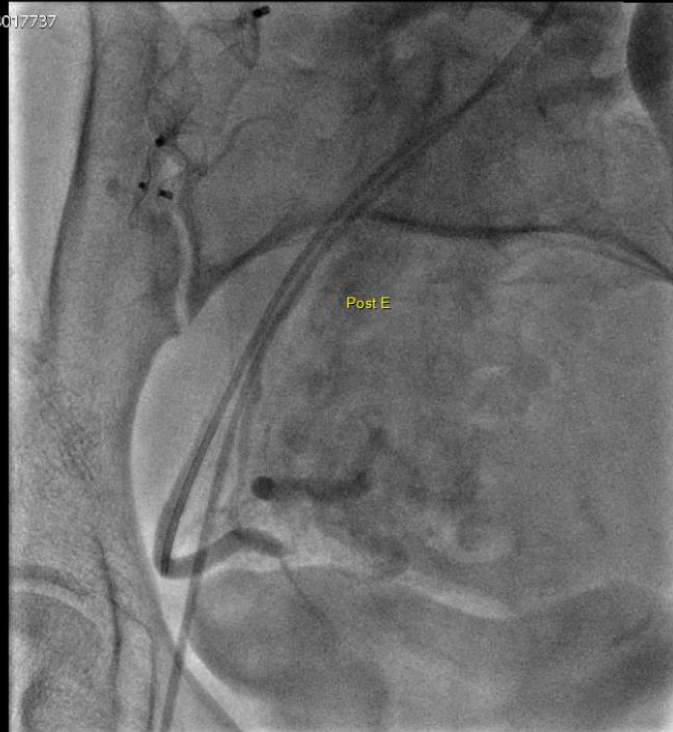Right uterine artery



Right uterine artery

GE MEDICAL SYSTEMS TERRA
DL
Ex: 854017737/854017737
Se: 1
Im: 6

RT



TOE1707 1771
Oct 09 2018
09:56:26 AM
Mag = 1.00
FL:
ROT:


(Shut.)

WW: 256WL: 128

Right uterine artery

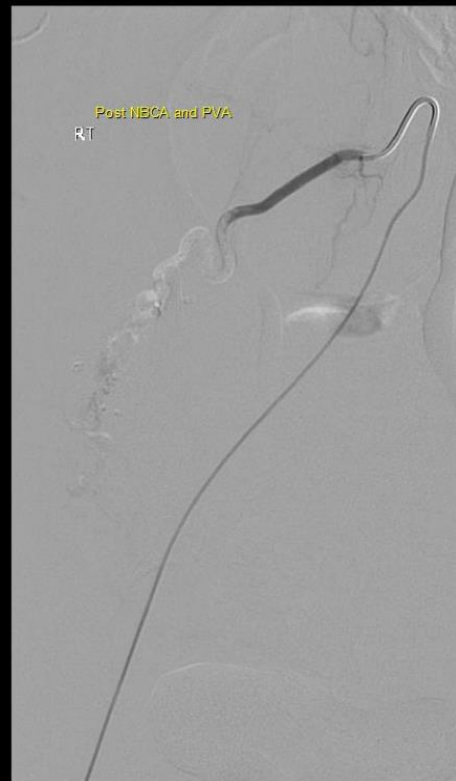
- The Roberts catheter was used to access the right internal iliac artery, navigated to the right uterine artery and advanced to its transverse segment
- Persistent arterial supply from the right uterine artery to the AVM was noted
- This artery was embolized to near-complete stasis using half of a vial of polyvinyl alcohol particles (355-500 micron)

Right ovarian artery



Right ovarian artery

GE MEDICAL SYSTEMS
Toronto Western Hospital
SIMONS



Oct 09 2018
10:20:26

(Filt. 5)
(Shut.)

depart. LAO: 7
depart. CRA: 5
depart. L: -3
Mag = 1.00
FL: ROT;
WWW: 4096VWL: 2048
XA 800x800

Seq: 10
FRAME = 7 / 11
MASK = 3

Right ovarian artery

- Contrast injection demonstrated this vessel was patent although smaller in caliber compared to 6 months prior
- Tortuous collaterals in communication with the parametrial veins were identified but no dilated draining ovarian vein could be identified
- A 2.8 Fr microcatheter was used to navigate into the mid portion of the right ovarian artery
- Half of a vial of polyvinyl alcohol particles (355-500 micron) followed by 5 mL glue/lipiodol (1:4 ratio) was used to embolize this vessel
- Post-embolization angiogram showed almost complete occlusion of the mid to distal right ovarian artery and no opacification of the fibroid

Follow-up 3 months later...

- Further reduction in fibroid size
 - Currently 8.0 x 8.0 x 7.2 cm
 - After first treatment 11.8 x 11.0 x 8.4 cm
 - Initially 15.0 x 12.0 x 6.0 cm
- No residual fibroid enhancement
- Patient is pain free, has regular periods
- However, large right adnexal mass with cystic areas persists
 - AVM
 - Right ovary – possibly increased in size
 - Surgical referral for consideration of oophorectomy

Vascular Malformations

Classification

- Mulliken and Glowacki 1982
 - Flow characteristics (rapid flow or slow flow)
 - Vascular channel components
 - capillary, venous, lymphatic, arterial, and combined

Venous Malformations

- Most common symptomatic VM
- Gene mutation (TIE2) disrupts cell signaling during angiogenesis
- Endothelial abnormalities
- Severe deficiencies of smooth muscle layer
- Gradual stretching/expansion of lumen
- Distended with dependency or increased venous pressure

Venous Malformations

Clinical presentation

- Pain and swelling
 - Worse with prolonged standing, exercise, pregnancy
- Pelvic (female) – associated with ovarian vein insufficiency
 - Questionable subtype of pelvic congestion syndrome

Venous Malformations

Imaging

- T2 hyperintense, phleboliths, heterogenous enhancement

Treatment

- Sclerosant injection - primary endovascular approach

Lymphatic Malformations (Lymphangiomas)

- May be focal or diffuse lesions
- Typically multicystic lesions with septations
- Subdivided into macrocystic (>2cm), microcystic, or mixed
- Some thought to represent incompetent lymphatic channels
- Often have associated venous component dilated veins (questionable persistent embryonic veins)
 - ie. lymphaticovenous malformation

Lymphatic Malformations

Clinical presentation

- Pain, swelling, complicated/worsening acutely due to intra-lesional hemorrhage
 - Can have cutaneous component as well
- Large majority occur in head/neck or axilla but can occur anywhere

Lymphatic Malformations

Imaging

- Multilocular cystic masses
 - Range from simple fluid to complex if containing debris, hemorrhage, infected etc.
- Internal septa of varying thickness (not well seen on CT)
 - Septa can be vascular
- T2 hyperintense
- Unlike VM there is no enhancement of the fluid collection

Lymphatic Malformations

Treatment

- Aspiration +/- sclerosant injection
 - Outcome varies depending on lesion characteristics
 - Best outcome with simple macrocystic
- Surgical excision

Rapid-Flow Arteriovenous Malformations (AVMs)

- Direct artery to vein communication without intervening capillary bed
- More common in head/neck but can occur anywhere
- Congenital or acquired
 - Can evolve over time
 - Hormonal influences, trauma
- Most are spontaneous
 - Hypothesis: abnormal endothelial cell proliferation & delayed vascular remodeling during fetal angiogenesis
- Predisposing mutations have been identified
 - ie. ALK-1 & endoglin -> HHT

Rapid-Flow Arteriovenous Malformations (AVMs)

- Clinical presentation
 - Largely dependent on flow dynamics of lesion
 - Minimal shunting: asymptomatic
 - Active high-flow shunt: high-output cardiac failure
 - Pain
 - Bleeding – ranges from spotting to catastrophic

Rapid-Flow Arteriovenous Malformations (AVMs)

- Imaging

- U/S often first modality
 - may be non-specific myometrial thickening/inhomogeneity
 - High velocity, low resistive indices (RI 0.25-0.55)
- CTA/MRA to delineate extent of lesion
 - Network of serpiginous arteries
 - Nidus
 - Dilated draining veins with early filling
 - Flow voids on conventional MR
- DSA remains 'gold standard'

Pelvic & Uterine AVMs

- Distinct entities with different etiologies, presentation, and management
- Pelvic AVMs
 - May have components involving uterus
 - Usually sporadic congenital lesions
- Uterine AVMs
 - Arteriovenous communications entirely within uterus
 - Majority acquired
 - May be more accurately termed AV fistulas
 - Semantics.. abundant uterine vasculature causes these to behave like a true AVM

Pelvic & Uterine AVM Treatment

- Asymptomatic women diagnosed by U/S
 - PSV < 40 cm/s
 - spontaneous resolution often occurs
 - conservative management
 - PSV >60 cm/s
 - higher risk for spontaneous bleed
- Presenting with hemorrhage
 - Embolization
 - Uterine AVMs respond well
 - Pelvic AVMs are trickier

Pelvic AVMs

- Poorer response to traditional transarterial embolization
 - Can attain massive size and high flow
 - Extensive arterial supply, often from multiple pelvic arteries
 - Anterior branches of internal iliac artery
 - Median sacral artery
 - IMA
 - Angiogenesis
- Often a single draining vein
 - Important target for treatment

Pelvic AVM Treatment Techniques

- **Interventional**
- Transarterial approach
- Transvenous approach
 - Femoral or jugular access
 - Risks
 - Non-target embolization
 - Embedding catheter
- Direct percutaneous puncture
 - Embolization, sclerosant injection

Pelvic AVM Treatment Techniques

- Surgical

- Uterine AVM

- Hysterectomy is the definitive treatment
 - Loss of fertility
 - Higher morbidity
 - Longer recovery

- Congenital pelvic AVMs

- more complicated due to typically complex network of AV communications and intimate association of the abnormal vessels to critical structures within the pelvis
 - Performed less frequently

Pelvic AVM Treatment Techniques

- Conservative

- Possibility of spontaneous resolution
 - Select lesions in appropriate patients
- Limited evidence/case reports (uterine AVMs)
 - GnRH agonists +/- subsequent embolization
 - Ultrasound-guided high-intensity focused ultrasound

Case Learning Points

- Treat the patient not the pictures
 - Be aware of high risk features
- Various forms/spectrum of vascular/lymphatic malformations
- True pelvic AVMs differ from uterine AVMS regarding etiology and response to treatment