



Case of the Week

August 2015

Drs. Sultan Alharbi & David Peck

London Health Science Center - University Hospital

Western University

Case Report

- 68-year-old gentleman underwent an uneventful robotic assisted prostatectomy.
- 10 days later his Foley catheter had fallen out.
- A few hours later he presented to ED with severe suprapubic pain and urinary retention.
- He denied any fevers or chills.
- On exam: diffuse peritonitis.

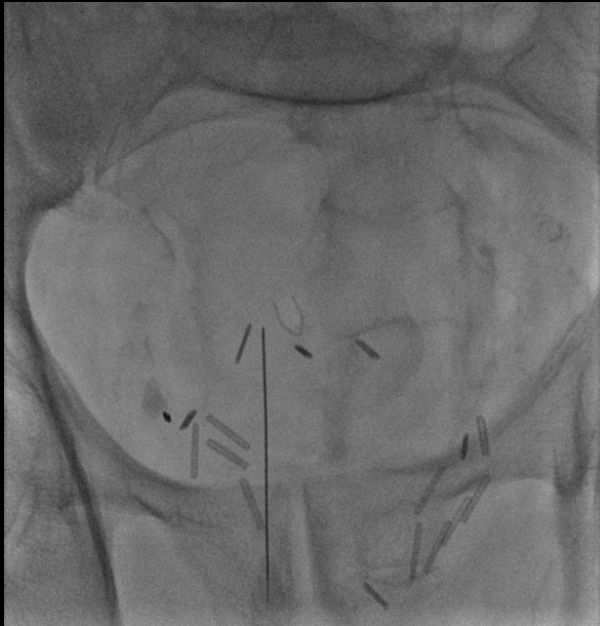Case Report

- Flexible cystoscopy per urethra was done.
- Multiple unsuccessful attempts in reinserting a Foley catheter during the procedure by urologist.
- Complete disruption of the urethral anastomosis with the bladder neck is suspected.
- An urgent percutaneous cystostomy was requested due to urinary retention prior to planned operative repair of the disrupted urethra.

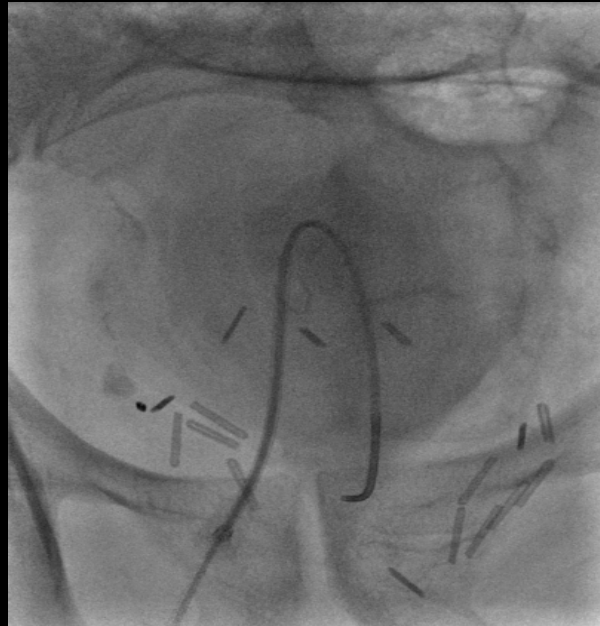
Procedure

- After discussion with urologist, percutaneous transvesical antegrade urethral catheterization was planned.

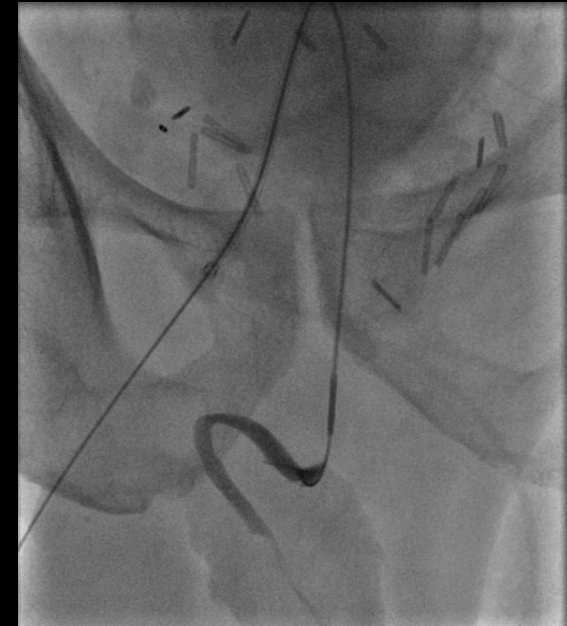Percutaneous transvesical antegrade urethral catheterization



- Suprapubic access

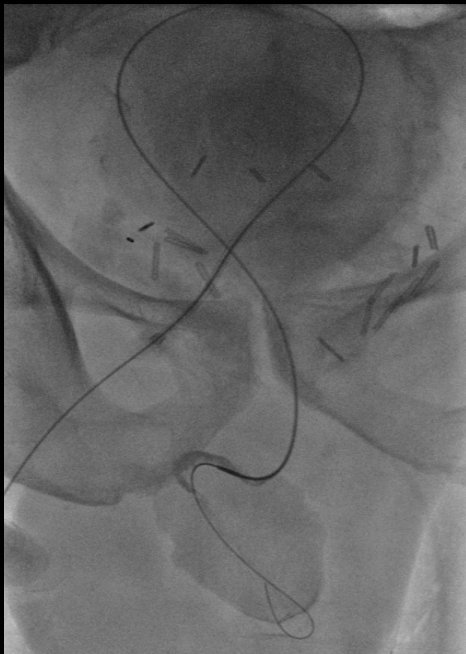


- Sheath and angled catheter used

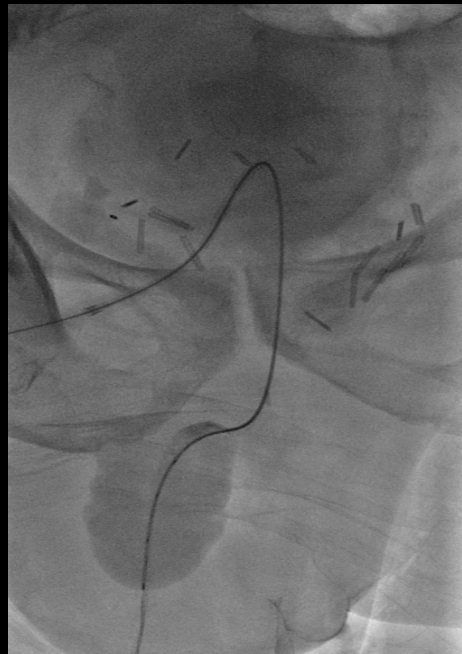


- Angled catheter used to cannulate the posterior urethra

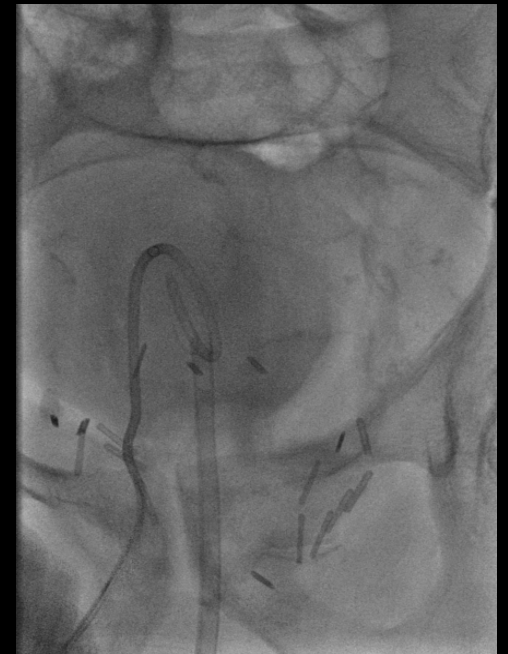
Percutaneous transvesical antegrade urethral catheterization



- Hydrophilic wire passed through the urethra



- Catheter advanced and wire exchanged to stiffer wire



- Foley catheter was inserted over wire
- Sheath was exchanged for suprapubic catheter

Post procedure

- Patient was doing well.
- No complication occurred.
- Discharged home.
- And more important no surgery was required.

Discussion

- Inadvertently removed Foley catheter after open prostatectomy is a nightmare for urologist.
- Urethroplasty for postoperative disrupted urethra is a major surgery.
- Suprapubic catheter is usually inserted due to urinary retention prior to operation.
- Percutaneous transvesical antegrade urethral catheterization is an alternative minimally invasive procedure whenever retrograde urethral catheterization is impossible.