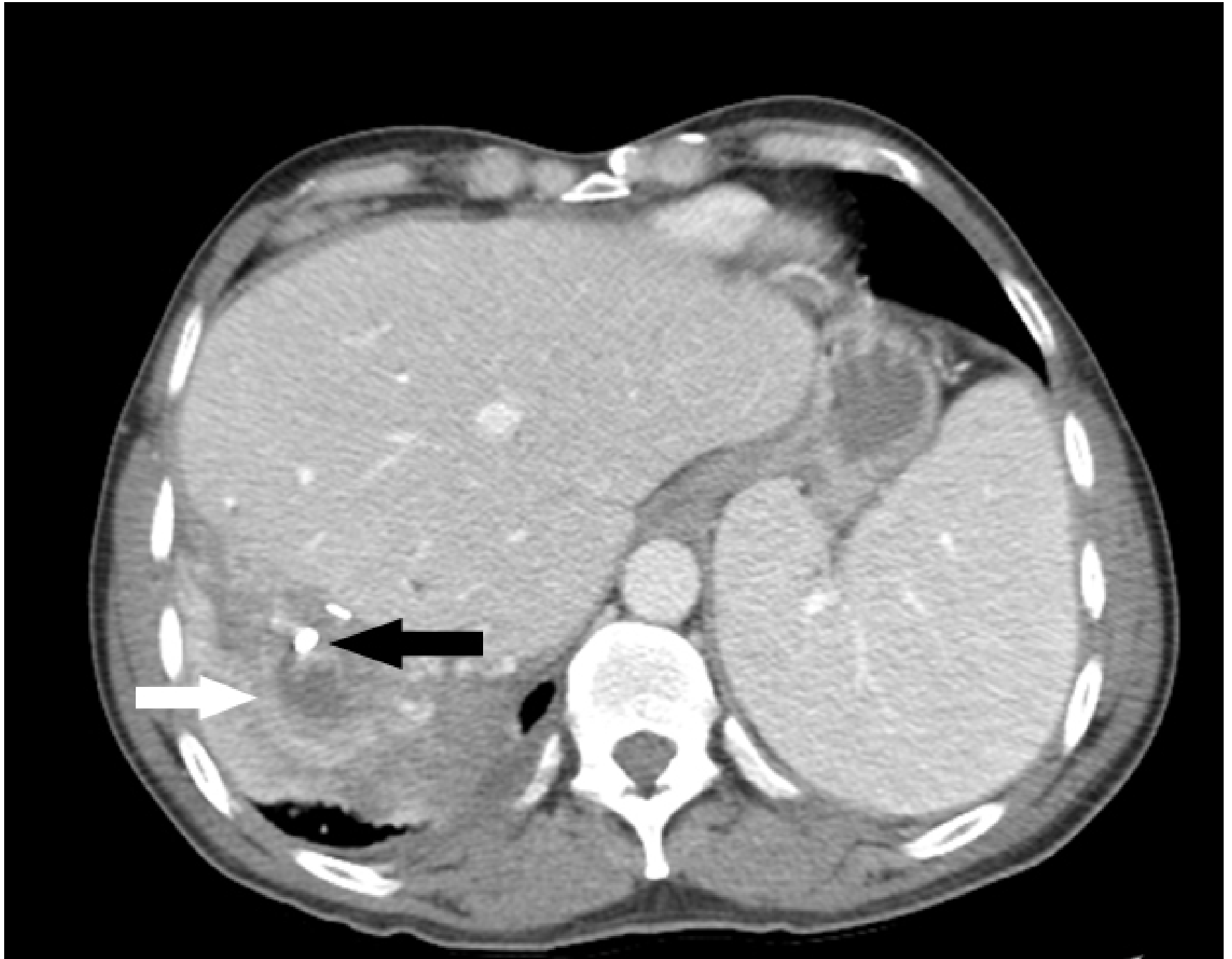


CIRA Case of the Day

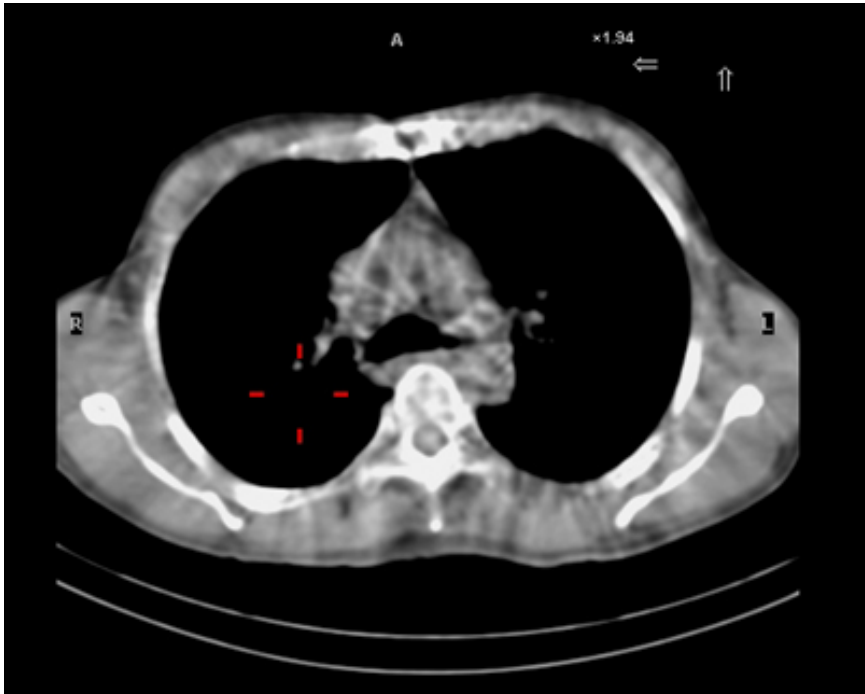
May 2015

Case Courtesy of Dr. Jonathan Chung
Western University

A 50-year-old male patient of Filipino descent presented to the emergency room with fever and a productive cough. His past medical history was significant for recurrent pyogenic cholangitis and recurrent pneumonia. He underwent a right hepatectomy approximately 15 years prior and was well known to both interventional radiology and gastroenterology for management of multiple percutaneous drains and endoscopic stents. Findings on his chest radiograph were consistent with right lower lobe pneumonia. The patient was also investigated with computed tomography of the abdomen (Image 1).

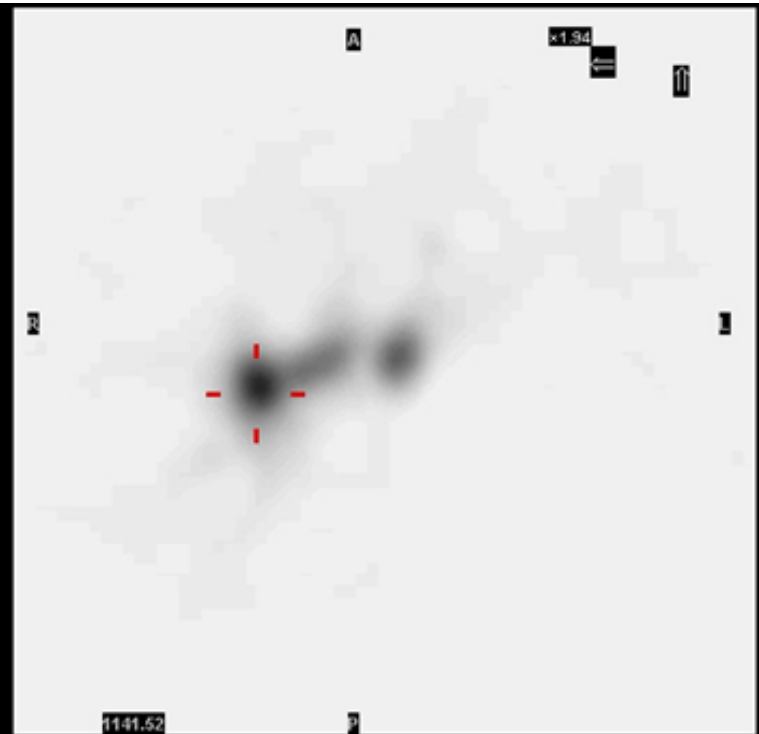


CT of the abdomen showed the tip of the endoscopic biliary stent protruding outside the liver with the tip (black arrow) terminating within a perihepatic inflammatory collection (white arrow). Upon further questioning, the patient revealed that he had been producing brown sputum for several weeks. A HIDA scan was performed (Image 2).



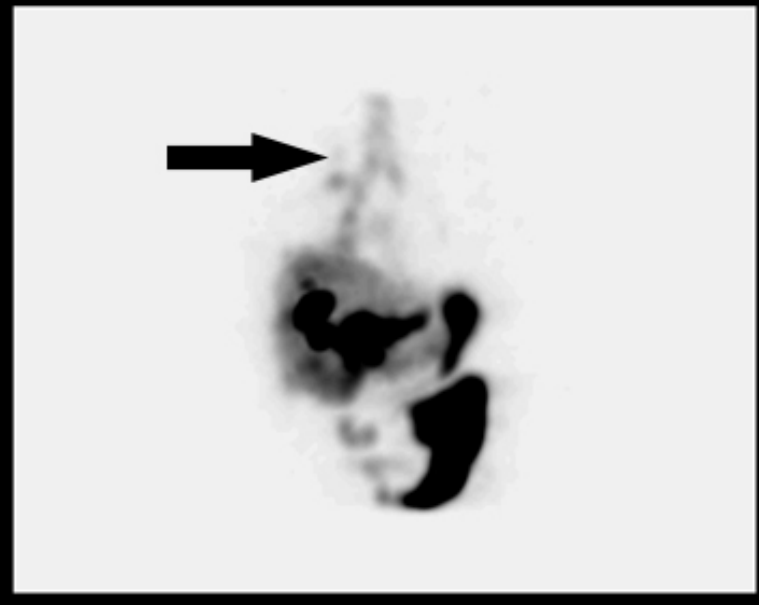
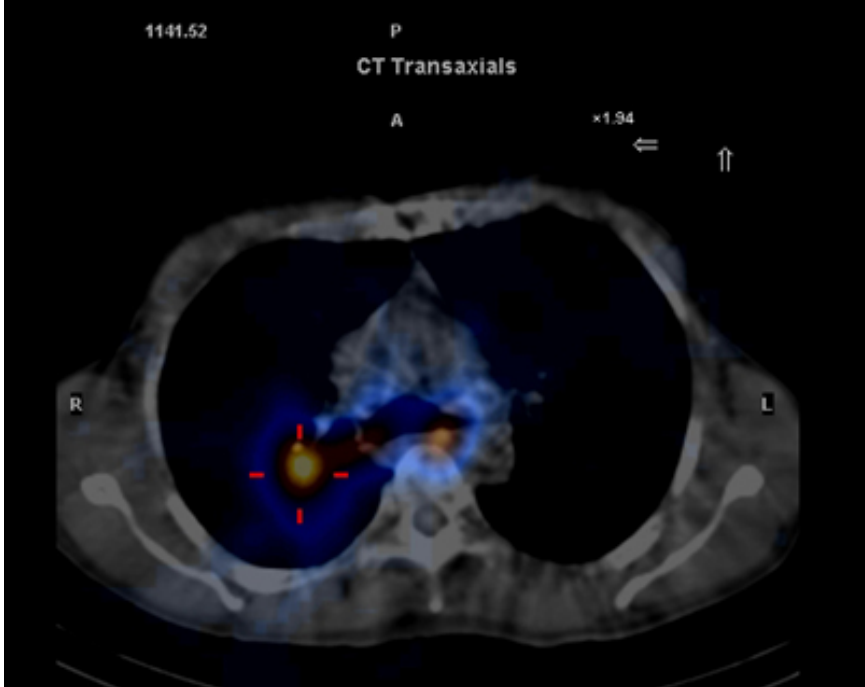
1141.52

P
CT Transaxials

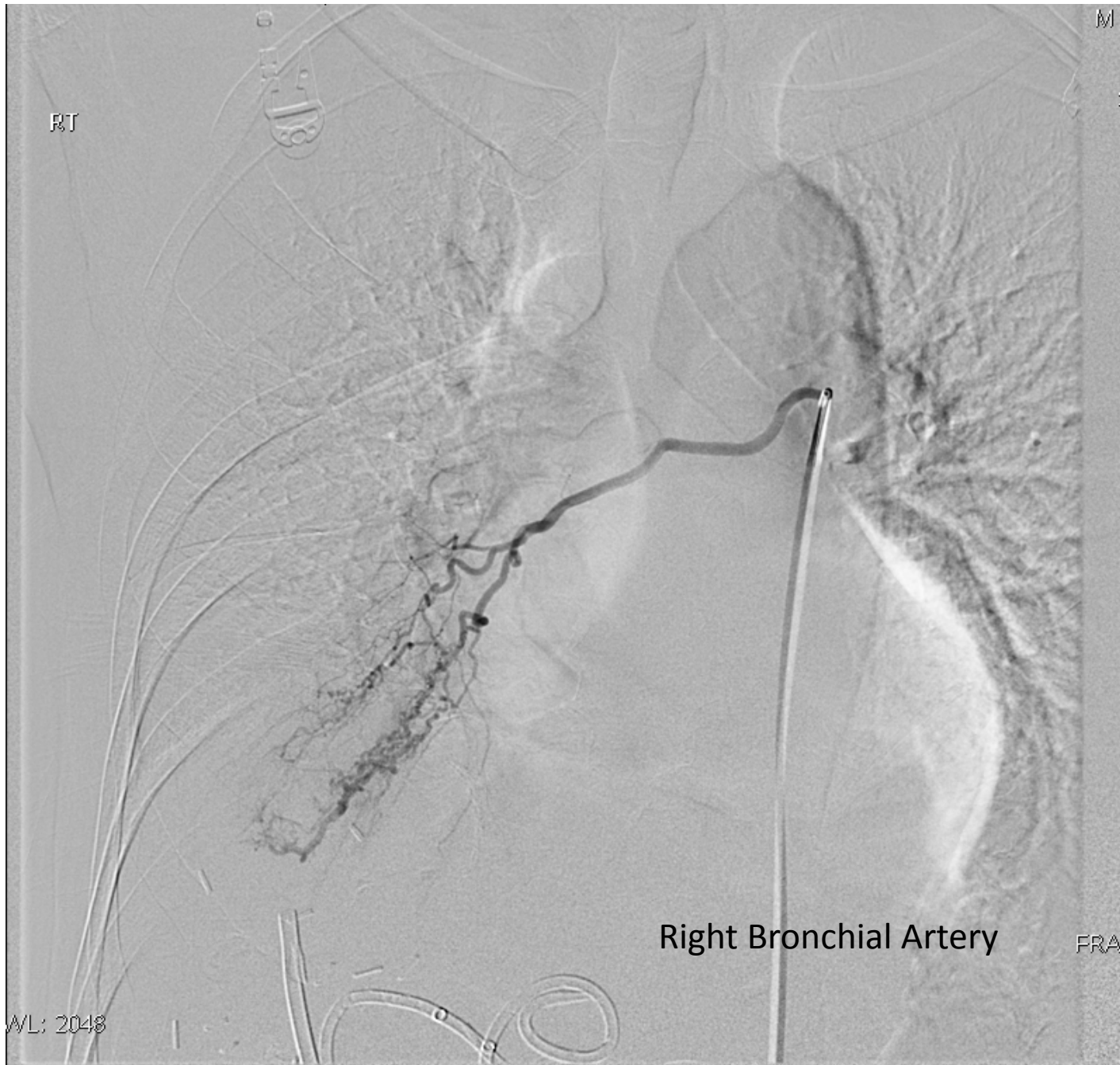

1141.52

NM Transaxials



The HIDA scan images show radiotracer uptake in the right lower lobe. Tomographic image on the right shows the ascending course of radiotracer through the right lung and towards the trachea, confirming the presence of a bronchobiliary fistula. The patient was discharged with an appointment for surgical consultation however returned to the emergency department shortly thereafter with life-threatening hemoptysis. Interventional radiology was consulted.



RT

18

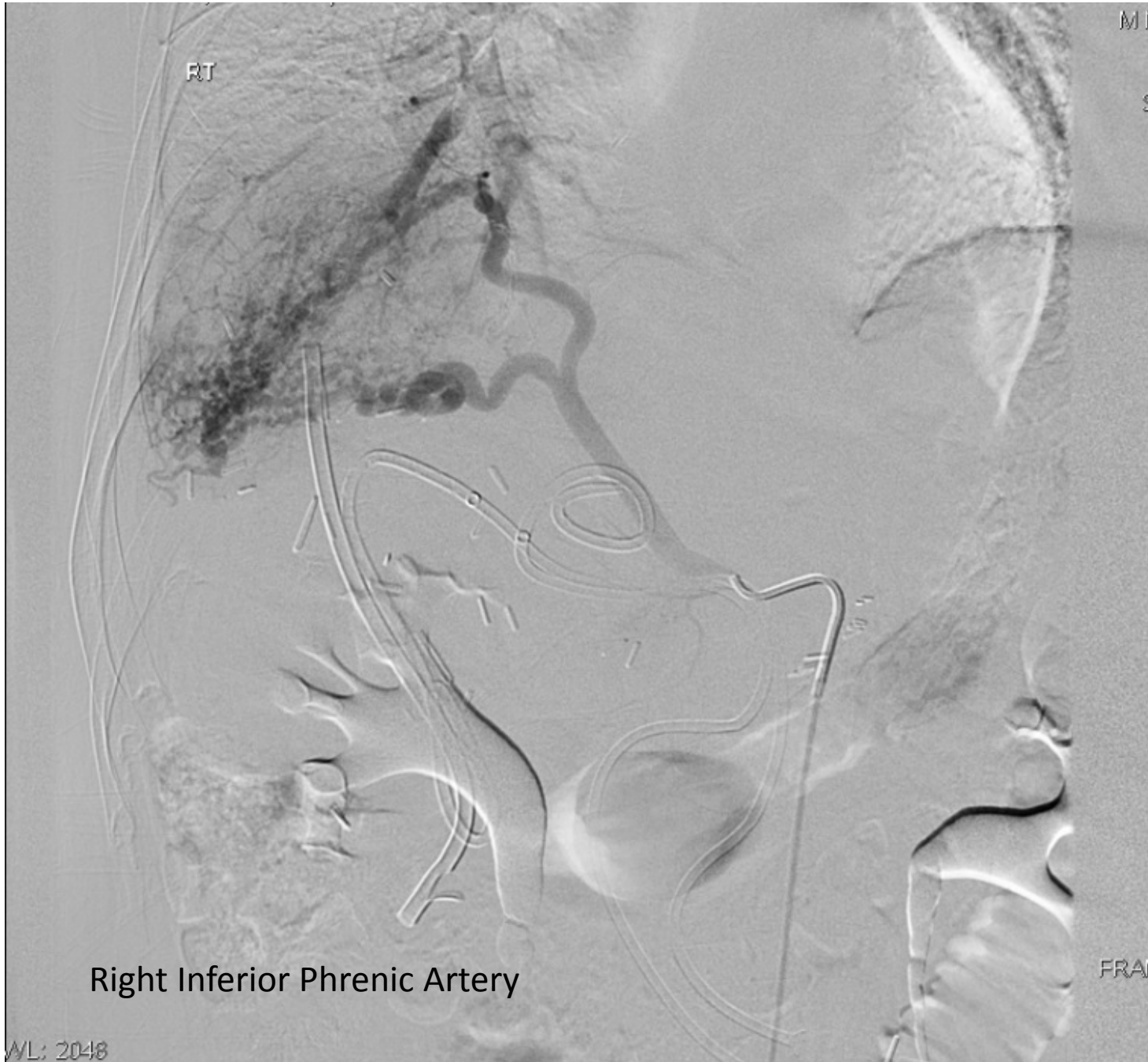MI

FRAN

Right Bronchial Artery

FRAN

WL: 2048

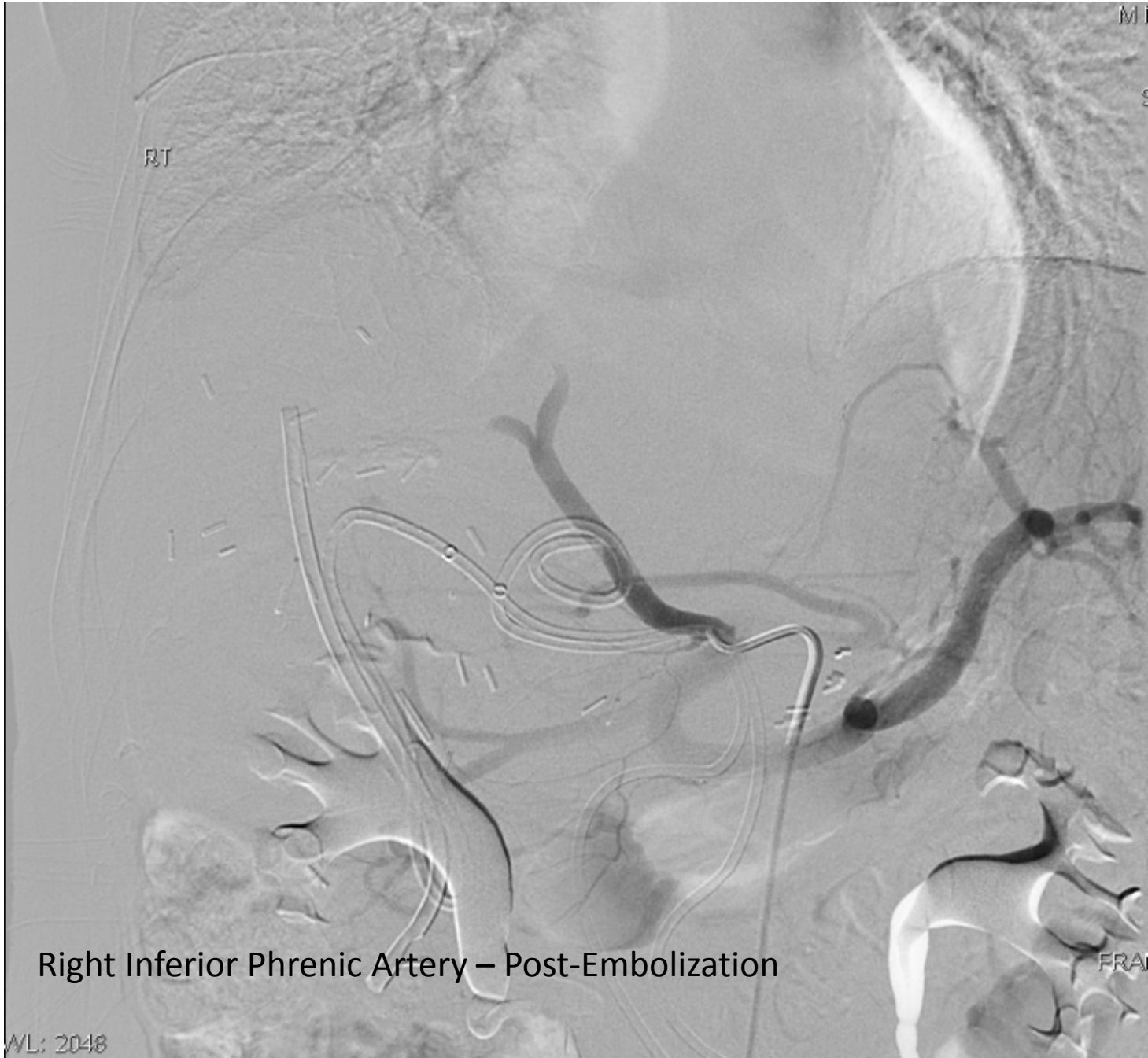

Right Inferior Phrenic Artery

WL: 2048

An angiogram was performed and this showed abnormal hypertrophy of both the right bronchial and right inferior phrenic arteries. Both arteries demonstrated neovascularity in the right lower lobe and the right inferior phrenic artery actually showed shunting to the pulmonary arterial system. It is postulated that the chronic inflammation from recurrent pneumonias, secondary to a bronchobiliary fistula induced neovascularity and eventual hypertrophy of these two arteries.

Embolization of the right bronchial artery with 355-500 micron PVA particles occluded the distal branches of this artery. Both 700-1000 micron particles and Gelfoam were used to occlude two branches of the right inferior phrenic artery. The patient was stabilized and eventually went on to have a right lower lobectomy, diaphragm repair, and Roux-en-Y.



Right Inferior Phrenic Artery – Post-Embolization

WL: 2048